

Results in Surgical Correction of Pectus Excavatum

Masatoshi MORI, M. D., Katsunobu KAWAHARA, M. D.
Hiroyoshi AYABE, M. D. and Masao TOMITA, M. D.

*The First Department of Surgery, Nagasaki University Hospital,
Nagasaki, JAPAN*

Received for publication, June 25, 1990

SUMMARY : The results in 37 patients who underwent surgical correction of pectus excavatum at the First Department of Surgery, Nagasaki University Hospital during a period from 1973 to 1984 were reported. A variety of surgical techniques were used, and satisfactory results were obtained in 29 patients (78%), including 24 excellent and 5 good appreciation. Topical postoperative complications occurred in 14 of the 37 patients (38%). Five patients had recurrence of the excavated deformity. Repair of the deformity using sternal turnover technique yielded satisfactory results in 24 of the 27 patients (88%). However, partial bone necrosis occurred in 2 patients, and recurrence of the deformity occurred in 2 patients, who underwent the classical type of turnover operation at their ages over 9 years old. Since 1982 subperichondrial dissection technique has been employed for free grafted sternal turnover operation, the results have been satisfactory without any major topical complication. The efficacy of total preservation of the perichondrium was emphasized.

INTRODUCTION

Pectus excavatum (funnel chest, Trichterbrust or thorax en entonnoir) is the most common deformity of the anterior chest wall¹²⁾. Wada¹⁸⁾ reported an incidence of 0.26% of the population in Japan, with a higher incidence (4.9%) in the poor rural area. The cause of the deformity has not yet been elucidated. The explanation which blames the pectus deformity on the overgrowth of the lower costal cartilages is more convincing^{11, 12, 13, 15)}. Several procedures have been devised for the surgical correction of pectus excavatum, however, controversy still remains between various surgical procedures, and it is not easy to appreciate the results of operation exactly¹⁰⁾.

This article reports our experience using various surgical procedures in our department.

PATIENTS AND METHODS

During a 12-year period from 1973 to 1984, 37 patients underwent surgical correction of pectus excavatum at the First Department of Surgery, Nagasaki University Hospital. There were 31 male and 6 female patients, and the age at operation ranged from 2 to 26 years old, with an average of 11 years (**Table 1**).

Table 1. Age at Operation and Sex of 37 Patients with Pectus Excavatum.

Age	No. of Patients	
	Male	Female
2	1	
4-5	7	1
6-12	11	3
13-15	5	2
16-18	6	
26	1	

Table 2. Funnel Chest Indices and Symmetry of 37 Patients with Pectus Excavatum.

Funnel Chest Index	No. of Patients	
	Symmetrical	Asymmetrical
Group 1	5	2
Group 2		1
Group 3	2	3
Group 4	4	
Group 5	8	11
Unknown	1	

Table 3. Symptoms in 37 Patients with Pectus Excavatum.

Symptom	No. of Patients
Common cold	20
Exertional dyspnea	3
Oppressed feeling	3
Easy fatiguability	3
None	10

Table 4. Respiratory Function (%VC) in 37 patients with Pectus Excavatum.

%VC	No. of Patients				
	Age (years old)	2-5	6-12	13-15	16-26
81-114%		3	5	6	
52-80%		1	6	1	7
N. E.*		5	3		

*Not examined

Table 5. Abnormalities in ECG and Heart Murmur in 37 Patients with Pectus Excavatum.

Abnormality	No. of Patients
IRBBB*	23
Others	10
Normal ECG	4
Heart murmur	13

*Incomplete right bundle branch block

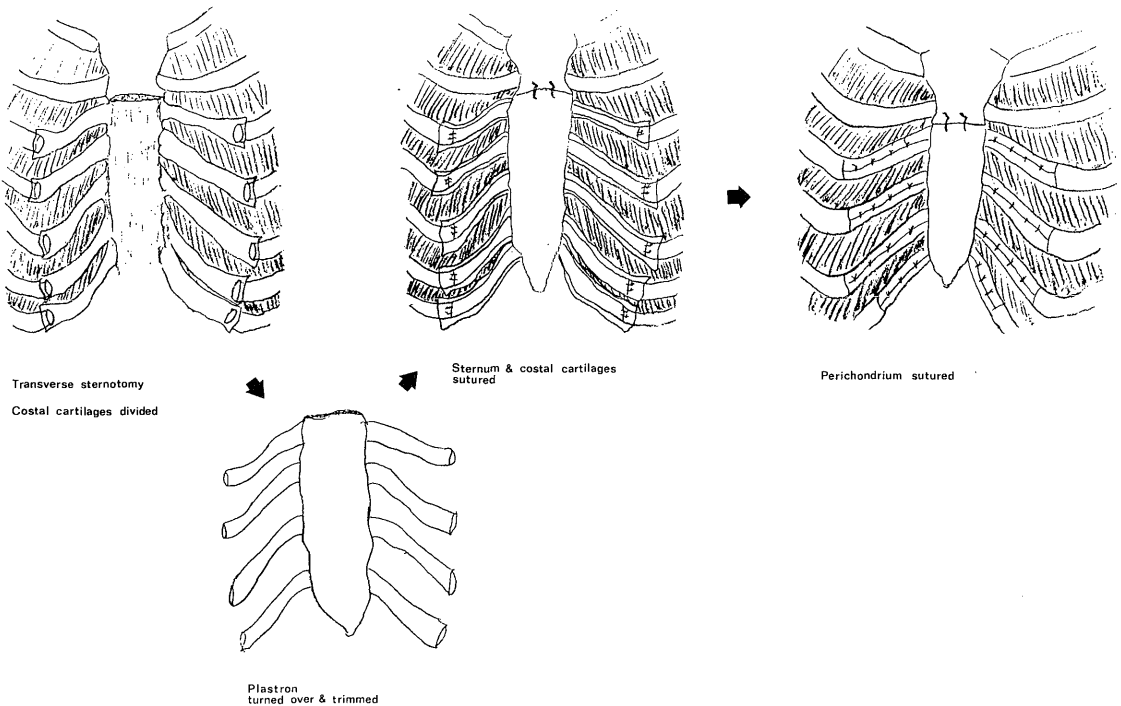


Fig. 1. Sternal turnover operation for correction of pectus excavatum using subperichondrial dissection technique. The perichondrium, intercostal muscle, intercostal vessels and internal mammary vessels are left behind after the resection of the plastron.

The funnel chest indices were measured and assigned to five groups according to the description by Wada and colleagues¹⁹. There were 19 patients (51%) in group 5. Twenty patients had symmetrical deformity, while 17 patients (46%) had asymmetrical deformity (Table 2). Only 6 patients were treated as absolute indication for the operation¹⁹. The indication for surgical correction of pectus excavatum was decided after considering the desire of the patients and the family for cosmetic improvement or avoiding psychological depression as well as the absolute and relative indication on the basis of the funnel chest index.

Twenty-two patients had respiratory symptoms such as exertional dyspnea (3 patients) and frequent suffering from common cold (20 patients). Only 10 patients (27%) were asymptomatic (Table 3). The respiratory function test revealed 15 of the 29 patients (51%) had impairment in respiratory function (%VC: 80% or less) (Table 4). Heart murmur was audible in 13 patients, and ECG abnormalities were observed in 33 patients (89%). Twenty-three patients had incomplete right bundle branch block (Table 5).

The choice of the surgical technique has been altered with the trend in each era. In 27 patients, the sternal turnover technique was employed for surgical correction of pectus excavatum, and the other underwent sternal elevation (8 patients) or costal plasty (2 patients). In 4 of the 27 patients who underwent sternal turnover operation, internal mammary vessels were preserved, and a 13-year-old boy underwent turnover operation with his abdominal rectus muscle preserved.

Since 1982 subperichondrial dissection technique has been employed. The costal cartilages are divided after subperichondrial dissection, and the perichondrium is sutured, after the plastron is turned over, placed and sutured, so that the grafted cartilages are wrapped by the perichondrium (Fig. 1).

Evaluation of the results was by follow-up examination in our clinic and by parent evaluation obtained from the correspondence to our questionnaire. The follow-up results were divided into 4 groups according to the descrip-

tion by Humphreys and Jaretzki¹⁰; excellent, good, fair and poor.

RESULTS

All patients survived the operation. Topical postoperative complications occurred in 14 of the 37 patients (38%) (Fig. 2). Subcutaneous abscess was the most frequent complication (5 patients) and was easily correctable. Partial bone necrosis occurred in 2 patients who underwent sternal turnover at their ages of 12 and 17. In 5 patients who underwent sternal elevation with metal plate or strut at their ages ranging from 13 to 26 years old, no major topical complication occurred, and most of them met with satisfactory results.

There were 5 patients with recurrence of the deformity (Fig. 3). Two patients who underwent turnover operation (free graft) at their ages of 9 and 12 had recurrence of the excavated deformity. A 6-year-old boy who underwent

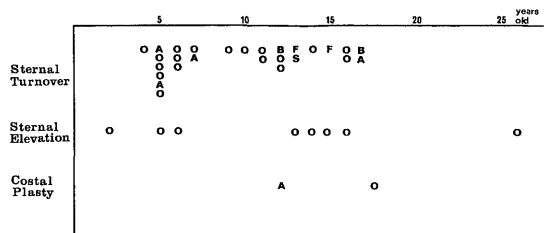


Fig. 2. Topical postoperative complications following surgical correction of pectus excavatum. A: subcutaneous abscess B: bone necrosis F: fistula S: skin necrosis O: none

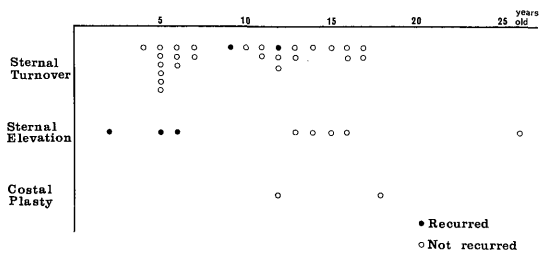


Fig. 3. Recurrence of the deformity after surgical repair of pectus excavatum.

sternal elevation had recurrence of the deformity, which required a reoperation 2 years after the first operation. In both of the patients who underwent sternal elevation with Kirschner wire, the results were not satisfactory because of recurrence of the deformity.

Satisfactory results were obtained in 29 of the 37 patients (78%), including 24 excellent and 5 good, followed for periods ranging from 2 to 8 years postoperatively (Fig. 4). The operative result was classified as fair in 4 patients, 3 of whom had recurrence of the excavated deformity. Two of the 4 patients whose results were classified as poor had recurrence of the deformity, one of which required a reoperation.

The postoperative complications after sternal turnover procedures occurred more frequently in the patients who underwent classical type of

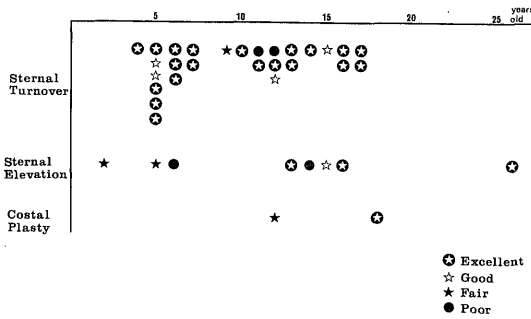


Fig. 4. Results of operations in 37 patients who underwent surgical correction of pectus excavatum.

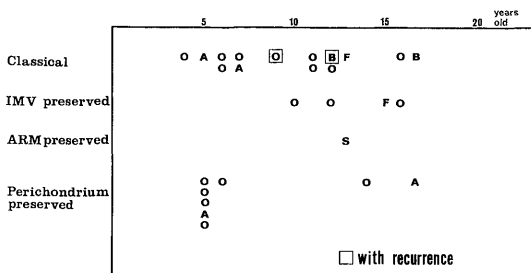


Fig. 5. Typical postoperative complications following sternal turnover operation.
 A: subcutaneous abscess
 B: bone necrosis
 F: fistula
 S: skin necrosis
 O: none
 IMV: internal mammary vessels
 ARM: abdominal rectus muscle

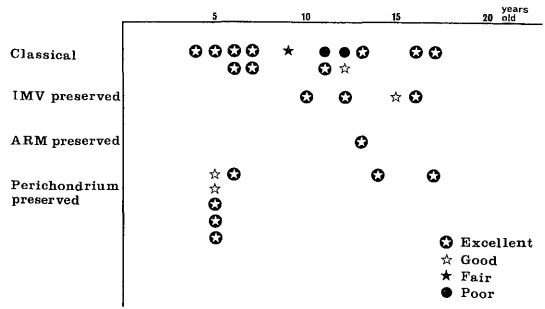


Fig. 6. Results of operations in 27 patients who underwent various types of sternal turnover operation.

the turnover operation. Two boys had recurrence of the deformity (Fig. 5). The excellent and good results were obtained in the patients with preservation of the perichondrium and preservation of blood supply (Fig. 6).

DISCUSSION

The existence of a significantly deep deformity in an infant or child constitutes the indication for the surgical repair of pectus excavatum¹². The operation is undertaken to correct the existing deformity and prevent its progression. Physicians and surgeons must take not only the postural and the cosmetic but also the physiologic effects of the deformity into consideration. Ordinarily, infants and children with pectus excavatum are thought to be asymptomatic but for the deformity, however, some severe deformities can lead to cardiac and respiratory compromise, which might improve dramatically after the corrective operation^{1, 11, 12}. Twenty-seven of the 37 patients (73%) in this series had symptoms, and 15 of the 29 patients (51%) showed impairment in respiratory function. Only 4 of the 37 patients showed normal ECG, and heart murmur was audible in 13 patients (35%). It might be a serious mistake to look on pectus excavatum as purely a cosmetic deformity. Many children with a pectus deformity are psychologically distressed with their appearance. They avoid exposing their chest and feel embarrassed in participation in sports and gymnastics^{1, 12, 19}.

A large number of techniques have been evolved, and no one method is universally

accepted as the optimal procedure for the surgical correction of pectus excavatum. Most of the current operative techniques are based on the method described by Ravitch¹²⁾. The basic procedures of Ravitch's method consist of subperichondrial resection of abnormal costal cartilages; freeing of the sternum from intercostal, pericardial and mediastinal attachments; and elevation of the depressed sternal segment. A variety of modifications and additions to this basic procedure have been made.

One of the major points of controversy is the use of metal struts, plates or wires for internal support to achieve stabilization of the sternum in corrected position. Holcomb⁷⁾ reported 94% satisfactory results using rib strut and stainless steel bar. Howard⁸⁾ reported 90% satisfactory results in 190 patients using rib strut. Wesselhoeft and DeLuca²²⁾ reported the use of a malleable metal strut passed transsternally, with excellent results in 70 of the 123 patients. A comparative study by Singh¹⁴⁾ using various surgical techniques disclosed that stabilization of sternum with stainless steel plate yielded the best results (36 excellent and 3 good) in 39 patients. Two patients in present series underwent sternal elevation with Kirschner wire and both of them had poor results because of recurrence of the deformity. Singh¹⁴⁾ reported 2 cases of recurrence in the 7 patients who underwent stabilization of the sternum with Kirschner pin. Watanabe and Iwa²¹⁾ as well as Takagi and Yamaga¹⁷⁾ reported the efficacy of the strut method using AO-plates²¹⁾ and a Zimmer osteosynthetic plate¹⁷⁾ over the sternum in adults and adolescents.

Many authors recommend methods without supporting material. Haller *et al.*⁴⁾ reported that 68 children obtained excellent reconstruction without prosthetic support or splints, using tripod fixation technique. Humphreys and Jaretzki⁹⁾ described the detail of their operative technique without internal support and reported minimal postoperative complications. Six years later they¹⁰⁾ reported late results of their patients with and without operation. Satisfactory results were obtained in 68 of the 106 operated patients (64%). However, when results were grouped according to the age at follow-up, the results

deteriorated with age (72% satisfactory results in children, 69% in adolescents and 55% in adults). Lacquet¹¹⁾ reported 80 to 100 percent satisfactory results in 134 patients without prosthetic support.

The sternoturnover technique has been used primarily in Japan, where a large series has been reported by Wada and colleagues²⁰⁾. This technique involves transecting the sternum and costal cartilages, turning the plastron over, and resuturing the sternum and costal cartilages. The sternal turnover technique has been attracting many surgeons, especially in Japan, where innumerable followers employ this technique and reported good results. Eversion of the sternum creates a good anterior chest wall contour, and the chest wall is very stable after repair. Since no struts or pins are used, a second operation for removal is avoided. Satisfactory results were obtained in 24 of the 27 patients (88%) in present series who underwent sternal turnover (20 excellent and 4 good). Davis and Shah²⁾ reported 15 cases of sternal turnover with excellent overall results. However, a few surgeons in Europe and America agree with the advantage of turnover technique. This method appears to be a very radical for children with pectus excavatum, and reversal of the sternum is rare in the United States because of fear concerning the fate of a large, devascularized piece of bone in the anterior mediastinum⁵⁾. Partial bone necrosis occurred in 2 of the 27 patients (7%) who underwent sternal turnover operation in present series. Taguchi *et al.*¹⁶⁾ proposed a sternal turnover procedure with preserved internal mammary vessels using crossover technique. Hawkins and colleagues⁵⁾ reported 81% satisfactory results in 26 patients using sternal eversion technique keeping one internal mammary vascular pedicle preserved. Hirayama *et al.*⁶⁾ devised a sternal turnover technique with preservation of internal thoracic artery and vein by means of microsurgical anastomosis, and proved the viability of the plastron and patency of the vessels by postoperative histopathological evaluation and angiography.

Although 88% satisfactory results were obtained in 27 patients in present series who underwent sternal turnover operation for sur-

gical correction of pectus excavatum, partial bone necrosis occurred in 2 patients, and recurrence of the excavated deformity occurred in 2 patients. These complication and unsatisfactory results were yielded in the patients who underwent the classical type of turnover operation at their ages over 9 years old. Therefore, the classical type of turnover technique is not thought to be preferable in older children and adolescents.

Since the subperichondrial dissection technique has been employed for free grafted sternal turnover operation, the results have been satisfactory without any major topical complication. The intercostal muscle attached to the devascularized ribs might become necrotic and cause the postoperative infection. Meticulous preservation of the perichondrium in resection of the plastron leaves the intercostal muscle, intercostal vessels and internal mammary vessels intact. Long-term correction of the deformity must rely on satisfactory further growth of the regenerated costal cartilages. Preservation of the perichondrium is essential to keep the costal cartilages viable. Engkvist³⁾ reported the experimental studies which revealed great potential of the perichondrium to regenerate cartilage.

REFERENCES

- 1) Bell, M. J., Bower, R. J. and Ternberg, J.L.: Selected Topics in Pediatric Surgery—Current Concepts of Diagnosis and Management. *Missouri Medicine* 78: 408 (1981)
- 2) Davis, M. V. and Shah, H. H.: Sternal Turnover Operation for Pectus Excavatum. *Ann. Thorac. Surg.* 17: 268 (1974)
- 3) Engkvist, O., Skoog, V., Pastacaldi, P. *et al.*: The Cartilaginous Potential of the Perichondrium in Rabbit Ear and Rib. *Scand. J. Plast. Reconstr. Surg.* 13: 275 (1979)
- 4) Haller, J. A., Shermeta, D. W., Tepas, J. J. *et al.*: Correction of Pectus Excavatum Without Prostheses or Splints: Objective Measurement of Severity and Management of Asymmetrical Deformities. *Ann. Thorac. Surg.* 26: 73 (1978)
- 5) Hawkins, J. A., Ehrenhaft, J. L. and Doty, D. B.: Repair of Pectus Excavatum by Sternal Eversion. *Ann. Thorac. Surg.* 38: 368 (1984)
- 6) Hirayama, T., Nozaki, M. and Wakamatsu, S.: A New Surgical Method for Repair of Funnel Chest. *Ann. Plast. Surg.* 14: 213 (1985)
- 7) Holcomb, G. W.: Surgical Correction of Pectus Excavatum. *J. Pediatr. Surg.* 12: 295 (1977)
- 8) Howard, R.: Funnel Chest: Results and Description of an Improved Operative Technique. *Med. J. Aust.* 2: 134 (1978)
- 9) Humphreys, G. H. and Jaretzki, A.: Operative Correction of Pectus Excavatum. *J. Pediatr. Surg.* 9: 899 (1974)
- 10) Humphreys, G. H. and Jaretzki, A.: Pectus Excavatum. —Late results with and without operation—. *J. Thorac. Cardiovasc. Surg.* 80: 686 (1980)
- 11) Lacquet, L. K.: Surgical Correction of Congenital Deformities of the Anterior Chest Wall. *Verh. K. Acad. Geneesk. Belg.* 47: 27 (1985)
- 12) Ravitch, M. M.: Disorders of the Sternum and the Thoracic Wall. In: *Surgery of the Chest*. 3rd ed. Sabiston, D. C. and Spencer, F. C. ed., p. 324. W. B. Saunders, Philadelphia 1976
- 13) Sanger, P. W., Robicsek, F. and Taylor, F. H.: Surgical Management of Anterior Chest Deformities: A New Technique and Report of 153 Operations Without a Death. *Surgery* 48: 510 (1960)
- 14) Singh, S. V.: Surgical Correction of Pectus Excavatum and Carinatum. *Thorax* 35: 700 (1980)
- 15) Singh, S. V.: The Changing Trend in Surgical Reconstruction of Pectus Excavatum. *Thorac. Cardiovasc. Surgeon* 29: 114 (1981)
- 16) Taguchi, K., Mochizuki, T., Nakagaki, M. *et al.*: A New Plastic Operation for Pectus Excavatum: Sternal Turnover Surgical Procedure with Preserved Internal Mammary Vessels. *Chest* 67: 606 (1975)
- 17) Takagi, K. and Yamaga, M.: A New, Modified Operation for Funnel Chest Using the Zimmer Osteosynthetic Plate. *Arch. Orthop. Trauma Surg.* 105: 154 (1986)
- 18) Wada, J.: Surgical Correction of the Funnel Chest "Sternoturnover". *West. J. Surg. Obst. Gynec.* 69: 358 (1961)
- 19) Wada, J.: Deformity of the Chest Wall. In: *Gendai Gekagaku Taikei* 29, Kimoto, S. *et al.* ed., P. 75. Nakayama Shoten, Tokyo 1968 (Japanese)
- 20) Wada, J., Ikeda, K., Ishida, T. *et al.*: Results of 271 Funnel Chest Operations. *Ann. Thorac. Surg.* 10: 526 (1970)
- 21) Watanabe, Y. and Iwa, T.: Surgical Correction of Pectus Excavatum for Adults and Adolescents. *Jpn. J. Surg.* 14: 472 (1984)
- 22) Wesselhoeft, C. W. and Deluca, F. G.: A

Simplified Approach to the Repair of Pediatric Pectus Deformities. *Ann. Thorac. Surg.* 34:640 (1982)