

## The Efficacy of Polydioxanone Monofilament Absorbable Suture for Tracheal Anastomosis

Katsunobu KAWAHARA, MD, Naoya YAMASAKI, MD, Satoshi YAMAMOTO, MD, Takeshi NAGAYASU, MD, Hiroyuki KUSANO, MD, Shinji AKAMINE, MD, Takao TAKAHASHI, MD, Akihiro NAKAMURA, MD, Kouji AZUMA, MD, Masao TOMITA, MD.

The First Department of Surgery, Nagasaki University School of Medicine, Nagasaki, Japan

To evaluate the efficacy of polydioxanone absorbable suture for tracheal anastomoses, we performed an experimental study using dogs. Eight adult mongrel dogs underwent sleeve resection of the mediastinal trachea. A length of ten to twelve cartilage rings was resected. An end-to-end anastomosis was performed using either interrupted or continuous running 4-0 polydioxanone (PDS) suture. There was no detectable difference bronchoscopically, microangiographically, or histologically, in tracheal anastomotic healing between interrupted suture and continuous running suture. The inflammatory tissue response was mild and disappeared 3 weeks after surgery. The breaking strength, however, was greater in dogs in which interrupted sutures were used than in those with a continuous running sutures. We conclude that PDS is a useful suture material for tracheal anastomoses and that interrupted sutures are stronger and possibly safer than a continuous running suture for end-to-end anastomosis following sleeve resection of the trachea.

**Key words:** Tracheal anastomosis, PDS, Polydioxanone, Absorbable sutures

### Introduction

The healing of the tracheal or bronchial anastomosis is affected by tension at the anastomoses, ischemia, and tissue reaction to suture materials. Severe tissue reaction caused by suture materials causes granulomas and may delay healing of the anastomoses, resulting in stricture formation. Anastomotic strictures and granulomas now rarely occur with the use of absorbable suture materials. Currently, the most commonly used absorbable sutures are: polyglycolic acid (Dexon plus; Davis & Grek, Willowdale, Ont.), polyglactin 910 (Vicryl; Ethicon Ltd., Peterborough, Ont.), polyglyconate (Maxon; Davis & Grek) and polydioxanone (PDS; Ethicon). The former two

are braided sutures and the other two are monofilament sutures. Monofilament sutures can reduce the infection rate compared with braided sutures (1). Monofilament absorbable sutures also have the additional advantages of smooth passage through tissue and production of minimal tissue reaction (2). PDS is a more flexible monofilament absorbable suture which produces minimal tissue reaction, but has great tensile strength. The tensile strength half-life of these absorbable sutures are: 2-weeks with Dexon Plus and Vicryl, 3-weeks with Maxon and 6-weeks with PDS (3). PDS, therefore, seems to be most appropriate for tracheal anastomosis which must withstand continuous tensile forces for many weeks. McKeown (4) reported that the degree of resultant stenosis was significantly less when PDS and an interrupted suturing technique were used. In this study, we experimentally evaluated the efficacy of PDS in performing canine tracheal anastomoses using either interrupted sutures or a continuous running suture.

### Methods

Eight adult mongrel dogs were anesthetized with intravenous administration of pentobarbiturate, intubated and ventilated by a Harvard mechanical ventilator with room air using a tidal volume of 250 mL, and a ventilatory rate of 16 breaths per minute. A right thoracotomy was performed, and the mediastinal pleura was divided. Lateral traction sutures were placed in the proximal and distal tracheal cartilages. Sleeve resection of the trachea, 10-12 cartilage rings in length, was performed. Tension on the anastomosis was determined to be from 700 to 800 gram weight. The intubation of the distal trachea was performed through the operating field, allowing ventilation. An end-to-end anastomoses of trachea was performed using interrupted sutures (Group 1, n=4) or a continuous running suture (Group 2, n=4) with 4-0 PDS. Postoperatively, bronchoscopic examination was performed. The animals then were sacrificed and subjected to postmortem microangiography 1, 3, 5 and 8 weeks after surgery. The breaking strengths of the tracheal anastomoses were

Address reprint requests to Dr. Katsunobu Kawahara  
The First Department of Surgery, Nagasaki  
University School of Medicine  
Sakamoto 1-Chome, 7-1, 852, Nagasaki, Japan  
TEL:0958-47-2111, FAX:0958-47-5034

measured by a tensiometer (Shimazu industry C.C). Histologic sections through the anastomosis were then cut and stained with hematoxylin-eosin. All dogs were maintained according to the National Society Medical Research Principles of Laboratory Animal Care.

#### *Postmortem microangiography*

The anesthetized and ventilated dog was administered 6000 units of heparin prior to bilateral ligation of the carotid arteries, the subclavian arteries, and the intercostal arteries. A catheter was placed in the thoracic aorta. The left atrium was opened, and the tracheal branches were flushed via the catheter, with 250 mL of saline solution prior to the perfusion with 250 mL of a warmed solution of 60% barium containing gelatin and agar-agar. The trachea and carina were removed and radiographs were taken by Softex using Fuji Softex Film. The exposure settings were 40 kilovolt, 3 miliampere and 10 seconds.

#### *Breaking strength*

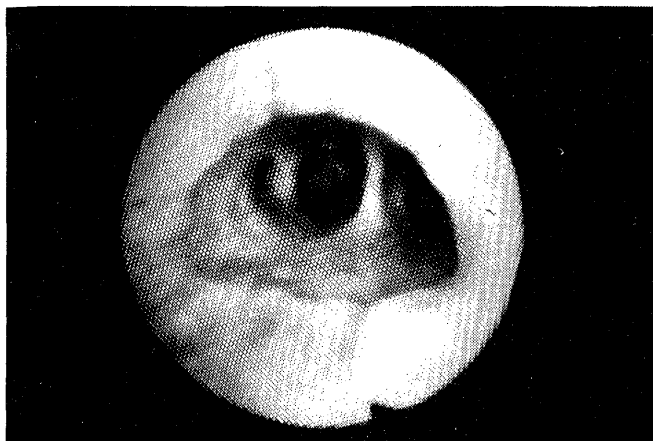
Slices of the anastomoses of the tracheal cartilage 1 cm in width and 2 cm in length were obtained. Tensile strength was measured using the Autograph (Shimazu Co. Tokyo). A crosshead speed of 1mm/sec to the point of suture line breakage was used.

#### **Results**

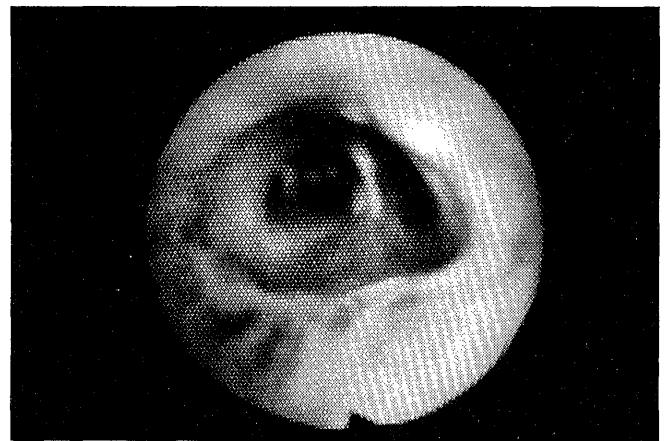
All animals survived uneventfully, until they were sacrificed from one to 8 weeks postoperatively.

#### *Bronchoscopic findings*

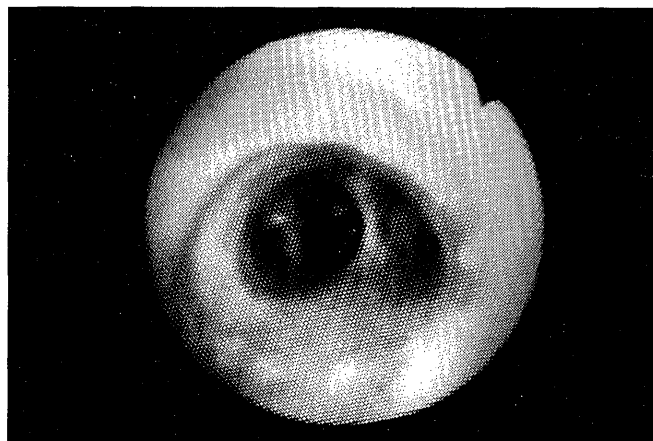
In both groups, bronchoscopy of anastomoses revealed slight edema and redness one week after surgery and a normal appearance 3 weeks postoperatively. No erosions or ulcers were observed in either group during the experi-



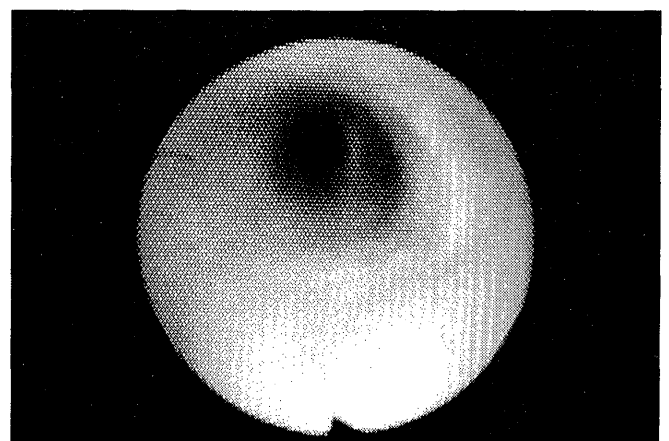
A



B



C



D

**Figure 1:** Bronchoscopic photographs of tracheal anastomoses: (A) with interrupted sutures one week postoperatively, (B) with a continuous running suture one week postoperatively, (C) with interrupted sutures four weeks after surgery, (D) with a continuous running suture four weeks after surgery.

ment. Stricture or granuloma formation did not occur in either group (Figure 1).

*Microangiographic findings*

Microangiographically, the reconstruction of bronchial

arteries was complete by one week after operation. No hypervascularity was observed in either group (Figure 2, 3). The bronchial arteries of the tracheal anastomoses were observed both in the tracheal adventitia and also in the submucosal layer.


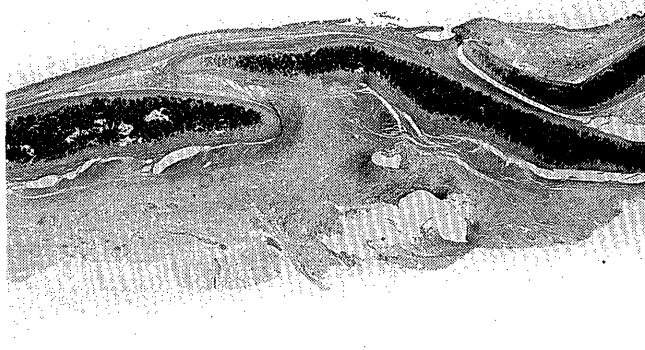


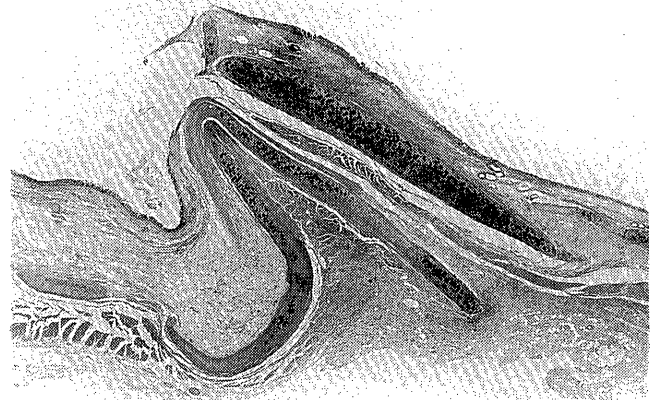
Figure 2: Microangiograms of the tracheal anastomoses, performed one week postoperatively: (A) with interrupted sutures, (B) with a continuous running suture.




Figure 3: Sectional aspects of the microangiography of tracheal anastomoses performed (A) with interrupted sutures and (B) with a continuous running suture as demonstrated one week postoperatively.



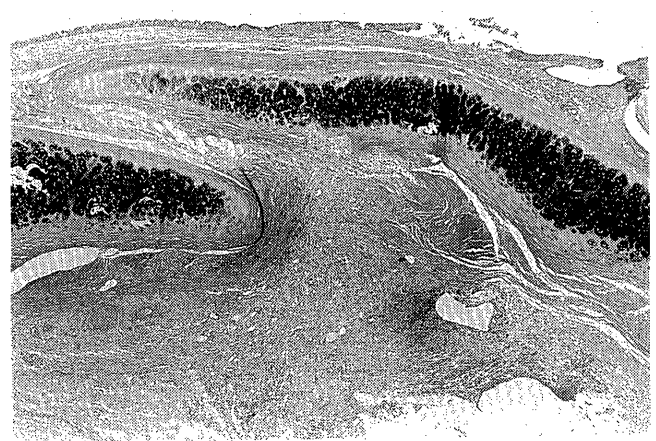
A



B

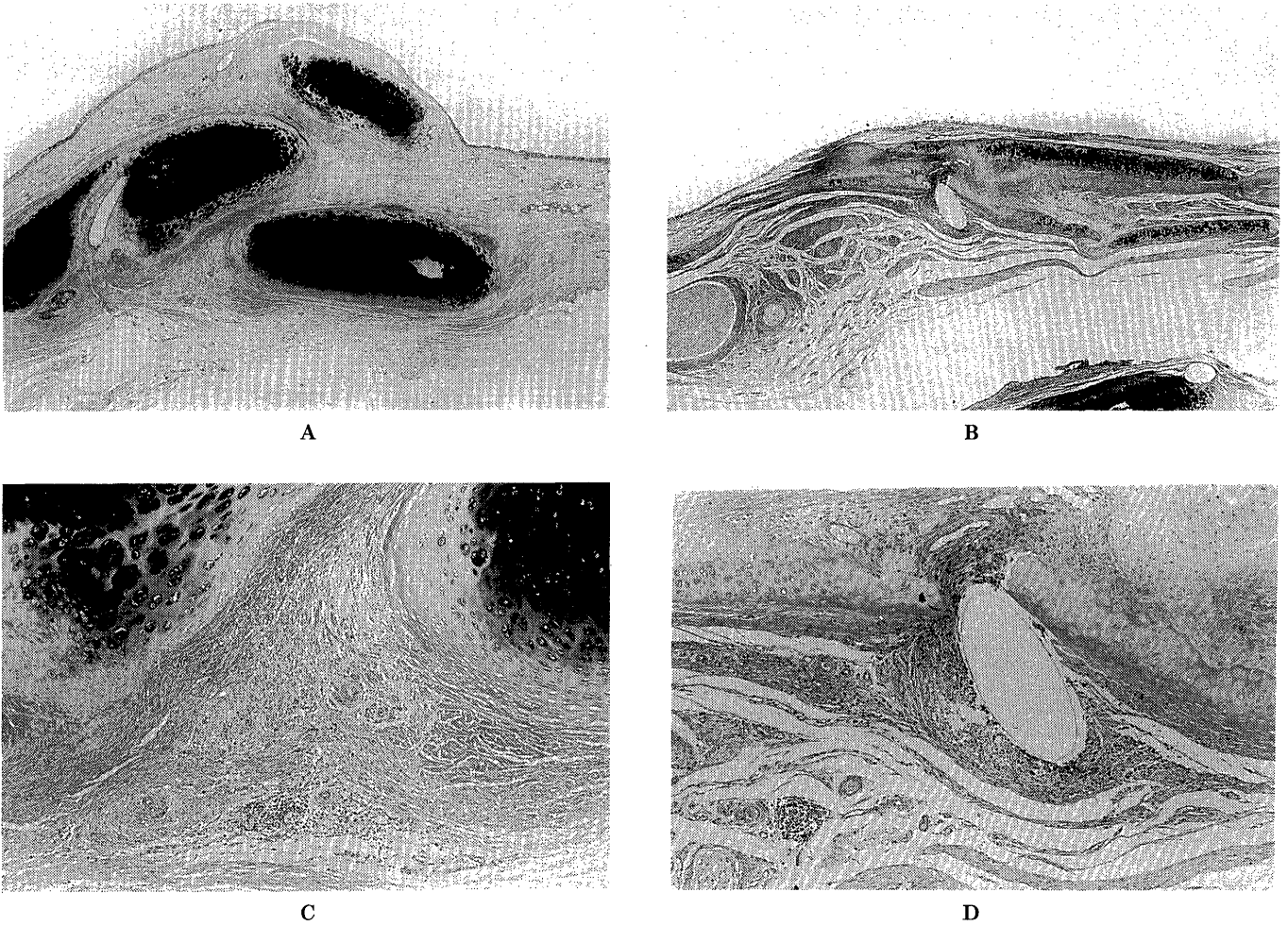


C



D

Figure 4: Photomicrographs taken one week after surgery of tracheal anastomoses: (A) performed with interrupted sutures; (B) with a running suture (magnification is  $4 \times 2.5$ ); (C) interrupted anastomosis at  $4 \times 5$  magnification; (D) running anastomosis at  $4 \times 5$  magnification.



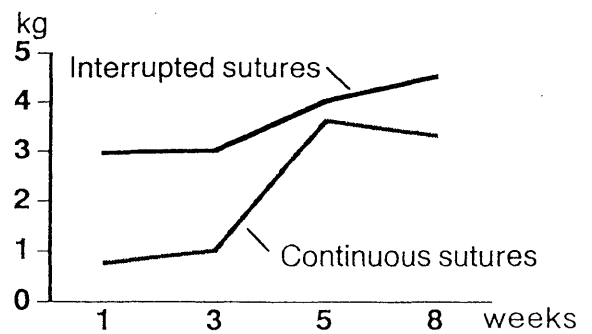
**Figure 5:** Photomicrographs taken at low and high power eight weeks after surgery. (A) anastomosis with interrupted sutures; (B) anastomosis with a running suture; (C) anastomosis with interrupted sutures at high power; (D) anastomosis with a running suture at high power.

*Histologic findings*

Histologically, mild cell infiltration and fibrotic changes were observed in anastomoses one week after surgery (Figure 4). Inflammatory changes disappeared 3 weeks after surgery in both groups. Mild cell infiltration was observed around a suture 8 weeks postoperatively (Figure 5).

*Breaking strength*

The breaking strength of the tracheal anastomoses with interrupted PDS sutures was higher than in those with a continuous running PDS suture. The breaking strength in Group 1 was 2.9 kg one week, 3.0 kg 3 weeks and 4.0 kg 5 weeks after surgery (Figure 4). While the breaking strength in Group 2 was 0.8kg one week, 1.0 kg 3 weeks and 3.6 kg 5 weeks after surgery.



**Figure 6:** This graph demonstrates the measured breaking strength of the tracheal anastomoses in groups using either a continuous running suture or interrupted suture. The graph demonstrates the superior strength of the interrupted anastomosis which is maintained over time.

**Discussion**

In this study, our data demonstrated that PDS is useful for tracheal anastomoses and that interrupted sutures are

equivalent to a continuous running suture of PDS in terms of tissue reaction, vascular reconstruction, and breaking strength. Tissue reaction for PDS was minimal and there was no difference in the vascular reconstruction at the tracheal anastomoses between interrupted sutures and the continuous running sutures. The breaking strength at the anastomoses with a running PDS suture was less than that in those where interrupted PDS sutures were used. When the breaking strength of the anastomosis was measured, both ends of the running suture were free and not fixed. Therefore, the suture was pulled out and could not support the tissues when tensile forces were applied. Several stitches remained in the slice of anastomotic tissues with interrupted sutures and it was therefore felt that each stitch contributed toward maintaining the anastomosis. If an end-to-end tracheal anastomosis is performed, using a continuous running suture following sleeve resection, trivial tissue injury due to tensile forces or ischemia in the

early postoperative period may result in a lethal anastomotic dehiscence. Interrupted sutures may be safer for end-to-end tracheal anastomoses which can withstand continuous tensile forces.

## References

1. Usher FC, Allen JE, Costhwait RW, Cogan JE. Polipropylene monofilament; a new biologically inert suture for closing contaminated wounds. *JAMA* 179: 780-782: 1962.
2. Lerwick E, Studies on the efficacy and safety of polydioxanone monofilament absorbable suture. *Surg Gynecol Obstet* 156: 51-55: 1983.
3. Bourne RB, Bitar H, Andrae PR, Martin LM, Finlay JB, Marquis F. In-vivo comparison of four absorbable sutures: Vicryl, Dexon Plus, Maxon and PDS. *The Canadian Journal of Surgery* 31: 43-45: 1988.
4. Mckeown P, Tsuboi H, Togo T, Thomas R, Tudk R, Gordon D, Growth of tracheal anastomoses: advantage of absorbable interrupted sutures. *Ann Thorac Surg* 51: 636-41: 1991.