

Case Report

Chemosensitivity of a Recurrent Desmoid Tumor with Increased Osteopontin Expression and a Novel Frame-Shift Mutation at Codon 1564 of the *APC* Gene

Naomi HAYASHIDA,¹ Shigeto MAEDA,¹ Yoshitsugu TAJIMA,² Sadanori OKUDAIRA,² Sumihiro MATSUZAKI,² Katsumi TANAKA,³ Tomayoshi HAYASHI,⁴ Jun-ichirou FURUI,^{1,2} Takashi KANEMATSU^{1,2}

¹Division of Endocrine Surgery, Nagasaki University Graduate School of Biomedical Sciences, Nagasaki, Japan

²Division of Hepato-Biliary Pancreatic Surgery, Nagasaki University Graduate School of Biomedical Sciences, Nagasaki, Japan

³Division of Plastic and Reconstructive Surgery, Nagasaki University Graduate School of Biomedical Sciences, Nagasaki, Japan

⁴Department of Pathology, Nagasaki University Hospital, Nagasaki, Japan

In this report, we describe a case of recurrent desmoid tumor that was characterized by a novel *APC* gene mutation and osteopontin (OPN) expression. A 20-year-old female patient with adenomatous polyposis underwent a right colectomy at 13 years of age. Five years later, she developed an abdominal desmoid tumor that was resected. After 2 more years, a recurrent desmoid tumor was found in the same region. This tumor grew rapidly and quickly became massive. The doubling time was estimated to be 122 days, based on the computed tomography findings. When we analyzed the *APC* gene in the recurrent desmoid tumor, we found a novel frame-shift mutation at codon 1564. This frame-shift mutation changed TTA to TAG, which is a stop codon. Northern blot analysis and immunohistochemical analysis for OPN, a GRGDS (glycine-arginine-glycine-aspartic acid-serine)-containing adhesive molecule, revealed abundant amounts of OPN mRNA and protein expression in this desmoid tumor. We postulated that the truncated *APC* protein and OPN expression might be involved in the invasive nature of this recurrent desmoid tumor. A primary cell culture derived from the desmoid tumor was assessed for chemosensitivity to 5-fluorouracil, cisplatin, doxorubicin, colchicine, docetaxel, and anti-OPN antibody. Docetaxel was found to have the strongest inhibitory effect on cell growth. As a result, docetaxel was administered to this patient (60 mg/m²/month) for 3 cycles. Over the next 2 years, no detectable recurrences occurred. Thus, docetaxel was clinically effective for the treatment of a recurrent desmoid tumor.

ACTA MEDICA NAGASAKIENSIA 50: 39 - 43, 2005

Keywords: Desmoid tumor; Chemosensitivity; *APC* gene

Introduction

Desmoid tumors (infiltrative fibromatosis) affect approximately 10% of all patients with familial adenomatous polyposis. Desmoid tumors are by definition nonmalignant; but these tumors are probably neoplastic in origin and may sometimes arise in association with germline or somatic mutations beyond codon 1444 of the *APC* gene.¹ Desmoid tumors often lead to life-threatening complications because of infiltration and the obstruction of surrounding structures. Treatment is often difficult, and such lesions tend to have a high frequency of recurrence after surgical excision. These lesions do not metastasize, and they may even undergo spontaneous regression. No effective

chemotherapy for desmoid tumors has yet been identified.

APC gene mutations in desmoid tumors tend to occur in the 3' region.² The severity of desmoid tumors might depend on the site of the *APC* mutation. Gebert et al.³ reported that desmoid tumors with the most severe manifestations contained mutations between codons 1444 and 1581. Therefore, we examined the desmoid tumor in this case report for a mutation in the 3' portion of the *APC* gene that might be involved in the recurrence and invasive nature of this tumor.

Osteopontin (OPN), a bone matrix protein, may also be involved in tumor cell attachment and migration.^{4,6} OPN is an acidic, sulfated glycoprotein that is primarily secreted by osteoblasts and osteoclasts.

Address correspondence: Shigeto Maeda, M.D., Division of Endocrine Surgery, Nagasaki University Graduate School of Biomedical Sciences, 1-7-1 Sakamoto, Nagasaki, 852-8501 JAPAN

TEL: +81-(0)95-849-7316, FAX: +81-(0)95-849-7319, E-mail: maedas@net.nagasaki-u.ac.jp

Received February 9, 2005; Accepted March 8, 2005

OPN is thought to play a role in bone resorption and possibly bone formation by binding to hydroxyapatites. OPN contains a GRGDS (glycine-arginine-glycine-aspartic acid-serine) sequence near the center of the single chain. This GRGDS sequence is reminiscent of sequences in cell attachment proteins that are known to interact with cell surface integrins. OPN functions in adhesive interactions at the tumor-host interface and thereby may influence such processes as invasion and metastasis.⁴

The purposes of the present study are: (1) to determine whether an *APC* gene mutation and osteopontin protein are associated with this recurrent invasive desmoid tumor; and (2) to evaluate the chemosensitivity of a primary cell culture from recurrent desmoid tumors.

Case Report

A 20-year-old female was admitted to our hospital with a diagnosis of a recurrent desmoid tumor in the abdomen. She had previously undergone a right colectomy for adenomatous polyposis at 13 years of age. A histological examination of the polyposis revealed

that it was a papillo-tubular adenoma of the colon. The patient had no known family history of colorectal disease. At 18 years of age, she was found to have an abdominal tumor. This tumor was surgically removed, and the histological diagnosis of a desmoid tumor was made. Two years later, a recurrent desmoid tumor was identified in the same area of the patient's abdomen. The tumor grew rapidly and quickly became massive. The doubling time was estimated to be 122 days, based on follow-up computed tomography (Figure 1). When the patient was admitted to the hospital, the diameter of the desmoid tumor was approximately 30 cm. Indirect ophthalmoscopy revealed no abnormalities that would indicate congenital hypertrophy of the retinal pigment epithelium. The desmoid tumor was resected, and reconstruction was performed using the fascia lata of the right femur. The patient was treated with sulindac, but another recurrent desmoid tumor occurred in the same region 6 months later. The 3rd recurrent desmoid tumor was also resected. Based on the chemosensitivity of a primary culture from the desmoid tumor, docetaxel was administered for 3 months. The docetaxel treatment proved to be successful, and the patient has remained healthy with no recurrence for two years.

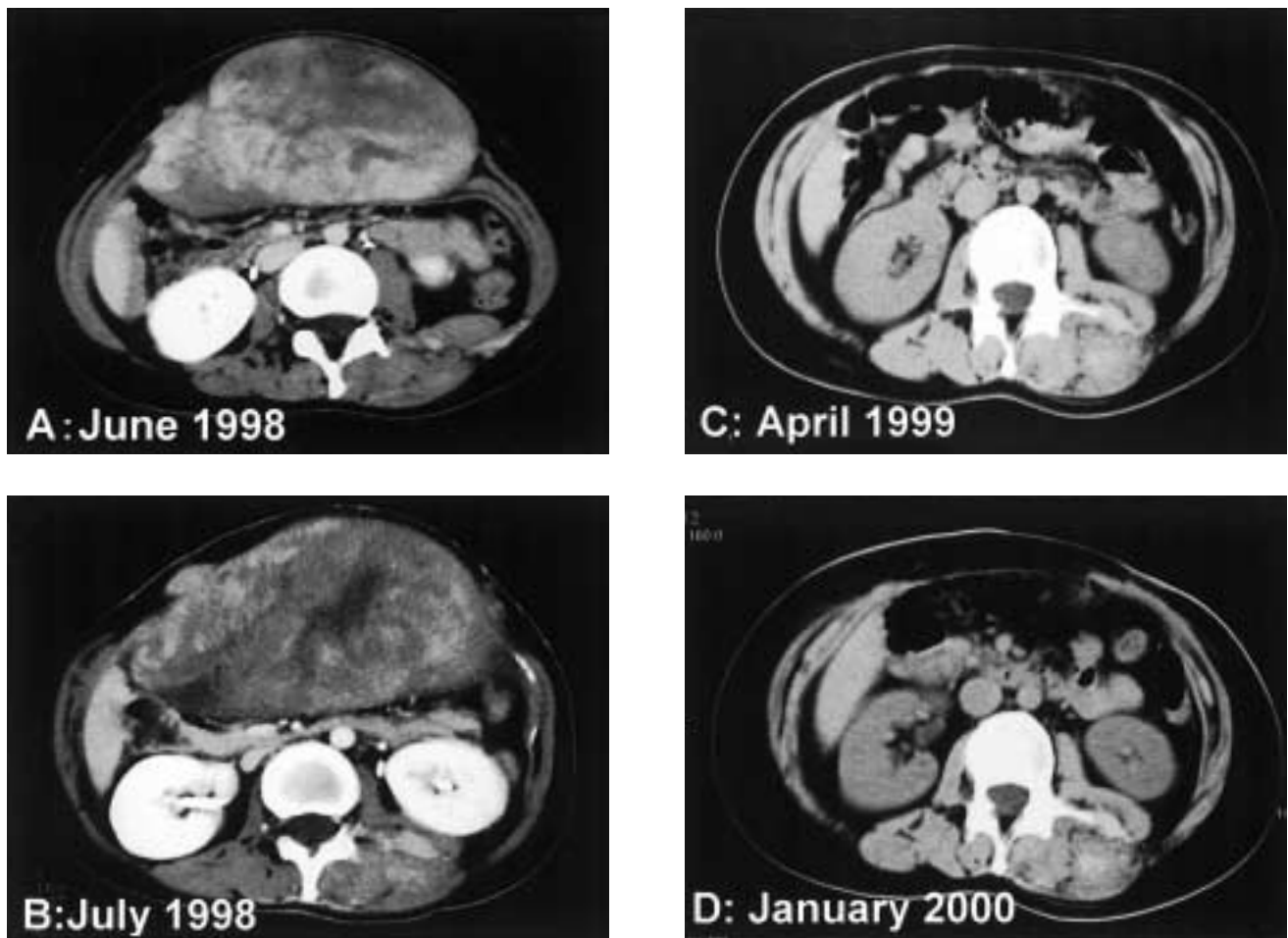


Figure 1. Computed tomography images of a desmoid tumor. The tumor was 25 × 23 cm in diameter at the first recurrence (A) and 28 × 35 cm at the second recurrence 6 months later (B). The doubling time was estimated to be 122 days. After the resection and docetaxel treatment, no recurrent tumor was detected for 2 years (C) and (D).

Materials and Methods

Specimens

A tumor specimen was immediately frozen and used for genetic analysis after obtaining written informed consent from the patient. To prepare primary cultures of tumor cells, the tumor was minced, and cells were grown in RPMI 1640 medium containing 10% fetal bovine serum (Gibco BRL, NY).

RNA isolation

Total RNA was isolated from frozen tissue specimens by the standard guanidine isothiocyanate method (Gibco BRL, NY).⁷

RT-PCR

Primers for the APC gene from nucleotide 3000 to 6000 were designed using primer 3 through the internet (http://www-genome.wi.mit.edu/cgi-bin/primer/primer3_www.cgi). The primers were: APC 4400 forward primer (GTGAACCATGCAGTGGGAATG); APC 4400 reverse primer (CACTCAGGCTGGATGAACAA); APC 5700 forward primer (ACCTCCAACCAACAATCAGC); and APC 5700 reverse primer (GGTTCTCCCTGTGAGTCAGG). A total of 1-2 µg of RNA were used for reverse transcription (RT). The PCR conditions were 95 °C for 1 min, 52 °C for 1 min, and 72 °C for 1 min for 35 cycles.

Northern blot analysis

Various amounts of total RNA were loaded onto a 1.2 % agarose gel containing 10% formaldehyde and were then transferred to a nylon membrane (Hybond-N, Amersham Pharmacia Biotech, Tokyo, Japan). A cDNA probe for OPN was amplified by PCR and radioactively labeled with ³²P using random hexamer priming (Boehringer Mannheim, Mannheim, Germany), according to the manufacturer's instructions. The predicted size for OPN is 1.4 Kb (Figure 2).

Direct sequence

The PCR products amplified by the APC primers underwent direct sequencing (ABI 373A Applied Biosystems, Japan) after subcloning. Sequencing was performed in both directions for the regions of interest to detect any mutations.

Immunohistochemistry

Immunohistochemistry was performed using the ABC procedure, according to the manufacturer's instructions. Antibodies for P53 (DAKO, Glostrup, Denmark), matrix metalloproteinase (MMP) 1, MMP 2, MMP 7 (Fuji Chemical Industries, Takaoka, Japan), estrogen receptor alpha (C-314) (Santa Cruz, CA), progesterone receptor (AB-52) (Santa Cruz, CA), and OPN (IDL, Fujioka, Japan) were purchased. The immunohistochemical analyses of actin (al-

pha-smooth muscle actin, HHF35, Glostrup, Denmark), desmin, and CD34 (Immunotech S.A., Marseille, France) were kindly evaluated by Dr. Hiroshi Hashimoto (University of Occupational and Environmental Health, Kitakyushu, Japan).

In vitro chemosensitivity

The primary cell cultures were maintained at 37 °C for 3 days. Then, a total of 10⁶ cells were seeded into 24-well flasks. When the cells reached 70% confluency, they were exposed to docetaxel (Aventis Pharma Co., Tokyo, Japan), 5-fluorouracil (5-FU) (Kyowa Hakko Co., Tokyo, Japan), or cisplatin (Nihon Kayaku Co., Tokyo, Japan) for 72 hours at 10-times the normal clinical dose. Cells were also exposed to colchicines (1.37 ng/mL) or OPN antibody (1 mg/mL). The chemosensitivities of the cells were evaluated by an assay using (3-(4, 5-dimethylthiazol-2-yl) -2, 5-diphenyl tetrazolium bromide: MTT) (Molecular Probes, Oregon), and the findings were compared to the untreated control cells.⁸

Results

Direct sequence

A novel frame-shift mutation was detected at codon 1564 of the APC gene. Sequencing of the fragment showed a 1 base pair deletion at codon 1564 that changed the sequence from GAC CTA TTA GAT to GAC CTA TAG. Thus, the deletion caused a frame-shift mutation that created a stop codon (Figure 2).

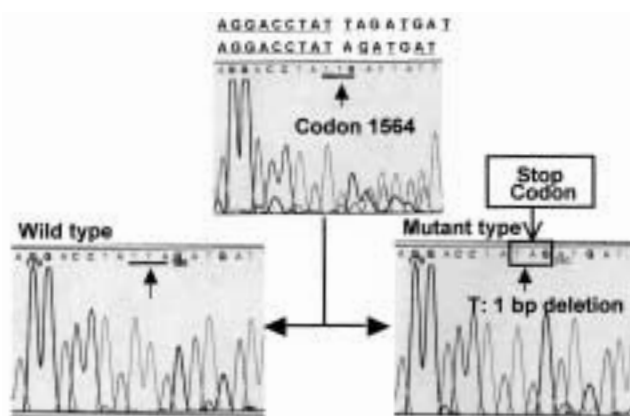


Figure 2. Mutation analysis for the APC gene. A novel frame-shift mutation (1 bp deletion) at codon 1564 of APC was detected in one allele. This mutation creates a stop codon.

Northern blot analysis

Northern blot analysis revealed abundant expression of OPN mRNA in the recurrent desmoid tumor. In fact, the expression level in the desmoid tumor was markedly higher than the expression level in the MCF-7 breast cancer cell line, which also expresses OPN mRNA and was used as a positive control (Figure 3).

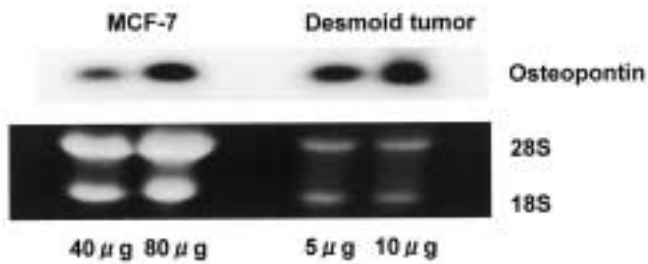


Figure 3. Northern blot analysis for OPN. Various amounts of total RNA were loaded onto a 1% agarose gel. The desmoid tumor expressed much larger amounts of OPN mRNA than MCF-7 cells, which also expressed a relatively large amount of OPN.

Immunohistochemistry

Many tumor cells were positive for actin. The tumor cells were negative for desmin and CD34. These findings support the myofibroblastic nature of the tumor cells (data not shown). The cytoplasm of the recurrent desmoid tumor was markedly stained with the OPN antibody, despite the fact that no staining was seen in the previous desmoid specimen (Figure 4). There was no staining for estrogen receptor

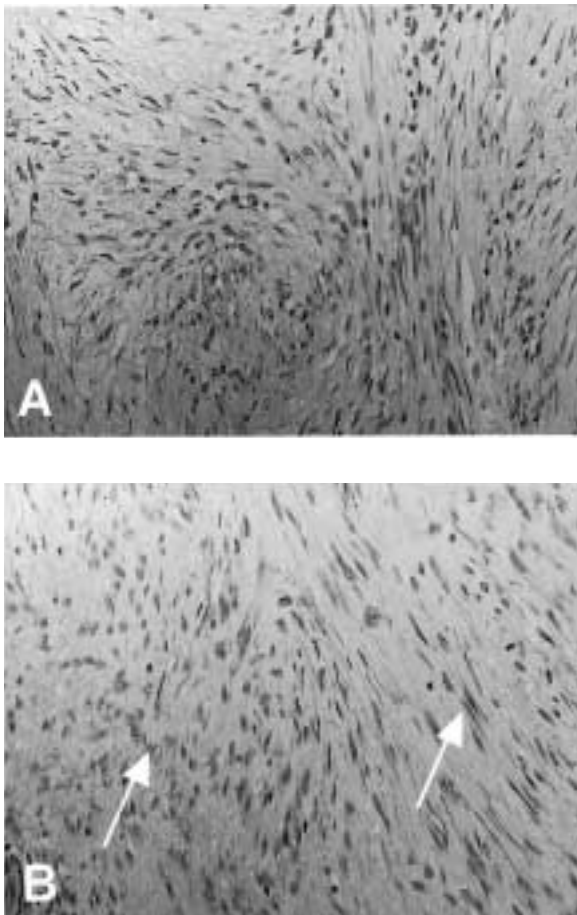


Figure 4. Immunohistochemistry for OPN. The recurrent desmoid tumor showed OPN staining in the cytoplasm (B), but the original desmoid tumor did not show any OPN staining (A).

alpha, progesterone receptor, p53, MMP 1, MMP 2, and MMP 7 (data not shown).

MTT assay

An MTT assay showed that docetaxel had a more powerful growth inhibitory effect than cisplatin, 5-FU, and colchicine. OPN antibody did not inhibit cell growth (Figure 5).

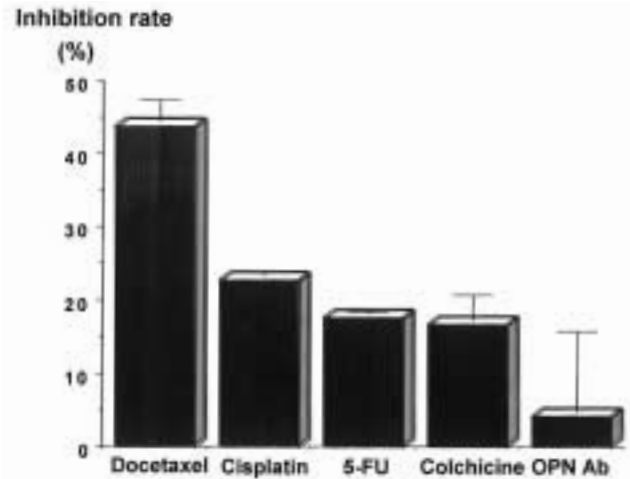


Figure 5. In vitro chemosensitivity. The chemosensitivity of desmoid tumor cells to docetaxel, cisplatin, 5-FU, colchicine, and OPN antibody was evaluated by MTT assay. Docetaxel had the greatest growth inhibitory effect.

Discussion

In the present study, a rapidly growing, recurrent desmoid tumor, characterized by an *APC* mutation and osteopontin mRNA expression, demonstrated chemosensitivity to docetaxel. A mutation analysis revealed that the *APC* gene was truncated at codon 1564. This heterogeneous stop codon might cause insufficient function of the normal APC protein. Homozygous inactivation of the *APC* gene has been identified in desmoid tumors, and the normal *APC* gene is a dominant negative regulator of growth in cells of mesenchymal origin as well as epithelial origin.⁹ Germline mutations after codon 1339 are associated with a high incidence of desmoid tumors.¹⁰ Severe manifestations of desmoid tumors are restricted to those with mutations between codons 1444 and 1581.³ Therefore, it is reasonable to hypothesize that the mutation at codon 1564 of APC might play an important role in the development of recurrent desmoid tumors. In addition, mutations between codon 1445 and 1578 may also preferentially cause both duodenal adenomas and desmoid tumors.¹¹ These findings emphasize the importance of screening the upper gastrointestinal tract, even when colonic disease is undetectable. Until now, no upper gastrointestinal diseases have been detected in this patient. Despite being locally aggressive, desmoid tumors have not been observed to undergo malignant transformation. We identified a heterogeneous somatic mutation of the *APC* gene in our

patient's desmoid tumor. Another important function of APC is to block cell cycle progression from G1 to S phase.¹² Mutant APC may be unable to stop the cell cycle. Thus, rapid cell growth may be caused by the loss of the cell cycle inhibitory effect in mutant APC. This is one of the reasons why this patient's desmoid tumor grew rapidly. Although desmoid tumors are benign, their doubling time is as rapid as that of malignancies. As a result, the mutated APC gene may be involved in the rapid growth. We therefore made a primary culture and attempted to measure the growth rate.

However, Hashimoto et al. reported that tumors with hypervascular areas more frequently recurred after surgery than those with hypovascularity. It remains difficult to predict recurrence based on histopathological findings alone. It is therefore necessary to evaluate other environmental factors.

OPN protein clearly has a cell attachment capacity for many different cell types, including osteoblasts, osteoclasts, and many transformed cells.⁴ Based on RT-PCR findings and a northern blot analysis, we found that the degree of OPNmRNA expression was remarkably high in this recurrent desmoid tumor. In addition, OPN protein was also immunohistochemically detected. Interestingly, the initial desmoid tumor did not express OPN. As a result, desmoid tumors are presumed to only express OPN during the process of recurrence. So, the significant expression of OPN may be associated with the ability of the desmoid tumor to reoccur. The recurrent desmoid tumor appeared to attach itself to the surrounding tissues via an OPN-integrin interaction. When we examined the effect of OPN antibody on desmoid tumor cells *in vivo*, we found that the OPN antibody did not inhibit tumor cell growth. These results suggest that OPN plays a role in cell attachment during local recurrence, but it is not associated with rapid growth.

The precise relationship between desmoid tumors and the hormonal environment remains to be elucidated; but, exogenously administered endocrine therapies might have an inhibitory effect on some desmoid tumors.^{13,14} In our patient's desmoid tumor, there was no expression of estrogen receptor or progesterone receptor (data not shown). No effective chemotherapy for desmoid tumors has been identified. Therefore, we evaluated the chemosensitivity of this desmoid tumor. We found that docetaxel had a powerful inhibitory effect on recurrent desmoid tumor cells *in vitro*. Based on this finding, we administered docetaxel to the patient.

In conclusion, docetaxel was found to effectively treat a recurrent desmoid tumor that expressed a large amount of OPN and contained an APC mutation at codon 1564.

Acknowledgments

We thank Dr. Hiroshi Hashimoto, University of Occupational and Environmental Health, Kitakyushu, Japan, for valuable assistance in the histopathological examination.

References

1. Clark SK, Phillips RK. Desmoids in familial adenomatous polyposis. *Br J Surg* 83: 1494-1504, 1996
2. Gardner RJ, Kool D, Edkins E et al. The clinical correlates of a 3' truncating mutation (codons 1982-1983) in the adenomatous polyposis coli gene. *Gastroenterology* 113: 326-331, 1997
3. Gebert JF, Dupon C, Kadmon M et al. Combined molecular and clinical approaches for the identification of families with familial adenomatous polyposis coli. *Ann Surg* 229: 350-361, 1999
4. Brown LF, Papadopoulos-Sergiou A, Berse B et al. Osteopontin expression and distribution in human carcinomas. *Am J Pathol* 145: 610-623, 1994
5. Senger DR, Perruzzi CA. Cell migration promoted by a potent GRGDS-containing thrombin-cleavage fragment of osteopontin. *Biochim Biophys Acta* 1314: 13-24, 1996
6. Sung V, Gilles C, Murray A et al. The LCC15-MB human breast cancer cell line expresses osteopontin and exhibits an invasive and metastatic phenotype. *Exp Cell Res* 241: 273-284, 1998
7. Chomczynski P, Sacchi N. Single-step method of RNA isolation by acid guanidinium thiocyanate-phenol-chloroform extraction. *Ann Biochem* 162: 156-159, 1987
8. Kratzke RA, Kramer BS. Evaluation of *in vitro* chemosensitivity using human lung cancer cell lines. *J Cell Biochem Suppl* 24:160-164, 1996
9. Sen-Gupta S, Van der Luijt RB, Bowles LV et al. Somatic mutation of APC gene in desmoid tumour in familial adenomatous polyposis. *Lancet* 342: 552-553, 1993
10. Sturt NJH, Gallagher MC, Bassett P et al. Evidence for genetic predisposition to desmoid tumours in familial adenomatous polyposis independent of the germline APC mutation. *Gut* 53: 1832-1836, 2004
11. Leggett BA, Young JP, Biden K, et al. Severe upper gastrointestinal polyposis associated with sparse colonic polyposis in a familial adenomatous polyposis family with an APC mutation at codon 1520. *Gut* 41: 518-521, 1997
12. Baeg GH, Matsumine A, Kuroda T et al. The tumour suppressor gene product APC blocks cell cycle progression from G0/G1 to S phase. *EMBO J* 14: 5618-5625, 1995
13. Oohata Y, Mibu R, Uehara S, et al. Regression of an aggressive abdominal desmoid tumor in a patient with familial adenomatous polyposis by hyperthermoradiotherapy. *Am J Gastroenterol* 92: 156-158, 1997
14. Lynch HT, Fitzgibbons R, Jr. Surgery, desmoid tumors, and familial adenomatous polyposis: case report and literature review. *Am J Gastroenterol* 91: 2598-2601, 1996