

Case Report

Duodenocolic Fistula Originating from Ascending Colon Cancer in the Blind Loop

Shigetoshi MATSUO,¹ Takashi AZUMA,¹ Nozomu SUGIYAMA,¹ Seiya SUSUMU,¹ Satoshi YAMAGUCHI,¹ Kuniko ABE²

¹Departments of Surgery, Nagasaki Prefectural Shimabara Hospital, Shimabara, Nagasaki, Japan

²Departments of Pathology, Nagasaki Prefectural Shimabara Hospital, Shimabara, Nagasaki, Japan

We herein present the case of a 68-year-old male with a duodenocolic fistula originating from ascending colon cancer in the blind loop, which was resected by a right hemicolectomy with pancreaticoduodenectomy. The present case achieved 14 months of disease-free survival after the operation. There have been reported, in the literature in Japanese and English, a total of 26 cases including the present one that have undergone a right hemicolectomy with pancreaticoduodenectomy for right-sided colon cancer with duodenocolic fistulae. The survival periods in these cases ranged from 5 months to 12 years after the operation. Thirteen patients survived for over 1 year. A right hemicolectomy with pancreaticoduodenectomy for locally advanced right-sided colon cancers with duodenal invasion could be expected to yield long-term survival if peritoneal and distant metastases are not present.

ACTA MEDICA NAGASAKIENSIA 51: 65 - 68, 2006

Keywords: Ascending colon cancer; Duodenum; Fistula

Introduction

With endoscopic and radiological advances, many gastrointestinal malignancies could be diagnosed in the early stages. Advanced colon cancers usually result in bowel obstruction, except those with an extrinsic growth or a development in the blind loop. Duodenocolic fistula is a rare condition that results from right-sided colon cancer. The most complicated symptom of duodenocolic fistula is feculent vomiting or belching that is attributed to the regurgitation of feces into the duodenum. We present herein a case of duodenocolic fistula originating from ascending colon cancer in the blind loop, which was resected by a right hemicolectomy (RH) with pancreaticoduodenectomy (PD). We discuss the benefit of surgery as a treatment for this condition as described in the literature in Japanese and English.

Case report

A 68-year-old male was admitted to Nagasaki Prefectural Shimabara Hospital complaining of a painful palpable mass in the right upper quadrant region on August 12, 2004. During the four months preced-

ing his admission, he underwent various studies in another Hospital. Transverse colon cancer was suspected based on the results of an enema study, but a colonofiberscopy did not detect the lesion. Cholecystitis without stones was finally diagnosed. In his past history, the patient received an appendectomy at the age of 25 years. At the age of 38 years, the patient underwent an ileotransversostomy to treat a small bowel obstruction. On admission, a 10×10 cm hard mass was palpated in the right upper quadrant. The results of complete blood counts were as follows: erythrocytes $338 \times 10^4/\text{mm}^3$; leukocytes $9200/\text{mm}^3$; hemoglobin 8.0 g/dL. The blood chemistry was found to be as follows (the parenthetic entries refer to the range of standard values): total protein 5.3 g/dL (6.2-8.3 g/dL); albumin 3.1 g/dL (4.0-5.0 g/dL); C-reactive protein 4.06 mg/dL (<0.30 mg/dL). Tumor markers such as carcinoembryonic antigen and cancer antigen 19-9 were within normal limits. An upper gastrointestinal series by Gastrografin[®] showed an apple-core-like lesion of the ascending colon via a fistula (Figure 1). Gastroscopy showed fecal matter in the stomach and the duodenum and tumor invasions into the duodenum (Figure 2). Biopsied specimens revealed an adenocarcinoma. A Gastrografin[®] enema also revealed an apple-core-like lesion in the ascending colon with duodenocolic fistula

Address correspondence: Shigetoshi Matsuo, M.D., Department of Surgery, Nagasaki Prefectural Shimabara Hospital, 7895 Shimokawajiri, Shimabara, Nagasaki 855-0861 JAPAN

TEL: +81-(0)957-63-1145, FAX: +81-(0)957-63-4864, E-mail: shigetoshi-matsuo@pref.nagasaki.lg.jp

Received December 6, 2005; Accepted April 12, 2006

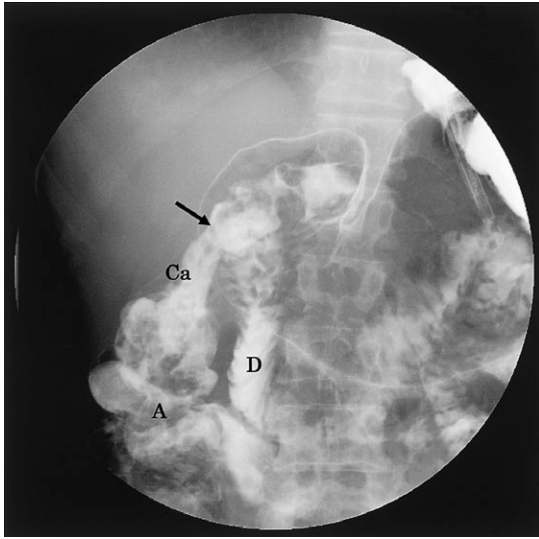


Figure 1. Upper GI series showed an apple-core lesion (Ca) of the ascending colon (A) via a fistula (arrow). D: duodenal second portion.

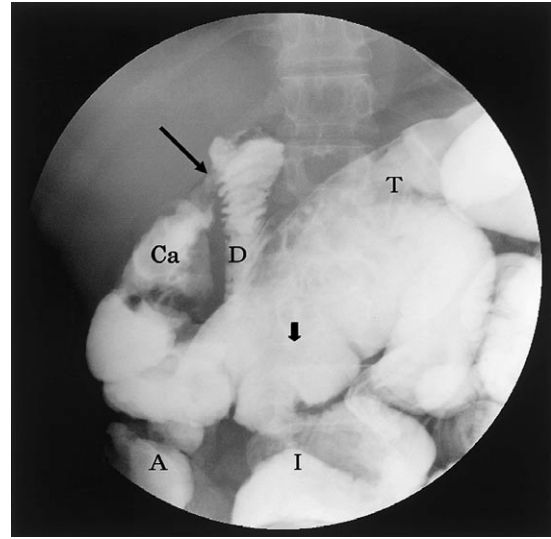


Figure 3. Gastrografin® enema revealed an apple-core lesion (Ca) in the hepatic flexure of the ascending colon with duodenocolic fistula (arrow). Ileo-transversostomy was shown in the midtransverse colon. I: ileum; T: transverse colon; ↓: the site of ileotransversostomy.

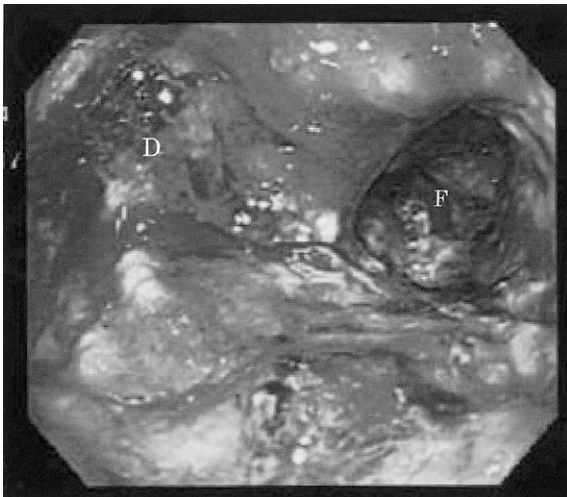


Figure 2. Gastrofiberscopy showed fecal matter in the duodenum (D) and tumor invasion via a fistula (F).

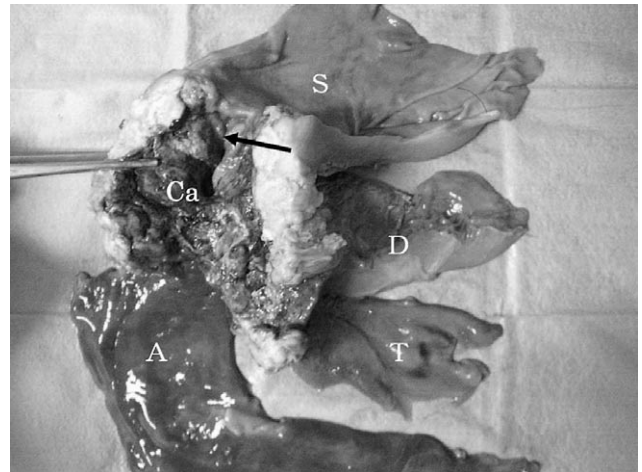


Figure 4. En bloc resected specimens showed colon cancer (Ca) in the hepatic flexure of the ascending colon with duodenocolic fistula (arrow). S: stomach; D: duodenum; T: transverse colon.

and ileo-transversostomy in the mid-transverse colon (Figure 3). Chest and abdominal computed tomography showed no distant metastases. In response to the diagnosis of the ascending colon cancer with duodenocolic fistula in the blind loop, a right hemicolectomy with pancreaticoduodenectomy was performed on September 9, 2004 (Figure 4). Tumors invaded into the gallbladder and the caudate lobe of the liver without peritoneal dissemination. Cholecystectomy and partial resection of the liver were also performed. Histological examination showed a poorly differentiated adenocarcinoma that originated from the ascending colon with invasions into the duodenum, gallbladder and liver. Paracolic nodal metastases were histologically found. Postoperatively, the patient had no recurrence at 14 months after the operation.

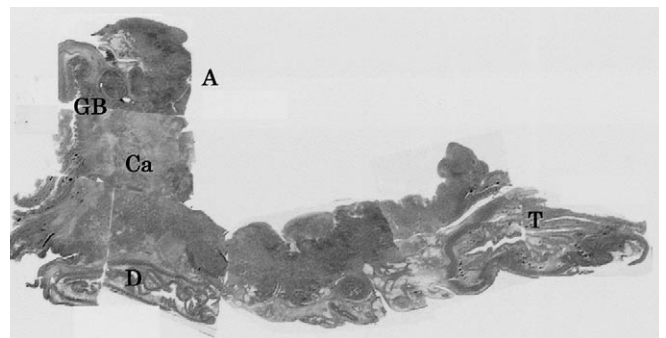


Figure 5. Histological examination showed ascending colon cancer (Ca) with invasions into the duodenum (D) and gallbladder (GB). A: hepatic flexure of the ascending colon.

Discussion

Interestingly, in this case, ascending colon cancer developed in the blind loop and resulted in a duodenocolic fistula. A radical operation would be an en bloc resection, such as RH with PD, for locally advanced right-sided colon cancers. Although questions remain as to whether RH with PD is necessary for locally advanced right-sided colon cancers, Hunter et al.¹ reported that the 5-year survival rate was 55% in standard colectomy for colorectal cancers without adherence to adjacent organs, 61% in en bloc resection for those with adherence to other organs, and 23% in colectomy for those with separation from adherent organs. Similarly, in colon cancers with uninvolved nodes, patients with invasion into adjacent organs (with or without fistula) had an excellent 5-year survival rate compared with those with full-thickness invasion into or through the serosa without adjacent organ invasion.²

RH with PD performed as a two-stage procedure to treat locally advanced colon cancer with duodenocolic fistula was first reported by Linton³ in 1944. The procedure consisted of, first, defunctionalization

of duodenocolic fistula by gastrojejunostomy and ileotransversostomy with a nutritional replacement, and, second, resection of the tumor. Later, a one-stage procedure involving en bloc resection of RH and PD was reviewed by Janes et al.⁴ in 1959. To our knowledge, there have been reported, in the literature in Japanese and English, 26 cases including the present one that have undergone RH with PD for right-sided colon cancer with duodenocolic fistula. The reported cases³⁻²⁶ are listed in Table 1. The first case in Japan underwent RH and consequently needed to undergo PD 2 months later because of duodenal stenosis due to remnant tumors.⁷ This case did not strictly involve the two-stage RH with PD procedure reported by Linton. The male-to-female ratio was 16:10. The age at operation varied from 34 to 73 years with the mean of 59.9 years. Postoperative survival time ranged from 5 months to 12 years and 13 patients survived for over 1 year. Minor complications were seen in 34.6% of all patients, including cardiac failure, jaundice, leakage, abscess and pulmonary embolus. In one patient (3.8%), postoperative mortality was the result. Four papers published between 1994 and 2005 have reviewed the RH with PD procedure for right-sided colon cancers with direct

Table 1. Right hemicolectomy with pancreaticoduodenectomy for right-sided colon cancer with duodenocolic fistulae reported in the literature in Japanese and English

Authors ^a	Year ^b	Clinical features of patients			
		Age ^c	Sex	Morbidity	Prognosis
Linton ³	1944	59	Male	Cardiac failure	Died in 9 months
Linton ³	1944	45	Male	Pancreatic juice discharge	Alive for 18 months
Prohaska et al. ⁵	1956	46	Male	No description	Died in 2.5 years
Janes and Mills ⁴	1959	69	Male	Bile leakage, pulmonary embolism	Alive for 4 years
Gallagher ⁶	1960	53	Male	Leakage	Alive for 32 months
Sone et al. ⁷	1961*	56	Male	None	Alive
Musican and Thompson ⁸	1969	44	Male	Abscess	Alive for 8 months
Vieta et al. ⁹	1974	54	Male	Leakage	Alive for 12 months
Welch and Warshaw ¹⁰	1977	46	Male	None	Alive for 14 years
Kotoura et al. ¹¹	1977*	51	Male	None	Alive for 3 years
Ogawa et al. ¹²	1980*	42	Male	None	Alive for 1 year
Mori et al. ¹³	1981	63	Female	None	Alive
Nakamoto et al. ¹⁴	1982	73	Female	Jaundice	Died in 7 days
Nakamura et al. ¹⁵	1983*	49	Male	None	Alive for 10 months
Tanaka et al. ¹⁶	1985*	63	Male	None	Alive for 5 months
Sasamoto et al. ¹⁷	1985*	69	Female	None	No description
Mizutani et al. ¹⁸	1985*	48	Female	None	No description
Giusto et al. ¹⁹	1986	70	Male	Leakage	Alive for 1 year
Masui et al. ²⁰	1986*	73	Female	None	Alive
Barton et al. ²¹	1987	61	Male	Abscess	Died in 9 months
Ikeda et al. ²²	1987*	73	Female	None	Alive for 20 months
Ikeda et al. ²²	1987*	45	Female	None	Alive for 1 year
Matsumaru et al. ²³	1989*	34	Female	None	Alive
Suzuki et al. ²⁴	1989*	66	Female	None	Alive for 1 year
Izumi et al. ²⁵	1991	34	Female	None	Alive for 20 months
Matsuo et al.	2006	68	Male	None	Alive for 14 months

^aEach superscript numeral refers to the reference number; the present article is by the last authors.

^bYear of publication; the asterisk indicates that the article is written in Japanese.

^cAge at operation in years.

invasion into adjacent organs such as the duodenum, stomach, pancreas head and liver.²⁶⁻²⁹ In these four reviews, there was one operative mortality in 20 cases that underwent RH with PD. This mortality resulted from leakage of the pancreaticojejunostomy and intra-abdominal hemorrhage. Major complications such as anastomotic leakages in hepatico-jejunostomy and ileo-colostomy occurred in 3 cases. Other minor complications involved wound infection, delayed gastric emptying and pneumonia. The longest postoperative survival achieved 88 months,⁶ 41 months,²⁷ and 113 months.²⁸

In conclusion, RH with PD for locally advanced right-sided colon cancers with duodenal invasion can be expected to result in long-term survival, if peritoneal and distant metastases are not present.

References

- Hunter JA, Ryan JA, Schultz P. En bloc resection of colon cancer adherent to other organs. *Am J Surg* 154: 67-71, 1987
- Gardner B, Feldman J, Spivak Y et al. Investigation of factors influencing the prognosis of colon cancer. *Am J Surg* 153: 541-544, 1987
- Linton RR. Two-stage operation for carcinoma of the transverse colon producing duodenocolic fistula. *Arch Surg* 48: 197-207, 1944
- Janes RM, Mills JF. Malignant duodenocolic fistula--report of a case treated successfully by mass resection. *Can J Surg* 3: 91-92, 1959
- Prohaska JV, Nelsen TS, Evans SO. Radical surgery in advanced carcinoma of intra-abdominal organs. *Arch Surg* 73: 671-681, 1956
- Gallagher HW. Extended right hemicolectomy. The treatment of advanced carcinoma of the hepatic flexure and malignant duodenocolic fistula. *Br J Surg* 47: 616-621, 1961
- Sone K, Satou F, Toyoshima J. A case of duodenocolic fistula due to ascending colon cancer. *Medical Journal of Iwate Prefectural Hospital* 1: 39-40, 1961 (in Japanese)
- Musicant ME, Thompson JC. The emerging management of lateral duodenal fistula by pancreaticoduodenectomy. *Surg Gynecol Obstet* 128: 108-114, 1969
- Vieta JO, Blanco R, Valentini GR. Malignant duodenocolic fistulas: Report of two cases, each with one or more other synchronous gastrointestinal cancers. *Dis Colon Rectum* 19: 542-552, 1976
- Welch JP, Warshaw AL. Malignant duodenocolic fistulas. *Am J Surg* 133: 658-661, 1977
- Kotoura Y, Yamamura T, Kusunoki T, Miura J, Ishikawa Y, Ito N. A case of duodeno-colic fistula due to colon cancer. *Hyogo Ikadaigaku Zasshi (Acta Med Hyogo)* 2: 291-297, 1977 (in Japanese with English abstract)
- Ogawa M, Oh S, Mizumoto S, Monden M, Okumura J, Kosaki G. Malignant gastroduodenocolic fistula: A case report. *Geka Chiryō (Surg Ther)* 42: 735-740, 1980 (in Japanese)
- Mori F, Miyamoto M, Torieda M, Morita N, Mohri H. Malignant duodenocolic fistula: A case report. *Jpn J Surg* 11: 50-53, 1981
- Nakamoto K, Nitta N, Tanaka A et al. Malignant duodenocolic fistulae: A report of three cases. *Arch Jpn Chir* 51: 176-185, 1982
- Nakamura S, Koyama W, Izumi N et al. Carcinoma of the colon with duodenocolic fistula and pneumobilia. Report of a case. *Naika (Int Med)* 51: 594-597, 1983 (in Japanese)
- Tanaka S, Arima S, Kinashi M et al. A case report of a transverse colon cancer forming a duodenocolic fistula. *Nippon Daicho-Koumonbyo Gakkai Zasshi (J Jpn Soc Colo-proctol)* 37: 224, 1985 (abstract, in Japanese)
- Sasamoto M, Tanaka M, Kimura Y, Kako N, Koie H, Soejima S. Duodenocolic fistula due to a transverse colon cancer: A case report. *Hirosaki Igaku (Hirosaki Med J)* 37: 1068, 1985 (abstract, in Japanese)
- Mizutani G, Utsunomiya T, Onishi H et al. A duodenocolic fistula due to transverse colon cancer: A case report. *Nippon Shokakibyō Gakkai Zasshi (Jpn J Gastroenterol)* 83: 1270, 1985 (abstract, in Japanese)
- Giusto F, Arzillo G, Lodo N, Falchero F, Gramegna A. Malignant duodenocolic fistula. A case report. *Ital J Surg Sci* 16: 47-49, 1986
- Masui N, Hara M, Ito K et al. A case report of malignant coloduodenal fistula. *Shokaki Naishikyo no Shinpo (Prog Digestive Endoscop)* 28: 321-324, 1986 (in Japanese with English abstract)
- Barton DJ, Walsh TN, Keane T, Duignan JP. Malignant duodenocolic fistula. Report of a case and review of the literature. *Dis Colon Rectum* 30: 636-637, 1987
- Ikeda M, Noto T, Kin D et al. Pancreaticoduodenectomy for malignant duodenocolic fistula and duodenal invasion: A report of three cases. *Nippon Daicho-Koumonbyo Gakkai Zasshi (J Jpn Soc Colo-proctol)* 40: 623, 1987 (abstract, in Japanese)
- Matsumura K, Abe T, Tsuruoka Y et al. A case of carcinoma of the colon associated with a coloduodenal fistula, which was confirmed by endoscopy. *Shokaki Naishikyo no Shinpo (Prog Digestive Endoscop)* 35: 359-362, 1989 (in Japanese with English abstract)
- Suzaki S, Maruyama A, Yano T, Kuroda H, Fujimori K, Ito T. Malignant duodenocolic fistula: A case report. *Chubu Geka Gakkai Sokai Kiroku (Rec Annual Meeting Chubu Surg Soc)* 25: 66, 1989 (abstract, in Japanese)
- Izumi Y, Ueki T, Naritomi G, Akashi Y, Miyoshi A, Fukuda T. Malignant duodenocolic fistula: Report of a case and considerations for operative management. *Surg Today* 23: 920-925, 1993
- Curley SA, Evans DB, Ames FC. Resection for cure of carcinoma of the colon directly invading the duodenum or pancreatic head. *J Am Coll Surg* 179: 587-592, 1994
- Kama NA, Reis E, Doganay M, Gozalan U, Yasti C. Radical surgery of colon cancers directly invading the duodenum, pancreas and liver. *Hepatogastroenterology* 48: 114-117, 2001
- Berrosi F, Celis J, Ruiz E, Payet E. En bloc pancreaticoduodenectomy for right colon cancer invading adjacent organ. *J Surg Oncol* 79: 194-198, 2002
- Kapoor S, Das B, Pal S, Sahni P, Chattopadhyay TK. En bloc resection of right-sided colonic adenocarcinoma with adjacent organ invasion. *Int J Colorectal Dis.* Epub. June 7, 2005