Acta Med. Nagasaki 52: 63−66

Case Report

Laparoscopic Marsupialization Surgery for Large Epidermoid Cyst of Spleen in a Child

Keisuke CHIHAYA,[1] Tomayoshi HAYASHI,[1] Takehiro MISHIMA,[2] Ichiro ISOMOTO,[3] Kyoko MOCHIZUKI,[2] Takayuki HAMADA,[2] Kuniko ABE,[1] Naoe KINOSHITA,[1] Aki TOMIHARA,[1] Takashi KANEMATSU[2]

[1] Department of Pathology, Nagasaki University Hospital, Nagasaki, Japan

[2] Department of Transplantation and Digestive Surgery, Nagasaki University Graduate School of Biomedical Sciences, Nagasaki, Japan

[3] Department of Radiological Science, Nagasaki University Graduate School of Biomedical Sciences, Nagasaki, Japan

Epidermoid cysts of the spleen are relatively rare. Usually occurring in children and young adults, they are most often asymptomatic, though large cysts can cause symptoms. A 9-year-old Japanese girl was found to have proteinuria and microscopic hematuria by routine school urine testing. She was incidentally found to have an abdominal mass. On abdominal magnetic resonance imaging, a cyst measuring 12.7 cm × 12.6 cm × 14.7 cm was found in her left upper abdomen. The cyst was too large for nonoperative treatment. Given the patient's age, concerns over the risk of septicemia after splenectomy led to laparoscopic marsupialization surgery. On pathology, the lumen of the cyst was found to be lined with stratified squamous epithelium. A small area of epithelium was positive for Alcian blue and HBME-1, indicating its mesothelial origin. Markers that were present in a high concentration, such as CA125 in the serum and cystic fluid, and CEA in the cystic fluid, stained positively in the epithelium. This supported the idea that these markers were produced by the lining epithelium. Six months since the operation, the cyst has gradually increased in size to 11.9 cm × 8 cm. However, since the cyst is asymptomatic, the patient is under outpatient-follow-up without further treatment.

ACTA MEDICA NAGASAKIENSIA 52: 63−66, 2007

Keywords: Splenic cyst; Epidermoid cyst; Mesothelial origin; Marsupialization; Spleen; Laparoscopic surgery

Introduction

Several types of cysts can occur in the spleen. Basically, splenic cysts are classified based on their etiology as parasitic cysts or nonparasitic cysts.[1] Nonparasitic cysts are further classified as true cysts or false cysts based on the presence of lining epithelium.[1] Epidermoid cysts, which are the dominant type of true cysts, form benign unilocular cysts in the spleen. They are relatively rare and about 1,000 cases have been reported.[2] Splenic epidermoid cysts usually occur in children and young adults, and are most often asymptomatic, though large cysts can cause symptoms.[3-5] Rarely, the cysts can rupture or be complicated by secondary bacterial infection.[6] Histologically, the cyst wall is variably fibrous, and it is usually lined by stratified squamous epithelium that may show keratinization and usually lacks rete ridges and skin appendages.[6] We report an epidermoid cyst of the spleen in a 9-year-old girl with a conspicuous abdominal mass.

Case report

A 9-year-old Japanese girl was found to have proteinuria and microscopic hematuria by routine school urinalysis. At that time, an abdominal mass was found in her left upper abdomen. On abdominal magnetic resonance imaging (MRI), a cyst measuring 12.7 cm × 12.6 cm × 14.7 cm was found. The inside of the cyst appeared uniform, and the cyst was suspected to be filled with fluid or blood. Radiologically, the possible origin of the mass included the spleen, the left kidney, or the lateral segment of the liver. Abdominal MRI showed compressed splenic parenchyma, and the lesion was diag-

Address correspondence: Tomayoshi Hayashi, M.D., Ph.D., Department of Pathology, Nagasaki University Hospital, 1-7-1 Sakamoto, Nagasaki 852-8501 JAPAN
TEL: +81-(0)95-849-7562, FAX: +81-(0)95-849-7564, E-mail: toma@nagasaki-u.ac.jp

Received January 19, 2007; Accepted March 20, 2007

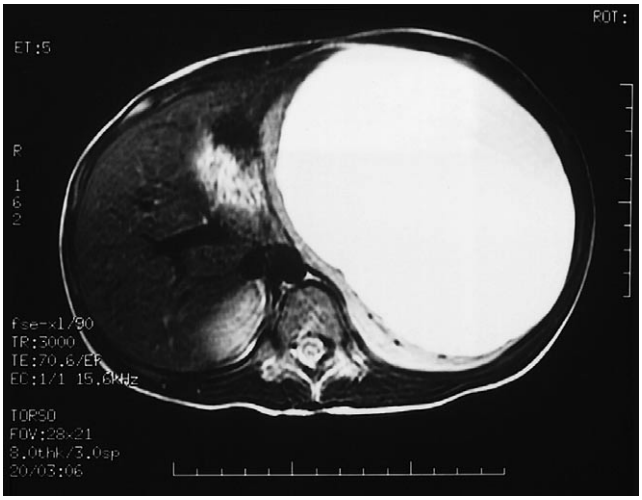

Figure 1. Abdominal MRI (T2WI). A cyst measuring 14.5 cm × 10.5 cm is evident in the left upper abdomen. The cyst compresses the parenchyma of the spleen, indicating its splenic origin. The cyst is unilocular with no solid areas.

nosed as splenic cyst (Figure 1). The border between the left kidney and the lateral segment of the liver was preserved. Preoperative serum levels were as follows: CEA—1.7 ng/mL, CA125—30.3 U/mL, CA19-9—<6 U/mL. Cystic fluid removed by needle puncture at operation revealed 740 ng/mL of CEA and 14,270 U/mL of CA125.

The operative options included splenectomy, partial splenectomy, and marsupialization. Since massive bleeding was considered to be a risk of partial splenectomy, and since the patient was considered to be too young for splenectomy, we chose a procedure of laparoscopic marsupialization.

At operation, most of the cyst surface was covered by the parenchyma of the spleen. A total of 1.3 L of fluid was removed by needle puncture. A small area of the cyst wall was not covered by the spleen. The intraoperative histological diagnosis of the non-covered cyst wall was consistent with epithelial cyst without malignancy. We cut out the area not covered by the spleen, and filled up the cystic wall with greater omentum and fixed the omentum to the cystic wall by seaming them with absorbable thread at 4 spots close to the edge of cystic wall.

After the operation, a lot of fluid was discharged through Penrose drain left in the cyst. Gradually, the amount of drainage decreased, the Penrose drain was removed 4 days after the operation, and the abdominal distension disappeared. On abdominal ultrasonography, a cyst measuring 2 cm × 2 cm with fluid was found in the surface area of the spleen. The postoperative course was uneventful and she was discharged from the hospital 8 days after the operation with the arrangement of outpatient follow-up.

Histologically, the cystic wall consisted of fibrous connective tissue with little elastic tissue. Bleeding, hyalinization, infiltration of lymphocytes and plasma cells, and calcification were noted. The lumen of the cyst was lined by stratified squamous epithelium. The lining epithelium was partially keratinized and was lost in some

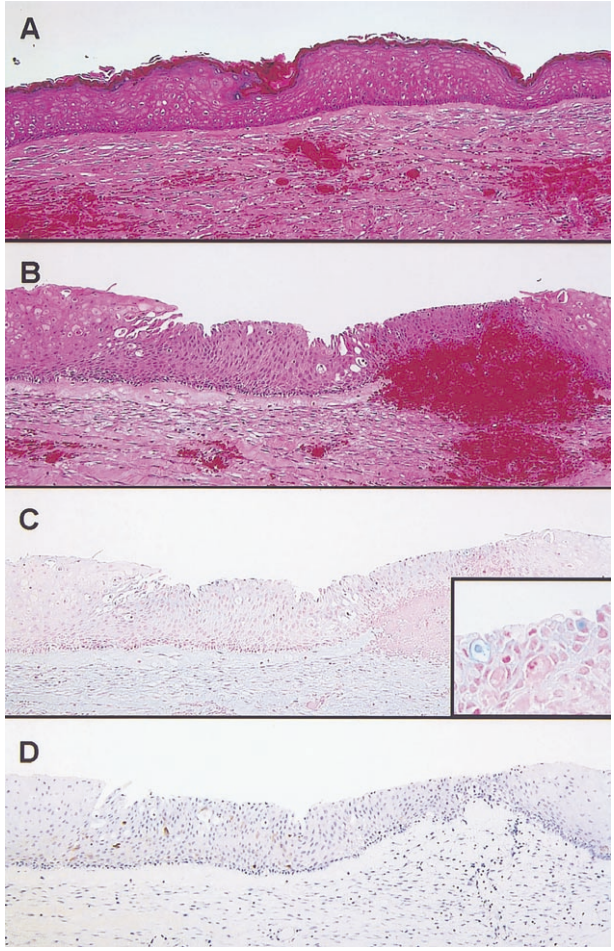

Figure 2. Histopathologic findings of the cyst wall. **A.** The cyst wall consists of fibrous connective tissue and is lined by keratinized squamous epithelium. The epithelium is flat without either rete ridges or skin appendages. The cyst wall shows hemorrhage (HE, ×100). **B.** In a small area, the cells are arranged perpendicular to the surface; these cells are smaller, with a gland-like space (×100). **C.** In the same area seen in the panel B, the lumen is positive for Alcian blue (×100); the inset presents the high magnification of intracytoplasmic Alcian blue-positive material (×400). **D.** The same area seen in the panel B has scattered positive reaction for HBME-1 (×100).

area (Figure 2 A). The epithelium was flat without either rete ridges or skin appendages. The epithelial cells were bland-looking with no malignant potential. A small area of gland-like cells with perpendicular arrangement of stratification was evident (Figure 2 B). In that area, Alcian blue-positive material was present in the cytoplasmic lumen (Figure 2 C), and on immunohistochemistry, there were scattered cells positive for HBME-1, a mesothelial marker (Figure 2 D). The squamous epithelium also showed positive reactions for EMA, keratin, CK7, CA125, CA19-9, and CEA (Figure 3), while it was negative for CK20, CK5/6, and calretinin (Table 1).

The cystic fluid obtained during the operation, containing benign squamous epithelium, squamous epithelium without nuclei, and histiocytes without atypical cells, was cytologically diagnosed as CLASS 1 negative.

Six months have passed since the operation, and the cyst is

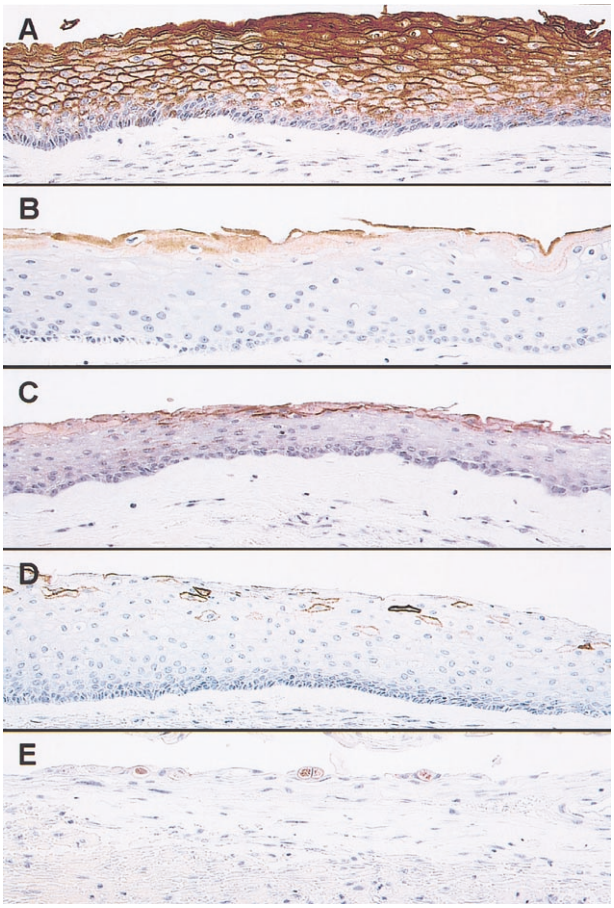

Figure 3. Immunohistochemical staining. The epithelium is diffusely positive for EMA (**A**); the surface layer is positive for CK7 (**B**) and CA125 (**C**); the cell membrane of scattered surface layer cells is positive for CA19-9 (**D**); and there is very focal positivity for CEA in the surface cells (**E**). The magnification is (×200) in all panels.

Table 1. Immunohistochemical characteristics of lining epithelium of the cyst with the level of respective antibodies in cystic fluid and serum

Antibody	Reaction	Cystic fluid[a]	Serum[a]
CA125	+, diffuse, surface layer	14,270 U/mL	30.3 U/mL
CA19-9	+, focal, surface layer	NA	<6 U/mL
CEA	+, very focal	740 ng/mL	1.7 ng/mL
EMA	+, diffuse	NA	NA
Keratin	+, diffuse	NA	NA
CK7	+, surface layer	NA	NA
CK20	–	NA	NA
HBME-1	+, focal	NA	NA
CK5/6	–	NA	NA
Calretinin	–	NA	NA

[a]NA=Not available.

gradually growing. On ultrasound, a fluid-filled mass measuring 11.9 cm × 8 cm has been noted. Since there is no abdominal distension and the patient is asymptomatic, no treatment is arranged. We are planning a curative operation when the symptoms such as abdominal distension appear.

Discussion

Epidermoid cysts of the spleen are relatively rare and account for 10% of nonparasitic and benign cysts of spleen.[7] Epidermoid cysts occur in children and young adults, affecting both genders equally.[3] The cysts are usually asymptomatic, but can cause mild abdominal pain.[4,5] Cysts are often discovered incidentally during imaging studies or at autopsy.[3-5] Although most cysts are solitary, some may be multiple.[8] The cystic fluid can be thin and serous, but cysts with turbid and viscoid fluid have been reported.[2] In our case, the cystic fluid was bloody and thin.

A previous report[3] presented 19 cases of epidermoid cysts ranging from 0.5 to 24 cm in diameter, and only patients with cysts exceeding 8 cm in diameter presented clinical symptoms; there were 14 such patients, and 64% of them had abdominal mass and 78% of them had abdominal pain. In the present case, the cyst measured 12.7 cm × 12.6 cm × 14.7 cm, and the patient had a clinically identifiable abdominal mass. Our case also had proteinuria, which may have been caused by compression of the kidney by the huge cyst, or the patient may have had glomerulonephropathy. We have not checked for proteinuria since the operation.

The origin of epithelial cysts of spleen is controversial. One hypothesis is that they originate from the embryonic inclusion of epithelial tissue from adjacent structures, while another hypothesis is that they originate from the embryonic inclusion of mesothelial lining with subsequent squamous metaplasia.[9-11] In a study using scanning and transmission electron microscopy, some ultrastructural features of mesothelial cells were observed in the lining cells,[9] leading to the conclusion that the lining epithelium of epidermoid cyst is not a true squamous epithelium but rather the result of squamous metaplasia of the mesothelium.[9,10] Our finding of an area with different histology showing intracytoplasmic positivity for Alcian blue and HBME-1 supports this view.

In some reports, serum levels of CA125, CEA, and CA19-9 were elevated in patients with epidermoid cysts.[12-14] These markers were found to return to normal after splenectomy, and the luminal epithelium was found to stain positively for CEA and CA19-9.[12,13,15] Some investigators have suggested that this shows that these markers are products of the squamous epithelium which have leaked into the bloodstream, presumably as a result of trauma or increasing pressure within the cyst.[12,13,15] In our case, the markers being of high concentration in the serum and/or cystic fluid, e.g. CA125 and CEA, stained positively in the epithelium; thus, these markers appear to be produced by the lining epithelium. The epithelium also showed positive reaction for CA19-9, which has been reported to be increased in other cases.[13,15]

With regard to the treatment strategy, nonoperative treatment is recommended for small cysts measuring up to 5 cm in diameter if

the cysts are totally asymptomatic with imaging characteristics of typical nonparasitic splenic cysts.[2] In the case of large cysts, the surgical treatment of choice has been total splenectomy; today, however, there are many other treatment options, such as percutaneous drainage, marsupialization, enucleation, partial splenectomy, and total splenectomy with autotransplantation of splenic tissue.[5] In our case, the cyst was too large to allow conservative treatment. Although we initially considered that radical treatment such as splenectomy or partial splenectomy would be preferable, we decided, considering patient's age, to preserve the spleen and chose laparoscopic marsupialization. In our case, however, enlargement of the cyst has already recurred, and we have chosen to continue outpatient follow-up and to observe the patient as long as she remains asymptomatic. If the cyst again becomes too large, we will then choose one among several options: enucleation, partial splenectomy, total splenectomy, and draining cystic fluid.

References

1. Fowler RH. Nonparasitic benign cystic tumors of the spleen. *Int Abstr Surg* 96: 209-227, 1953
2. Di Carlo I, Fasone MA, Toro A. Epidermoid cyst of the spleen in the laparoscopic era. *Dig Surg* 22: 53-54, 2005
3. Tsakayannis DE, Mitchell K, Kozakewich HPW, Shamberger RC. Splenic preservation in the management of splenic epidermoid cysts in children. *J Pediatr Surg* 30: 1468-1470, 1995
4. Cowles RA, Yahanda AM. Epidermoid cyst of the spleen. *Am J Surg* 180: 227, 2000
5. Balzan SMP, Riedner CE, Santos LM, Pazzinatto MC, Fontes PR. Posttraumatic splenic cysts and partial splenectomy: report of a case. *Surg Today* 31: 262-265, 2001
6. Warnke RA, Weiss LM, Chan JKC, Cleary ML, Dorfman RF. Splenic cysts. In *Atlas of Tumor Pathology 3rd Series Fascicle 14, Tumors of the Lymph Nodes and Spleen* (Warnke RA, Weiss LM, Chan, JKC et al eds.; Armed Forces Institute of Pathology, Washington, D.C.) pp. 506-508, 1994
7. Golinsky D, Freud E, Steinberg R, Zer M. Vertical partial splenectomy for epidermoid cyst. *J Pediatr Surg* 30: 1704-1705, 1995
8. Bostick WL, Lucia SP. Nonparasitic, noncancerous cystic tumors of the spleen. *Arch Pathol* 47: 215-222, 1949
9. Burrig KF. Epithelial (true) splenic cysts. Pathogenesis of the mesothelial and so-called epidermoid cyst of the spleen. *Am J Surg Pathol* 12: 275-281, 1988
10. Ough YD, Nash HR, Wood DA. Mesothelial cysts of the spleen with squamous metaplasia. *Am J Clin Pathol* 76: 666-669, 1981
11. Iwanaka T, Nakanishi H, Tsuchida Y, Oka T, Honna T, Shimizu K. Familial multiple mesothelial cyst of the spleen. *J Pediatr Surg* 30: 1743-1745, 1995
12. Arda IS, Tüzün M, Hicsönmez A. Epidermoid cyst of the spleen with elevated levels of CA125 and carcino-embryonic antigen. *Eur J Pediatr* 164: 108, 2005
13. Higaki K, Jimi A, Watanabe J, Kusaba A, Kojiro M. Epidermoid cyst of the spleen with CA19-9 or carcinoembryonic antigen productions: report of three cases. *Am J Surg Pathol* 22: 704-708, 1998
14. Yokomizo H, Hifumi M, Yamane T et al. Epidermoid cyst of an accessory spleen at the pancreatic tail: diagnostic value of MRI. *Abdom Imaging* 27: 557-559, 2002
15. Galizia G, Lieto E, Ferraraccio F et al. A true splenic cyst producing carbohydrate antigen 19-9 and cancer antigens 50 and 125, but not interleukin 10. *Dig Surg* 20: 71-74, 2003