

## Original article

## Triple-drug therapy to prevent pancreatic fistula after pancreatectomy in a rat model



Naoki Kuroshima, Takayuki Tanaka, Tamotsu Kuroki, Amane Kitasato, Tomohiko Adachi, Shinichiro Ono, Hajime Matsushima, Takanori Hirayama, Akihiko Soyama, Masaaki Hidaka, Mitsuhsa Takatsuki, Susumu Eguchi\*

Department of Surgery, Nagasaki University Graduate School of Biomedical Sciences, Nagasaki, Japan

## ARTICLE INFO

## Article history:

Received 23 February 2016

Received in revised form

8 May 2016

Accepted 21 June 2016

Available online 24 June 2016

## Keywords:

Pancreatic fistula

Somatostatin analogue

Gabexate mesilate

Antibiotic

Complication

## ABSTRACT

**Background:** Pancreatic fistula (PF) is one of post-operative complications in pancreatic surgery, but there is no consensus about the optimal treatment for PF. Our group has established a rat model of PF, and we conducted the present investigation to determine the efficacy of the triple-drug therapy (somatostatin analogue, gabexate mesilate, and imipenem/cilastatin) against PF using our rat model.

**Methods:** In the PF rat model, the triple-drug therapy was administered to the treated (T) group ( $n = 4$ ), and we compared the results with those of a control (C) group ( $n = 4$ ). The rats were sacrificed on postoperative day 3 (POD 3) and the levels of amylase and lipase in serum and ascites were measured. The intra-abdominal adhesion was scored. Each pancreas was evaluated pathologically, and inflammation was scored.

**Results:** The ascitic amylase levels on POD 3 were 1982 (1738–2249) IU/L in the C group and significantly lower at 136 (101–198) IU/L in the T group ( $p = 0.02$ ). The ascitic lipase levels on POD 3 were 406 (265–478) U/L in the C group and significantly lower at 13 (7–17) U/L in the T group ( $p = 0.02$ ). The intra-abdominal adhesion score on POD 3 was 2 (1–2) in the C group and significantly lower at 0 (0–1) in the T group ( $p = 0.02$ ). The histological evaluation showed that the average of pancreatic inflammatory score was 8.5 (8–9) in the C group and significantly milder at 5 (5–7) in the T group ( $p = 0.01$ ).

**Conclusion:** Our findings suggest that the triple-drug therapy could be useful as a treatment for PF in clinical settings.

© 2016 IAP and EPC. Published by Elsevier B.V. All rights reserved.

## 1. Introduction

Pancreatic surgery has become safer due to improvements in surgical techniques and devices in recent years [1–5], but the frequency of complications after pancreatic surgery remains high at 30%–50% [6]. Pancreatic fistula (PF) is one of the most serious postoperative complications in pancreatic surgery because of its character. A PF can melt adipose tissues and induce abscess formations and a pseudoaneurysm that could be life-threatening when it ruptures [7–10]. Controlling a PF would thus be the most important aspect of peri-operative care for patients who undergo a pancreatic resection. However, there is no guideline or consensus

about the treatment of PF, and there are many types of treatments for this complication.

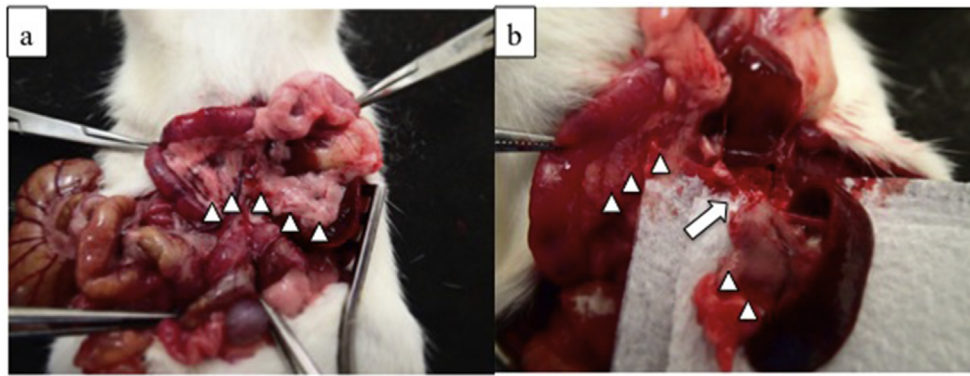
Somatostatin analogue is a drug that binds to the somatostatin receptor and suppress the release of hormones by organ [11]. Some studies have shown that somatostatin analogue suppresses pancreas secretions, and the studies' authors suggested that these medications are effective against PF [12–14], but other studies obtained negative results about the efficacy of these drugs for PF [15–17]. The efficacy of somatostatin analogues for PF thus remains controversial.

Gabexate mesilate is a protease inhibitor that controls trypsin activation, which suppresses pancreatic self-digestion and necrosis. It is widely used to treat acute pancreatitis in Japan. There are some descriptions about this drug in the Japan Guidelines for the Management of Acute Pancreatitis [18], but it concludes that the efficacy of this drug is not clear and more RCTs are needed.

Imipenem/cilastatin is known as an antibiotic that has a

\* Corresponding author. Department of Surgery, Nagasaki University Graduate School of Biomedical Sciences, 1-7-1 Sakamoto, Nagasaki City, 852-8501, Japan.

E-mail address: [sueguchi@nagasaki-u.ac.jp](mailto:sueguchi@nagasaki-u.ac.jp) (S. Eguchi).



**Fig. 1.** The procedure for making PF rat model. a) The pancreas was unfolded (indicated by triangles). The splenic vein was identified, which ran with splenic duct. b) Pancreas was transected preserving the splenic vessels (indicated by arrow).

sufficient tissue penetration to pancreas. There are some descriptions of reference between use of prophylactic antibiotics and reduction of infectious pancreatic complications in above-cited guideline, but it also concludes that more RCTs are needed [18].

Based on the studies described above, in our department we usually use these three drugs (somatostatin analogue Octreotide, gabexate mesilate, and imipenem/cilastatin) simultaneously for patients who are at high risk of the development of a PF. We have reported the efficacy of this triple-drug therapy in a clinical setting [19]. Although this pharmacological treatment for PF has been effective in our experience, exactly how these drugs affect PF is unclear.

Our group has established a PF model in rats [20]. The aim of the present study was to determine the efficacy of the triple-drug therapy against PF using the rat model.

## 2. Methods

### 2.1. Animals

Eight-week-old male Fisher 344 rats weighing 250–300 g (CLEA Japan, Tokyo) were used. All rats were housed in plastic cages with standard feed and water at the Laboratory Animal Center for Biochemical Research at the Nagasaki University Graduate School of Biomedical Sciences. All animal protocols were approved by the Animal Experimentation Committee of Nagasaki University.

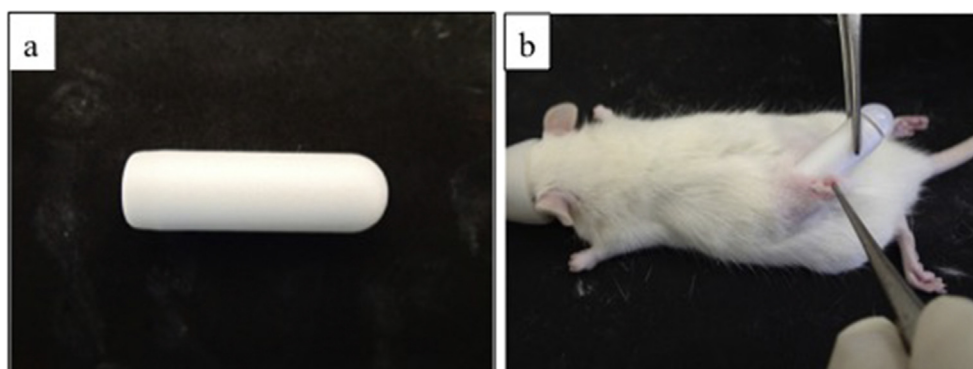
### 2.2. Making the PF rat model

The PF rat model was created as described [20]. In brief, after a

laparotomy was performed, pancreas was unfolded (Fig. 1a). The rat pancreatic duct consists of four smaller duct; common duct, gastric duct, duodenal duct, and splenic duct. To transect splenic duct induce PF model in rats without removing any pancreas lobe [20]. Pancreas which included splenic duct was transected along the portal vein to preserve the splenic vessels (Fig. 1b). After the pancreas transection, the abdomen and skin were closed by suturing with 3–0 silk. We divided the rats into two groups: the triple-drug therapy (T) group (n = 4) and the control (C) group (n = 4). All rats of both groups were sacrificed on postoperative day (POD) 3.

### 2.3. The triple-drug therapy

We medicated rats with using Osmotic Pumps (model 2ML1, Alzet, Cupertino, CA, USA). It is a small pump that can be used for the continuous dosing of unrestrained laboratory animals. The pump filled with a solution of drugs can release drugs continuously in a subcutaneous site for one week. The dosage of somatostatin analogue (Octreotide), gabexate mesilate, and antibiotics (Imipenem/cilastatin) used in clinical settings are 300  $\mu\text{g}/\text{day}$ , 600  $\text{mg}/\text{day}$ , and 1000  $\text{mg}/\text{day}$  respectively. In this study we medicated each rat with 5  $\mu\text{g}/\text{kg}/\text{day}$  of somatostatin analogue, 10  $\text{mg}/\text{kg}/\text{day}$  of gabexate mesilate, and 16.6  $\text{mg}/\text{kg}/\text{day}$  of antibiotics respectively. These three drugs were dissolved in saline and injected into the pump. T-group rats underwent the above-described PF operation first, and then we made an incision on the rats' back and implanted the pumps into the subcutaneous space (Fig. 2). The incision was sutured and closed with 3–0 silk. For the C group, we performed the PF operation first, and then simply made the incision and closed



**Fig. 2.** The procedure for implanting pumps. a) Osmotic Pumps (model 2ML1, Alzet, Cupertino, CA, USA) filled with three drugs. b) Implanting pumps in the subcutaneous site.

**Table 1**

Serum and ascitic levels of amylase and lipase in PF rat model with or without triple drug treatment.

Parameter	The day after operation	C group (n = 4)	T group (n = 4)	p value
Serum amylase (IU/l)	0	548 (536–554)	587 (533–609)	0.56
	3	1010 (930–1149)	617 (604–658)	0.02
Serum lipase (U/l)	0	6 (5–8)	6 (6–7)	0.74
	3	8.5 (6–24)	6 (5–10)	0.24
Ascitic amylase (IU/l)	0	14.5 (7–20)	13.5 (8–21)	0.77
	3	1982 (1738–2240)	136 (101–198)	0.02
Ascitic lipase (U/l)	0	3.5 (3–5)	4 (2–5)	0.88
	3	406 (265–478)	13 (7–17)	0.02

it on the rats' back without implanting the pumps. We extirpated and weighed the pumps on POD 3 to confirm that they equally eluted the solutions in each rat.

#### 2.4. Evaluation of the serum amylase and lipase levels

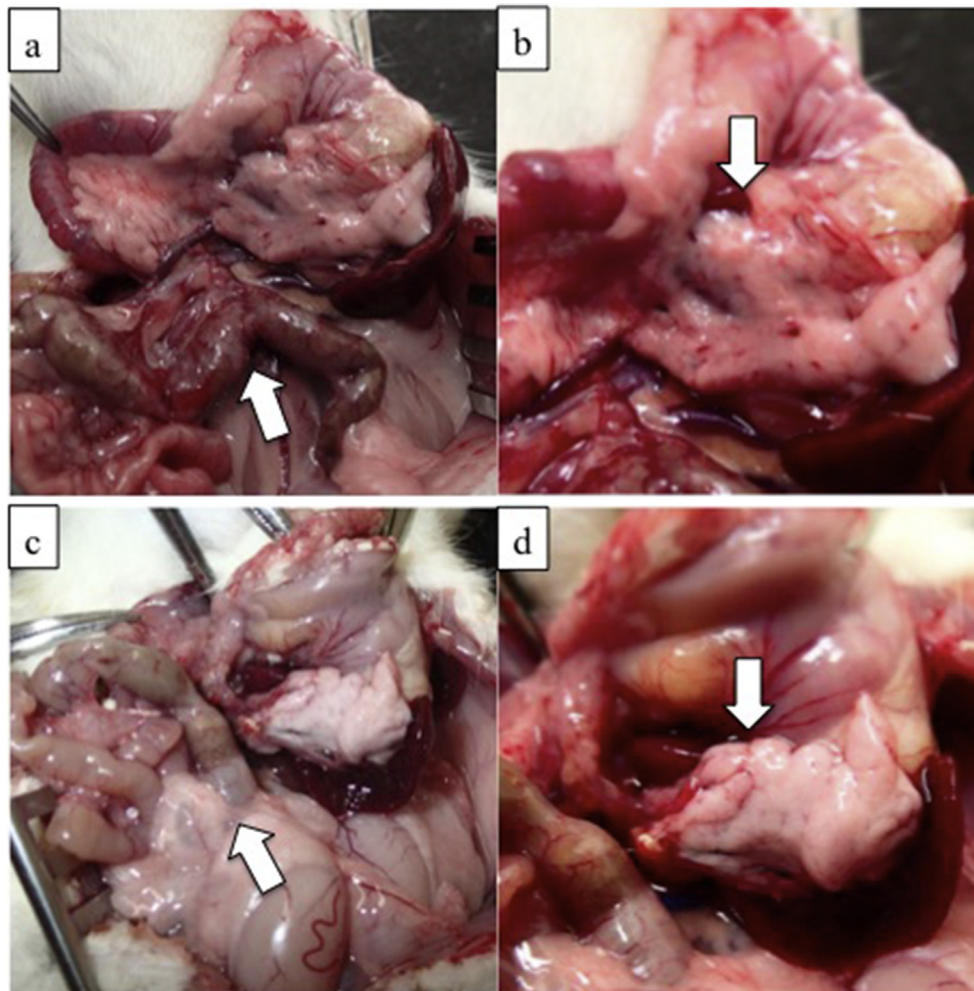
Blood samples were collected from each rats' right femoral vein on the operation day and on POD 3. After centrifugation the samples, the serums were collected, and the serum amylase and lipase levels were measured. We asked these measurements to an outsourcing to avoid the simple error.

#### 2.5. Evaluation of the ascitic amylase and lipase levels

Ascites samples were collected on the operation day and on POD 3. Immediately after the laparotomy was completed, the rats' abdominal cavity was irrigated with 5 ml of saline. After ascites samples were centrifuged, the amylase and lipase levels of the supernatant were measured.

#### 2.6. Evaluation of intra-abdominal adhesion

On POD 3, the intra-abdominal adhesion between the stomach,



**Fig. 3.** Macrofindings in each group. The rats were sacrificed on POD 3. It shows the intra-abdominal view on POD 3. a),b): C group. a) Severe inflammation was observed in the abdomen (indicated by arrow). b) The pancreas melted (indicated by arrow). Moderate adhesion to surrounding organs was observed. c),d): T group. c) Less inflammation was observed (indicated by arrow). d) The pancreas kept its shape (indicated by arrow). Slight adhesion was observed.

**Table 2**  
Intra-abdominal adhesion score and pancreatic inflammatory score in each group.

	C group (n = 4)	T group (n = 4)	p value
Adhesion score	2 (1–2)	0 (0–1)	0.02
Pancreatic inflammatory score	8.5 (8–9)	5 (5–7)	0.01

spleen, and pancreas of each rat was evaluated. It was scored by the degree of difficulty of adhesion dissection as follows: 0 = no adhesion; 1 = adhesion that could be separated with blunt dissection; 2 = adhesion that could be separated by sharp dissection; 3 = adhesion that could not be separated. The median values of each group were compared.

#### 2.7. Evaluation of histological findings of the pancreas

To evaluate the inflammation and histological changes of pancreas parenchyma due to PF, the rats were sacrificed and the pancreas was eviscerated on POD 3. The pancreas was formalin-fixed and stained with hematoxylin-eosin. The histological grading of the pancreas was performed as described [21].

Three pancreas sections from each rat were scored using the grades 0–4, and the three sections' scores were summed: grade 0 = no inflammation was present or <2 small foci monocular cells were present with no disruption of the architecture; grade 1 = <5% neutrophilic or lymphoplasmacytic inflammation; grade 2 = 5–50% neutrophilic or lymphoplasmacytic inflammation; grade 3 = >50% neutrophilic or lymphoplasmacytic inflammation; and grade 4 = necrosis of pancreatic tissue or peri-pancreatic necrosis/steatitis. The median values of each group were compared.

### 3. Results

The amylase and lipase levels in the rats' serum and ascites are shown in Table 1. The serum amylase levels on POD 3 were 1010 (930–1149) IU/L in the C group and significantly lower at 617 (604–658) IU/L in the T group ( $p = 0.02$ ). There was no significant difference between the serum lipase levels of the two groups.

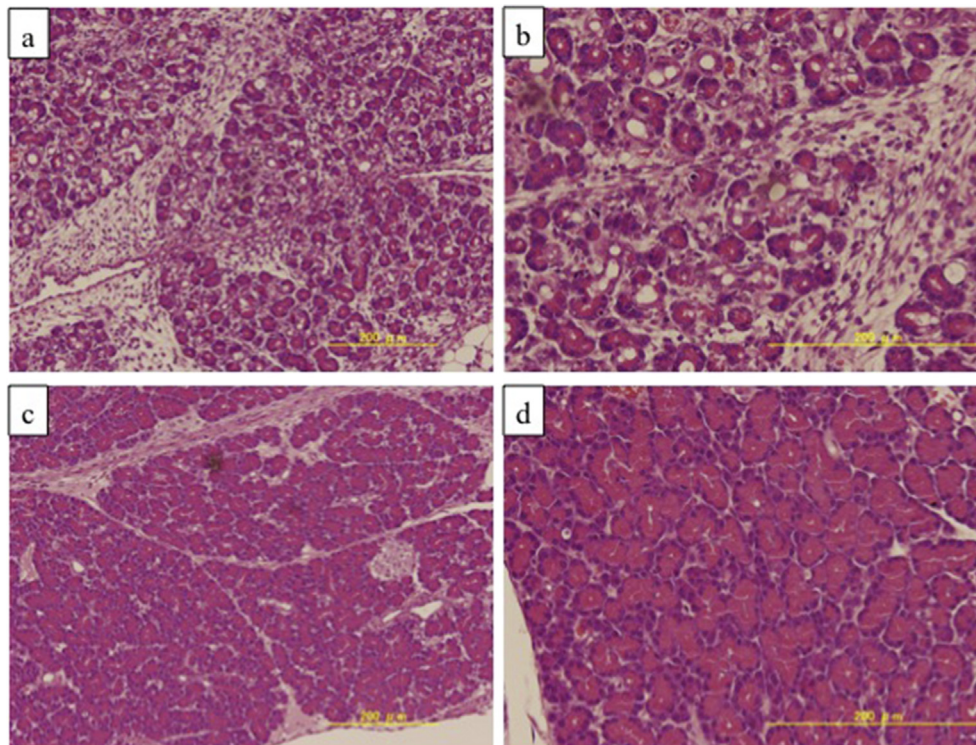
The ascitic amylase levels on POD 3 were 1982 (1738–2240) IU/L in the C group and significantly lower at 136 (101–198) IU/L in the T group ( $p = 0.02$ ). The ascitic lipase levels on POD 3 were 406 (265–478) U/L in the C group and significantly lower at 13 (7–17) U/L in the T group ( $p = 0.02$ ).

The intra-abdominal adhesion results are shown in Fig. 3 and Table 2. On POD 3, one rat in the C group scored 1 and the other three rats scored 2. In the T group, three rats scored 0 and one rat scored 1. The adhesions in the T group were significantly milder than those in the C group ( $p = 0.02$ ).

The histological results are shown in Fig. 4 and Table 2. In the C group, there were some abscesses in the pancreas. In the T group, the inflammatory cell invasions were mild and no abscess was observed. The median value of the pancreatic inflammatory score was 8.5 (8–9) in the C group and 5 (5–7) in the T group. The pancreatic inflammation in the T group was significantly milder than that in the C group ( $p = 0.01$ ).

### 4. Discussion

We chose the three drugs (somatostatin analogue Octreotide, gabexate mesilate, and imipenem/cilastatin) to prevent pancreatic fistula. In the present investigation, there was a significant difference in the amylase and lipase levels of the ascites on POD 3 between the control group and the group treated with the three drugs, there was less intra-abdominal adhesion in the treated



**Fig. 4.** Histological findings in each group. a),b): Pancreas of the C group (POD 3). Many inflammatory cells invaded and destroyed pancreatic glands. c),d): Pancreas of the T group (POD 3). Some inflammatory cells were observed, but the shapes of pancreatic glands were almost unchanged.

group, and there was a lesser pancreatic inflammatory response.

The efficacy of somatostatin analogues for PF remains controversial in studies. A recent report indicated these studies' findings conflict because the studies were performed before 2005, when there was no consistent definition of pancreatic fistula [22]. That report also pointed out that somatostatin analogues have short half-lives *in vivo*, and that this might have affected the various studies' results. We had administered somatostatin analogue with a continuous dosing pump, and the continuous dosing might have extended the short half-life of somatostatin analogue, leading to our findings. These results suggest that a continuous dosing of somatostatin analogue may suppress pancreatic secretions and the development of PF.

Gabexate mesilate is widely used to treat acute pancreatitis in Japan for preventing pancreas self-digestion and necrosis, but the efficacy of this drug is still unclear [18]. In this study we evaluated the efficacy of the triple-drug therapy by performing a pathological examination. Although much destruction of the pancreas glands' structure was observed in the C group, the shapes of the glands were almost unchanged in the T group. This result may indicate that gabexate mesilate contributed to the prevention of the destruction and necrosis of the pancreas.

There were also no abscesses in the pancreas of the T-group rats, whereas some abscesses were observed in the C group. We suspect that this result is due to the effect of the antibiotic imipenem/cilastatin.

There are some limitations of this study. First, the number of rat in this study was small. Second, we medicated rats with continuous pumps implanted in the subcutaneous site. However, in clinical settings, these three drugs are administered to the patients in intravenous drip infusion. The serum levels of the drugs should have been measured in this study.

In conclusion, we evaluated the efficacy of a triple-drug therapy for preventing pancreatic fistulas, using a rat PF model. The treated rats showed lower ascitic amylase and lipase levels, less intra-abdominal adhesion, and a lesser pancreatic inflammatory response. Our results suggest that the triple-drug treatment is effective against PF, and that this could be one of the treatments for PF in clinical settings.

## References

- [1] Kuroki T, Tajima Y, Kanematsu T. Surgical management for the prevention of pancreatic fistula following distal pancreatectomy. *J Hepatobiliary Pancreat Surg* 2005;12:283–5.
- [2] Misawa T, Shiba H, Usuba T, Nojiri T, Uwagawa T, Ishida Y. Safe and quick distal pancreatectomy using a staggered six-row stapler. *Am J Surg* 2008;195:115–8.
- [3] Knaebel HP, Diener MK, Wente MN, Büchler MW, Seiler CM. Systemic review and meta-analysis of technique for closure of the pancreatic remnant after distal pancreatectomy. *Br J Surg* 2005;92:539–46.
- [4] Suc B, Msika S, Fingerhut A, Fourtanier G, Hay JM, Holmières F. Temporary fibrin glue occlusion of the main pancreatic duct in the prevention of intra-abdominal complications after pancreatic resection: prospective randomized trial. *Ann Surg* 2003;237:57–65.
- [5] Kawai M, Tani M, Yamaue H. Transection using bipolar scissors reduces pancreatic fistula after distal pancreatectomy. *J Hepatobiliary Pancreat Surg* 2008;15:366–72.
- [6] Bassi C, Dervenis C, Butturini G, Fingerhut A, Yeo C, Izbicki J. Postoperative pancreatic fistula: an international study group (ISGPF) definition. *Surgery* 2005;138:8–13.
- [7] Butturini G, Daskalaki D, Molinari E, Scopelliti F, Casarotto A, Bassi C. Pancreatic fistula: definition and current problems. *J Hepatobiliary Pancreat Surg* 2008;15:247–51.
- [8] van Berge Henegouwen MI, De Wit LT, Van Gulik TM, Obertop H, Gouma DJ. Incidence, risk factors, and treatment of pancreatic leakage after pancreaticoduodenectomy: drainage versus resection of the pancreatic remnant. *J Am Coll Surg* 1997;185:18–24.
- [9] Enestvedt CK, Diggs BS, Cassera MA, Hammill C, Hansen PD, Wolf RF. Complications nearly double the cost of care after pancreaticoduodenectomy. *Am J Surg* 2012;204:332–8.
- [10] Seetharam P, Rodrigues GS. Postoperative pancreatic fistula: a surgeon's nightmare! An insight with a detailed literature review. *JOP* 2015;16:115–24.
- [11] William ST, Woltering EA, O'Dorisio TM, Fletcher WS. Effect of octreotide acetate on pancreatic exocrine function. *Am J Surg* 1989;157:459–62.
- [12] Li-ling J, Irving M. Somatostatin and octreotide in the prevention of post-operative pancreatic complications and the treatment of enterocutaneous pancreatic fistula: a systematic review of randomized controlled trials. *Br J Surg* 2001;88:190–9.
- [13] Pederzoli P, Bassi C, Falconi M, Albrigo R, Vantini I, Micciolo R. Conservative treatment of external pancreatic fistulas with parenteral nutrition alone or in combination with continuous intravenous infusion of somatostatin, glucagon or calcitonin. *Surg Gynecol Obstet* 1986;163:428–32.
- [14] Prinz RA, Pickleman J, Hoffman JP. Treatment of pancreatic cutaneous fistulas with a somatostatin analog. *Am J Surg* 1988;155:36–42.
- [15] Lowy AM, Lee JE, Pisters PW, Davidson BS, Fenoglio CJ, Stanford B. Prospective, randomized trial of octreotide to prevent pancreatic fistula after pancreaticoduodenectomy for malignant disease. *Ann Surg* 1997;226:632–41.
- [16] Yeo CJ, Cameron JL, Lillemoe KD, Sauter PK, Coleman J, Sohn TA. Does prophylactic octreotide decrease the rates of pancreatic fistula and other complications after pancreaticoduodenectomy? results of a prospective randomized placebo-controlled trial. *Ann Surg* 2000;232:419–29.
- [17] Sarr MG. The potent somatostatin analogue vapreotide does not decrease pancreas-specific complications after elective pancreatectomy: a prospective, multicenter, double-blinded, randomized, placebo-controlled trial. *J Am Coll Surg* 2003;196:556–64.
- [18] Yokoe M, Takada T, Mayumi T, Yoshida M, Isaji S, Wada K. Japanese guidelines for the management of acute pancreatitis: Japanese guidelines 2015. *J Hepatobiliary Pancreat Sci* 2015;22:405–32.
- [19] Adachi T, Kuroki T, Kitasato A, Hirabaru M, Matsushima H, Eguchi S. Safety and efficacy of early drain removal and triple-drug therapy to prevent pancreatic fistula after distal pancreatectomy. *Pancreatology* 2015;15:411–6.
- [20] Tanaka T, Kuroki T, Adachi T, Ono S, Kitasato A, Eguchi S. Development of a novel rat model with pancreatic fistula and the prevention of this complication using tissue-engineered myoblast sheets. *J Gastroenterol* 2013;48:1081–9.
- [21] Caroline SM, Garry AA, Amanda JO. Association between canine pancreatic-specific lipase and histologic exocrine pancreatic inflammation in dogs: assessing specificity. *J Vet Diagn Invest* 2012;24:312–8.
- [22] Allen PJ, Genen M, Brennan MF, Bucknor AA, Robinson LM, Pappas MM. Pasireotide for postoperative pancreatic fistula. *N Engl J Med* 2014;370:2014–22.