

An Imported Human Malarial Case Characterized by Severe Multiple Infections of the Red Blood Cells

Masuhisa TSUKAMOTO

*Department of Epidemiology, Institute for Tropical Medicine,
Nagasaki University, Nagasaki*

Abstract : Thin blood smears prepared from a Japanese student showed malaria parasites of which characteristics were similar to those of *Plasmodium vivax* except for their heavy multiple infections of the host red blood cell (RBC). Immediately after returning to Japan from a trip to Afghanistan, the patient showed severe symptoms with an irregular pattern of fever. However, examination of the blood smear taken on admission indicated that the parasitaemia was only 0.82%. More than 30% of the infected RBC were invaded by 2 or more young trophozoites and up to 7 ring forms in a single RBC were photographed for illustration, whereas 8 rings/RBC had once been observed. All blood forms of the *vivax*-type parasite were detected in the host RBC with or without stippling. The infected RBC showed more or less enlargement in accordance with the growth of the parasites. The possibility of mixed infection with *P. falciparum* and *P. vivax* was rejected on the basis of the features of the infected host cells and the absence of elongated gametocytes. Merozoite numbers ranged from 12 to 19 with an average of 15.4, thus the diagnosis of *P. malariae* or *P. ovale* was also excluded. In some simian malaria parasites, it is known that such severe multiple infections are characteristic and that the morphology of blood stages is practically very difficult to distinguish from that of *P. vivax*. Therefore some possibilities of natural infection with a simian malaria parasite have also been discussed.

Imported cases of human malaria in Japan are increasing in number each year (Nakabayashi *et al.*, 1976). The writer has recently had an opportunity to examine thin blood smears taken from a university student, who was admitted to the Tohoku University Hospital, Sendai, Japan, as a patient suspected of having malaria almost immediately after coming home from a trip to Afghanistan. No detailed clinical information was available except that he showed an irregular pattern of high fever before and after admission to the hospital. At a glance of the thin blood smear under the microscope, severe multiple infections of the host erythrocytes (RBC)* were noticed in addition to the usual *vivax*-like malaria infection. This could not be easily ascribed to any parasite species of the typical human malaria. Among the usual human

Contribution No. 798 from the Institute for Tropical Medicine, Nagasaki University

Received for publication, May 20, 1977

* Abbreviation used : RBC for erythrocyte(s) or red blood cell(s)

malaria parasites, multiple infections of parasites in a single RBC are rather common in the case of *falciparum* malaria, and up to 8 rings were reported within a single RBC by Springall (1943). Even in the case of *vivax* malaria double or triple infections of the host cell occurs but severe cases of multiple infections are uncommon in *vivax* malaria. It is, therefore, very intriguing to diagnose the parasite species in this particular case. The present paper describes the results of the examination of blood smears of such a curious cases of human malaria.

MATERIALS AND METHODS

Two thin blood smears taken from the young male student mentioned above were sent, after Giemsa staining, to be examined. One (Slide A) was said to have been prepared on admission to the hospital on September 20, 1976, and hence prior to initiating chemotherapy with antimalarial drugs; and another (Slide B) was said to have been prepared a few day later during the chemotherapy. These blood smears were examined using an oil-immersion optical system, and the parasitaemia was counted as usual.

RESULTS

1. Parasitaemia

On the basis of trial counts of 15 microscopic fields on Slide A, 39 RBC were infected with malaria parasites among a total of 4736 RBC counted; thus the parasitaemia was 0.82% on admission. By a similar examination of Slide B, a greatly reduced parasitaemia (0.0027%) was found in the patient a few days after drug treatment had begun.

2. Erythrocytic Forms of the Parasites

Several different stages of the erythrocytic forms were observed. Only the infected RBC were then examined and Table 1 summarizes the results of such differential counts of the parasites. Among a total of 1,280 infected cells counted, about 800 RBC contained the young trophozoite (ring form) and about 300 RBC were infected with older trophozoites. The general appearance of the malaria parasites of different stages are briefly described below.

Young Trophozoites (Figs. 1-4): Typical ring forms are less amoeboid with a well developed vacuole and a diameter about one-fourth of the infected RBC. The nucleus is round or oval and usually single, but double chromatin dots of either equal or unequal size are often found; a small accessory dot is also observed frequently (Fig. 4).

Old Trophozoites (Figs. 5-11): Trophozoites become much more amoeboid and their features resemble those of *P. vivax* in size and shape. The older trophozoites usually occupy from two-thirds to three-fourths of the enlarged host cell. No band forms have been detected. The fine brownish black granules of malaria pigment become visible within the markedly irregular-shaped cytoplasm.

Immature Schizonts (Figs. 12-14): The nucleus is by now divided into 4-8 fragments of

Table 1. Differential counting of malaria parasites on the blood smear prepared from the patient on admission (Slide A)*

Parasite stage	No. of infected RBC examined	Percentage
Young trophozoites	797	62.3
Old trophozoites	308	24.1
Immature schizonts	92	7.2
Mature schizonts	28	2.2
Merozoite group	4	0.3
Gametocytes	51	4.0
Total	1,280	(100%)

* Counting was based on the examinations for 500 microscopic fields corresponding to about 1.56×10^5 RBC.

irregular shape, and the pigment granules are still not so evident. The immature schizonts develop largely within the RBC.

Mature Schizonts (Figs. 15-17): The schizont occupies large parts of the whole RBC and malaria pigments gather together to form a large mass at the center or masses at some peripheral portions. Nuclei are isolated from each other and hence the number of merozoites (or at least well separated chromatin dots) can be counted individually. The counts ranged from 12 to 19 with an average of 15.4 merozoites:

Merozoites/RBC	12	13	14	15	16	17	18	19
Counts	2	2	7	5	8	4	3	1

Gametocytes (Figs. 18-20, 32): Matured or nearly matured gametocytes are not crescent in shape, thus this excludes the possibility of *P. falciparum*. The cytoplasm of the gametocytes nearly fills the enlarged RBC, and dark pigment granules of different sizes are scattered in the cytoplasm.

3. Multiple Infections

One of the most remarkable characteristics of the present case was the tendency to heavy multiple infections of a single host RBC. Then only the infected RBC were assorted into several groups on the bases of the number of parasite(s) within each RBC and the different stages of the blood forms. Distribution of blood forms of the parasites in such differential counts for Slide A is summarized in Table 2. On admission more than 60% of the parasitized RBC were infected with young trophozoites (ring forms). Among a total of 1,280 infected cells counted, at least 18.8% were invaded by 2 or more parasites, or in other words, about 30% of the RBC invaded by the ring forms were found to have multiple infections. Double or triple infections were common and easily noticed at a glance (Figs. 4, 5, 21, 29, 30). Although the highest case of multiple infections, 8 rings in a single RBC was observed when a photographic attachment was not in place during the examinations, two cases of 7 rings per RBC have been photographed later (Figs. 27, 28). In the cases of multiple infections, mostly

Table 2. Multiple infections of the host RBC with young trophozoites of *vivax*-like parasites from the Slide A

No. of ring forms in a single RBC	No. of infected RBC examined	Percentage	Rate of multiple infections
1	557	69.9	
2	139	17.4	
3	51	6.4	
4	29	3.6	
5	17	2.1	
6	3	0.4	
7	1	0.1	
Total	797	(100%)	30.1%

young trophozoites of about the same stage were found within a single RBC, but in some cases combinations of the different stages of parasites were also observed, for example, 2 growing trophozoites (Fig. 30), several young and old trophozoites (Fig. 31), one gametocyte and 1-3 young trophozoites (Figs. 19, 32), 2 gametocytes (not shown in figures), and so on. In such cases, parasites were described as old trophozoites or gametocytes in Table 1. Thus the actual rate of multiple infections is higher than that shown in Table 2 where multiple infections were recorded on the basis of counts for only young trophozoites.

4. Stippling and Enlargement of the Infected Host RBC

The RBC infected with a young ring form usually does not show any stippling and the size of the RBC is also not enlarged (Figs. 1, 3, 4). In some cases, however, a markedly enlarged RBC harboured only a single young trophozoite without any stippling (not shown in figures). The RBC infected by several young or old trophozoites becomes enlarged with or without stippling. In the present case stippling is not so remarkable, and, where present, its colour is bluish gray instead of pink, the colour typical of Schüffner's dots. This might be due, however, to staining conditions because at most hospitals in Japan blood smears are routinely stained under slightly acidic conditions, such as pH 6.5-6.8. Trial counts of the infected RBC demonstrated that there was no difference in distribution of the parasites of various blood stages between the stippled RBC group and the unstippled RBC group. In other words, it is impossible to divide malaria parasites into 2 groups on the basis of the presence or the absence of Schüffner's dots in this case. Thus it is unlikely that there was a mixed infection of distinct parasite species. A single infection with the malaria parasite, especially with an old trophozoite, found in an enlarged and stippled RBC shows characteristics rather

Figs. 1-3 : Trophozoites in a host RBC with or without stippling ; Fig. 4 : Trophozoites with an accessory chromatin dot ; Fig. 5 : Growing trophozoites in a well-stippled and elongated RBC ; Figs. 6-11 : Old trophozoites in an enlarged RBC with or without stippling ; Figs. 12-14 : Immature schizonts ; Figs. 15-17 : Mature schizonts ; Figs. 18-20 : Gametocytes.

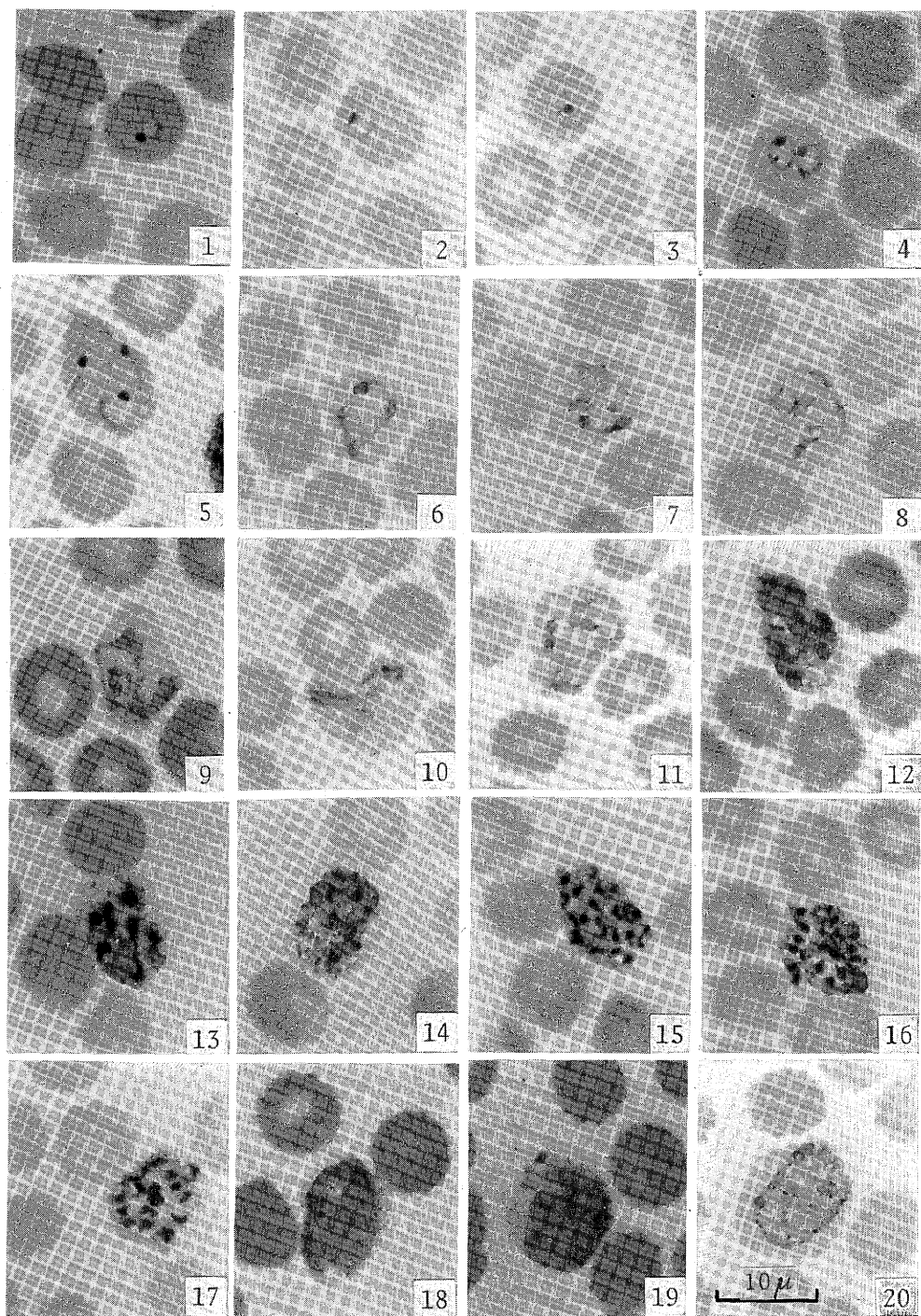


PLATE I. — Various blood stages of *vivax*-like malaria parasites.

typical of *P. vivax* infection. In some cases, the infected RBC showed the highly deformed shape similar to *P. ovale* infection (Figs. 5, 12, 15, 29).

5. Examination of Slide B

All the observations described in previous sections were based on the examination of Slide A, but parasitological informations obtained from the examination of Slide B have been markedly different from above because of the consequence of the chemotherapy with antimalarials. A total of 29 parasites could be detected after extensive examination of 387 microscopic fields corresponding to about 1.07×10^5 RBC. The parasitaemia calculated was thus 0.0027%. The parasites detected were: 2 ring forms, 9 old trophozoites, 3 immature schizonts, and 15 gametocytes. The morphology of all the parasites except gametocytes appeared to be greatly damaged presumably by the drug treatment, and no multiple infections were detected. Both microgametocytes and macrogametocytes appeared to be intact morphologically, and again no crescent-typed gametocytes were observed.

DISCUSSION

The phenomenon of multiple infections of the host RBC is not rare in human malaria. Especially, in *P. falciparum*, it is rather frequent. As an extreme case, up to 8 young trophozoites have been reported within a single RBC by Springall (1943) in a fatal case where the parasitaemia was more than 44% and the rate of multiple infections was 37.0%. Field and Shute (1956) also showed an example of multiple infections in a fatal case where the parasitaemia was more than 38.3% just before death, and the rate of multiple infections was 23.6% with a maximum of 7 rings in a cell. In the present case of human malaria, however, the possibility of mixed infections with *P. falciparum* and another species is not acceptable by the evidence mentioned above: *i. e.*, stippling and enlargement of the infected host cells and the shape of gametocytes.

In the case of *P. vivax*, double or triple invasions of the host RBC are also not uncommon whereas the frequency of multiple infections and the number of parasites found within single cells are usually not so high as in cases of *P. falciparum*. In an extreme case of even *P. vivax*, however, Field (1942) recorded exceptionally heavy infections where one RBC appeared to have 8 young trophozoites. The rate of multiple infections is calculated to be 37.6% from his data. As cited by Field and Shute (1956), similar severe cases of multiple infections with up to 6 rings/RBC were also recorded by Chalmers and Archibald (1920), Rodenhuis

Figs. 21–22 : Trophozoites with 2 chromatin dots or nearly divided nucleus; Fig. 23 : 4 Ring forms in a host cell with stippling ; Figs. 24–26 : 5 Ring forms in a host RBC ; Figs. 27–28 : 7 Ring forms in a single RBC ; Fig. 29 : Deformed RBC with young or old trophozoites; Fig. 30 : Double infection of RBC with 2 growing trophozoites ; Fig. 31 : An enlarged RBC invaded by 3 old trophozoites and 3 young trophozoites; Fig. 32: A single RBC occupied by a large gametocyte and 3 young trophozoites.

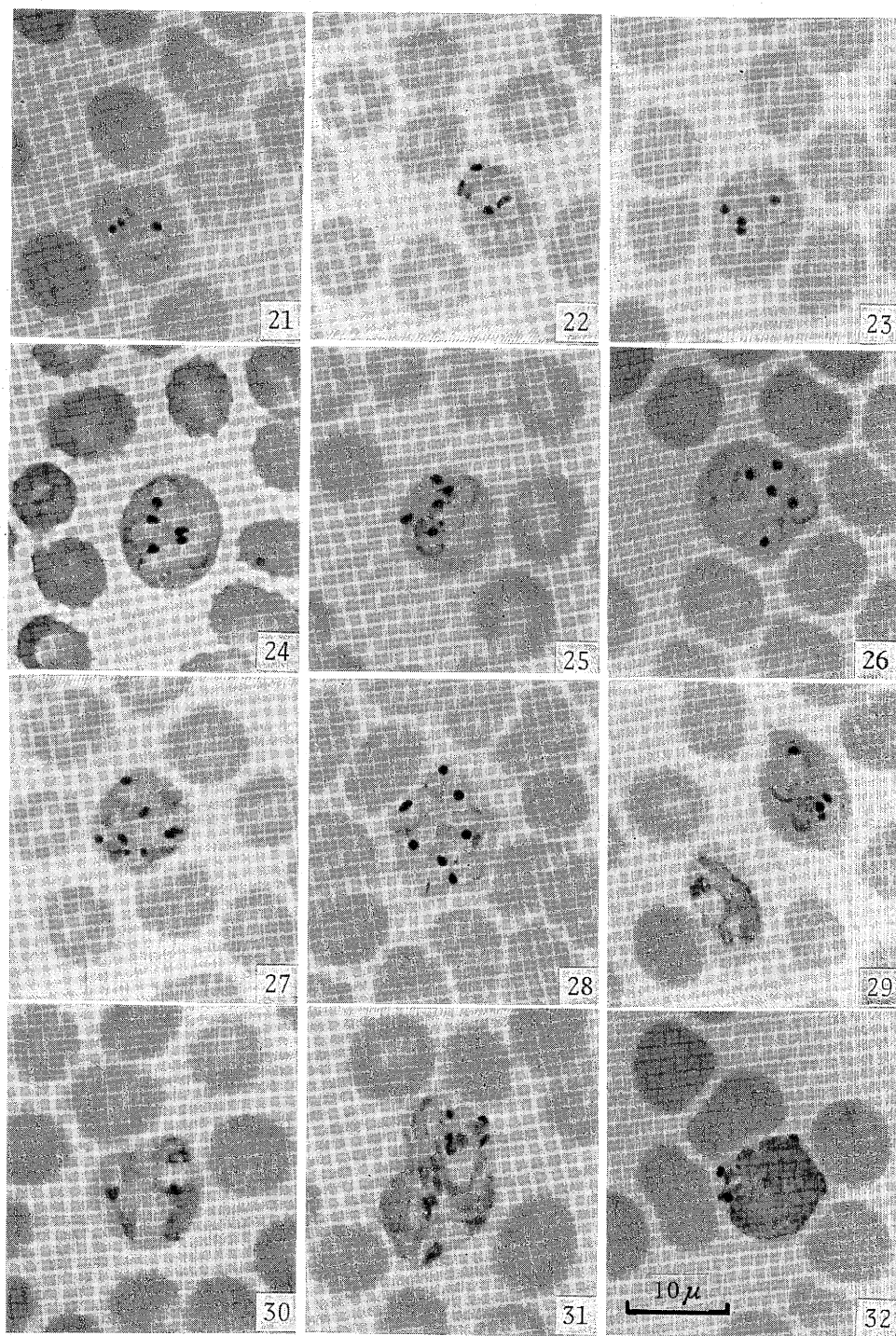


PLATE II. — Multiple infections of a single host RBC.

(1921), Das Gupta (1939) and Young and Eyles (1949). In the case of *P. ovale*, double or triple infections of single RBC are more common than in cases of *P. vivax* but any heavy multiple infection of *P. ovale* has not been reported so far. On the other hand, multiple infection of the RBC is extremely rare in the case of *P. malariae*.

In contrast to these human malaria parasites, the phenomena of multiple infections have been reported to be more frequent in several simian malaria species. For example, in *P. cynomolgi bastianellii* the presence of up to 6 ring forms has been described by Garnham (1966), and in *P. cynomolgi cyclopis* up to 7 rings have been recorded by Inoki *et al.* (1942), whereas in the original *P. cynomolgi cynomolgi* such heavy multiple infections have not been reported (with up to 4 parasites). *P. eylesi* is also one of the simian malaria species characterized by a high frequency of multiple infections and the average rate of multiple infection reported was 29.45% by Warren *et al.* (1965).

In the present case of *vivax*-like malaria, the writer's first impression during the microscopic examination of the thin blood smears was so curious that the possibility of simian malaria parasites came to mind. Garnham (1966) has pointed out that parasites of simian origin might explain some of the abnormal or aberrant forms reported as *P. vivax*. Indeed, the human is more or less susceptible to the infection of certain simian malaria parasites (Garnham, 1966; Coatney *et al.*, 1971). So far the malaria parasites of simian origin distributing in south-east and central south Asia which are known to be infectious to humans whether naturally, accidentally or experimentally, are: *P. knowlesi* (Knowles and Das Gupta, 1932; Chin *et al.*, 1965; Yap *et al.*, 1971; *etc.*), *P. cynomolgi* (Schmidt *et al.*, 1961; Coatney *et al.*, 1961; Bennet and Warren, 1965), *P. cynomolgi bastianellii* (Eyles *et al.*, 1960; Garnham *et al.*, 1962; *etc.*), *P. eylesi* (Coatney *et al.*, 1971), and *P. inui* (Das Gupta, 1938). It is, therefore, not unlikely that the malaria parasite of the present human case is of some simian origin.

P. vivax and *P. cynomolgi bastianellii* resemble each other and practically are not easy to distinguish by means of examination of a blood film alone whereas they can be differentiated by knowing other stages of the life cycle and their infectivity to the rhesus monkey. Because of the marked resemblance of *P. cynomolgi bastianellii* to the aberrant forms of *P. vivax* reported by Field (1942), Sandosham *et al.* (1962) have stated in their record that "a possible explanation may be that Field was in fact dealing with two cases of naturally acquired human infections of *P. c. bastianellii* of monkey origin." According to Garnham *et al.* (1962), too, "the first important clue in the differential diagnosis of *bastianellii* and *vivax* malaria" is that "the human infections (of *P. c. bastianellii*) are characterized by the association of relative severity of symptoms with very low parasitaemia." These characteristics are also applicable to the present situation, although the present parasitaemia of 0.82% is still higher than the very low level of their concept. A diagnostic method more conclusive than morphology is to test infectivity to the rhesus monkey: *i. e.*, *P. vivax* cannot invade the rhesus monkey whereas *P. c. bastianellii* can easily do so. However, when the present writer could examine the blood smears, the patient was already discharged from the hospital after curative therapy. Hence a desirable subinoculation of the blood samples into rhesus monkeys and subsequent

confirmation of whether the parasite was an aberrant form of the human *vivax* malaria or one of the rare cases of natural infection with a parasite of simian origin had become impossible. The likelihood of infection with *P. eylesi* may be excluded by its higher number of merozoites (or at least divided chromatin dots) than that found in the present case. Another possibility of a mixed infection with *P. vivax* and a similar simian malarial parasite still remains obscure. At present, therefore, the writer must suspend making a definite diagnosis of the parasite species.

ACKNOWLEDGMENTS

The writer is grateful to Dr. Yoshio Uzuka, Department of Internal Medicine of the Institute, for providing the opportunity to examine the present blood smears sent from the Tohoku University Hospital, and to Dr. J. T. Ponnampalam, Malaria Division, Institute for Medical Research, Kuala Lumpur, Malaysia, for his kind arrangement for obtaining invaluable literature. Critical reading of the manuscript and useful suggestions by Miss Joan Bodurtha are also particularly appreciated.

REFERENCES

- 1) Bennet, G. F. & Warren, M. (1965) : Transmission of a new strain of *Plasmodium cynomolgi* to man. J. Parasitol., 51, 79-80.
- 2)* Chalmers, A. J. & Archibald, R. G. (1920) : The 'tenue' phase of *Plasmodium vivax* (Grassi & Feletti, 1890). J. Trop. Med. Hyg., 23, 33.
- 3) Chin, W., Contacos, P.G., Coatney, G.R. & Kimball, H.R. (1965) : A naturally acquired quotidian-type malaria in man transferable to monkeys. Science, 149, 865.
- 4) Coatney, G. R., Collins, W. E. & Contacos, P. G. (1971) : The primate malarias. 366 pp., U.S. Government Printing Office, Washington.
- 5) Coatney, G. R., Elder, H. A., Contacos, P. G. & Getz, M. E. (1961) : Transmission of the M strain of *Plasmodium cynomolgi* to man. Amer. J. Trop. Med. Hyg., 10, 673-678.
- 6)* Das Gupta, B. M. (1938) : Transmission of *Plasmodium inui* to man. Proc. Natl. Inst. Sci. India, 4, 241-244.
- 7) Das Gupta, B. M. (1939) : Some anomalies in the morphology of *Plasmodium vivax* occurring in a newborn baby. Indian Med. Gaz., 74, 273.
- 8) Eyles, D. E., Coatney, G. R. & Getz, M. G. (1960) : Vivax-type malaria parasite of macaques transmissible to man. Science, 131, 1812-1813.
- 9) Field, J. W. (1942) : Morphological variation in *Plasmodium vivax* Grassi & Feletti, 1890. Parasitology, 34, 82-87.
- 10) Field, J. W. & Shute, P. G. (1956) : The microscopic diagnosis of human malaria. II - A morphological study of the erythrocytic parasites. Studies Inst. Med. Res. Feder. Malaya, No. 24. 251 pp., Government Press, Kuala Lumpur.
- 11) Garnham, P. C. C. (1966) : Malaria parasites and other haemosporidia. 1114 pp., Blackwell Sci. Publ., Oxford.
- 12) Garnham, P. C. C., Molinari, V. & Shute, P. G. (1962) : Differential diagnosis of *bestianellii*

- and vivax malaria. Bull. Wld Hlth Org., 27, 199-202.
- 13) Inoki, S., Takemura, S., Makiura, Y. & Hotta, F. (1942) : A malaria parasite, *Plasmodium inui* var. *cyclopi*s Inoki, Takemura, Makiura & Hotta, 1941 in *Macacus cyclopi*s Swinhoe. Osaka Igakkai Zasshi, 41, 1327-1343. (in Japanese)
 - 14)* Knowles, R. & Das Gupta, B. M. (1932) : A study of monkey-malaria, and its experimental transmission to man. Indian Med. Gaz., 67, 301-320.
 - 15) Nakabayashi, T., Ebisawa, I., Ohtomo, H. & Ishizaki, T. (1976) : Investigation of imported malaria cases in Japan in 1972-1974. J. Trop. Med. Hyg., 79, 247-251.
 - 16)* Rodenhuis, Y. (1921) : Dubbel-en superinfectie bij malaria tertiana. Geneesk. Tijdschr. v. Nederl.-Indie, 61, 123.
 - 17) Sandosham, A. A., Eyles, D. E. & Yap, L. F. (1962) : *Plasmodium cynomolgi bastianellii* from a Malayan monkey and its similarity to aberrant *P. vivax* in man. Med. J. Malaya, 17, 78-79.
 - 18) Schmidt, L. H., Greenland, R. & Genther, C. S. (1961) : The transmission of *Plasmodium cynomolgi* to man. Amer. J. Trop. Med. Hyg., 10, 679-688.
 - 19) Springall, A. N. (1943) : Heavy density of *P. falciparum* parasites in malaria. Report of a case. Amer. J. Trop. Med., 23, 533-535.
 - 20) Warren, M., Bennett, G. F., Sandosham, A. A. & Coatney, G. R. (1965) : *Plasmodium eylesi* sp. nov., a tertian malaria parasite from the white-handed gibbon, *Hylobates lar*. Ann. Trop. Med. Parasit., 59, 500-508.
 - 21) Yap, L. F., Cadigan, F. C. & Coatney, G. R. (1971) : A presumptive case of naturally occurring *Plasmodium knowlesi* malaria in man in Malaysia. Trans. Roy. Soc. Trop. Med. Hyg., 65, 839-840.
 - 22)* Young, M. D. & Eyles, D. E. (1949) : Parasites resembling *Plasmodium ovale* in strains of *Plasmodium vivax*. J. Natl. Mal. Soc., 8, 219.
- * Not seen, cited by Field & Shute (1956) ; Garnham (1966) ; Coatney *et al.* (1971)

猿マラリアを疑わしめる多重感染の著しい輸入マラリア例

塚本増久 (長崎大学熱帯医学研究所疫学部門)

アフガニスタンへの旅行から帰国直後東北大学附属病院に入院した不定型熱発のマラリア患者の薄層血液標本の同定を依頼された。この標本は感染赤血球率が0.82%と比較的低いにもかかわらず、顕著な多重感染が特徴的であって極めて奇異な感じをいだかせた。即ち1個の赤血球に複数個のマラリア原虫が同時に寄生しているものは感染赤血球の約30%におよび、最高8個の環状体が侵入している例も観察された。薄層標本には三日熱型原虫の各段階が検出され、メロゾイト数は12個から19個(平均15.4個)であって、被寄生赤血球は通常次第に膨大し、Schüffnerの斑点は示すものと示さないものがほとんど同数見られた。人間のマラリアでは、通常、多重感染は熱帯熱マラリアの場合最も普通で、最高8個の環状体の入った例も記録されているが、三日熱・卵型マラリアの場合はそれほど著しくなく、四日熱では稀である。一方、猿のマラリアの中には著しい多重感染を示す種類が幾つか知られており、人間に自然感染または実験感染する例も報告されている。従来三日熱マラリアの異常型と同定された多重感染の著しい例が知られているが、最近ではこれらは実は猿のマラリアの自然感染例ではなかったらうかと考える学者もあり、筆者もこれと同意見である。ただ、本症例の場合は患者の治療退院後に薄層血液標本を検査する機会を得たので、アカゲザルに対する感染能力の有無などの決め手となるべき感染実験を行うことは既に不可能であった。従ってここでは果して三日熱マラリアの異常型であったのか、それともある種の猿マラリアの人体自然感染例であったのかを断定することは避け、今後の参考迄に、マラリア患者に遭遇した場合、臨床医は後事に備え治療開始前のマラリア原虫(患者血液)を-70°C以下で生きたまま凍結保存しておくことが望ましいことを書き添えておきたい。