

Treatment of *Dipetalonema gracile* in *Cebus apella* by Ivermectin

Makoto SAKAMOTO², Osamu FUJITA², Alicia SCHININI³,
Alba INCHAUSTI¹, Rosa RAMONA S³., Antonieta ROJAS de Arias³
and Ricardo MORENO A.³

¹Department of Parasitology, Institute of Tropical Medicine, Nagasaki University,
12-4, Sakamoto-machi, Nagasaki 852, Japan

²Hokkaido Medical Animal Center, N-3, W-24, 259, Chuo-ku, Sapporo, 064, Japan

³Instituto de Investigaciones en Ciencias de la Salud, Rio de la Plata y Lagerenza, Asun-
ción, 2511, Paraguay

Abstract: The microfilaricidal effect of ivermectin was studied on *Cebus apella* infected with *Dipetalonema gracile* in Paraguay. Nine monkeys were treated with ivermectin at the dosage of 200 µg/kg body weight by single subcutaneous injection. The significant reduction in microfilarial count after treatment of ivermectin was recognized ($P < 0.01$). The change of blood picture of 9 monkeys infected with *D. gracile* following treatment of ivermectin also studied. The total WBC count was found to be significantly increased at 1 day after the treatment. Differential count study showed that neutrophils increased in most monkeys. On the other hand, the significant change in eosinophil and lymphocyte count was not observed.

Key words: *Dipetalonema gracile*, Ivermectin, Treatment

INTRODUCTION

It is well known that *Cebus apella*, one of the most popular monkey in the New World, harbor Dipetalonematidae in peritoneal cavity (Yagi *et al.*, 1986). However, little is known about chemotherapy of this filariasis. In general, diethylcarbamazine (DEC) is widely used in chemotherapy of human and animal filariasis, being particularly effective against microfilariae of lymphatic filariasis due to *Brugia malayi*, *Brugia timori* and *Wuchereria bancrofti*. However, DEC is not a entire drug for onchocerciasis, subcutaneous filariasis, because of its severe inflammatory reactions though it shows a remarkable microfilaricidal effect. On the other hand, ivermectin, an antihelmintic drug in wide use for several years by the veterinary industry, has recently been found to be less side effects and effective against *Onchocerca volvulus* and *W. bancrofti* (Greene *et al.*, 1985, Kumaraswani *et al.*, 1988).

The present study describes the microfilaricidal effect of ivermectin and inflammatory reactions elicited by treatment in *C. apella* infected with *Dipetalonema gracile*.

Received for Publication, September 11, 1991.

Contribution No. 2536 from the Institute of Tropical Medicine, Nagasaki University.

This study was performed as part of Paraguay/Japan medical cooperation project on Chagas' disease supported by Japan International Cooperation Agency (JICA).

MATERIALS AND METHODS

Twelve monkeys (3 males and 9 females), *C. apella*, were provided for this study. All of them were captured in the northern part of Paraguay and maintained for more than one year in the Laboratory of Institute of Health Science, Asunción University. *D. gracile* microfilariae were detected in all of their blood stream. Microfilarial densities were ranged from 163 to 60,784 per 0.5 ml of blood. Nine monkeys were treated with ivermectin (Merck, Sharp & Dohme) at the dosage of 200 µg/kg body weight by single subcutaneous injection. Three monkeys were given saline solution through subcutaneous as the control group. By the Knott's concentration method, the number of microfilariae per 0.5 ml of blood were counted at 1, 2 days and 1, 2, 3, 4 weeks after the initial treatment (Knott, 1930).

To know the inflammatory reaction after treatment, haematological examination was carried out. Total number of white blood cell (WBC) per cubic millimeter of blood was counted by conventional method and differential cell count was assessed under giemsa staining. The blood examination was made between 9:00 and 10:00. Statistical analysis was performed where appropriate using Wilcoxon's rank-sum test.

RESULTS

Table 1 shows the effect of ivermectin on the microfilarial count of *D. gracile*. Mean percentages of reduction on microfilarial count of treated group at 1, 2, 7, 14, 21 and 28 days after the treatment were 48.4, 37.4, 49.2, 55.7, 53.3 and 49.7% respectively. On the other hand, microfilarial densities of control group was not decreased after the injection of saline solution. The percentage of maximum reduction in microfilarial count of each monkeys rang-

Table 1. Microfilarial count in 0.5 ml blood of *Cebus apella*

Monkey No.	Number of microfilarae							
	Before	Days after treatment						
		1	2	7	14	21	28	
treated group	1	163	29	12	21	19	22	24
	2	6,875	1,999	1,331	1,142	1,572	1,328	1,991
	3	1,068	390	443	505	529	690	616
	4	503	3	4	0	1	2	1
	5	286	93	91	133	121	156	140
	6	12,776	6,988	4,005	5,303	6,480	5,792	5,552
	7	2,179	65	59	50	59	52	61
	8	34,432	22,416	23,408	21,648	18,832	20,496	20,770
	9	60,784	29,440	45,216	30,960	25,136	27,016	30,688
control	10	246	191	273	257	340	245	203
	11	3,210	2,998	3,751	4,472	3,840	3,446	4,008
	12	3,734	3,372	3,304	3,480	3,438	3,024	3,216

ed from 45.3 to 100%. One of 9 monkeys showed the maximum reduction in microfilarial count at 1 day after the treatment. Three monkeys showed the maximum reduction at 2 days after the treatment. In other 5 monkeys, the maximum reduction was revealed at 1 and 2 weeks after the treatment. A significant decrease in microfilarial count was found at 1, 2, 7, 14, 21, 28 days after the treatment of ivermectin ($P < 0.01$). The change of blood picture of 9 monkeys infected with *D. gracile* following treatment of ivermectin was shown in Fig. 1. The total WBC count was found to be increased at 1 day after the treatment. Seven of 9 monkeys showed the significant increase in total number of WBC at 1 day after the treatment. The rate of increase varied from 2 to 115 percent of the initial count. On day 2 after treatment, the total WBC count returned to the level of initial count. Differential count study showed that neutrophils increased in 7 of 9 monkeys with the range from 52 to 425% of the initial count at 1 day after the treatment. All monkeys with the increase of total WBC showed the increase of neutrophil. The significant change in eosinophil and lymphocyte count was not observed during this experiment.

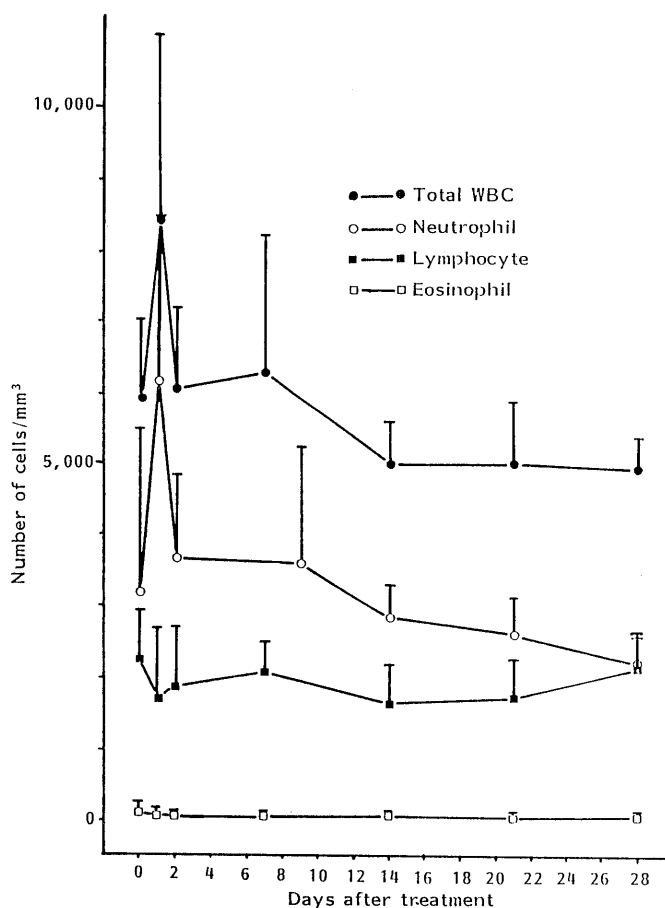


Fig. 1. Changes of blood picture following ivermectin administration.

DISCUSSION

In this study, ivermectin were firstly tested for it's effectiveness against natural infection of *D. gracile* in *C. apella*. Nine monkeys were treated with ivermectin at a single dose of 200 $\mu\text{g}/\text{kg}$. The maximum reduction in numbers of microfilariae ranged from 45.3 to 100% of initial level. Out of 9 monkeys, 7 showed the maximum reduction in numbers of microfilariae within 1 week after treatment, and these level were maintained over the next 4 weeks. Awadzi *et al.* (1985) reported that microfilarial densities fell progressively to reach their lowest level at 1 month after the treatment of ivermectin (200 $\mu\text{g}/\text{kg}$) in patient with onchocerciasis, and these level were maintained over next 32 weeks. Soboslay *et al.* (1987) also reported that abnormal motility was observed in microfilariae in the anterior camber of patient with onchocerciasis at 2 days after the treatment of ivermectin. Furthermore, Freedmann *et al.* (1989) reported that ivermectin was 100% effective against human ascariasis and strongyloidiasis on 1 month after treatment.

On the other hand, diethylcarbamazice (DEC) was one of the most effective drugs against filariasis during recent four decades. Eberhard (1982) described the marked reduction in numbers of microfilariae of *D. gracile* in squirrel monkeys when treated with DEC (50 mg/kg/day for 10 days). However, the numbers of microfilariae had returned to pretreatment level within 4 to 20 weeks. The mechanism(s) of microfilarial killing by DEC were related to a variety of condition in host such as complement activation (Hammerberg and Staiunas, 1982), activation of granulocytes (King *et al.*, 1983), presence of specific antibody (Sakamoto *et al.*, 1984), and adherence of effector cells to microfilariae (Piessens and Beldekas, 1979; Chandrashekar *et al.*, 1984). On the other hand, Soboslay *et al.* (1987) suggested that ivermectin directly impaired motility of microfilariae inducing spastic paralysis. In our study, it was also suggested that rapid reduction of microfilariae was caused by direct effect of ivermectin.

The inflammatory reaction in patient with filariasis during the treatment of filaricidal drugs have been discussed. It was generally considered that inflammatory reaction caused by DEC administration was the result of speedy killing of microfilariae. The histological studies showed that neutrophils, eosinophils and lymphocytes appeared in close proximity to damaged microfilariae (Haqking, 1952, Gibson *et al.*, 1976). These inflammatory reactions may induce the change of blood picture of patient. Sakamoto *et al.* (1983) reported that the total WBC count was found to be rised in patient with onchocerciasis at 3 days after the initial treatment of DEC. On the other hand, Awadzi *et al.* (1985) reported that there was an increase in total WBC counts after day 8, but the levels remained within the normal range. Our study also showed that WBC cont increased (ranged from 2 to 115%) at 1 day after treatment, but returned to the initial level at 2 days after treatment. The particular role of eosinophil also have been discussed in inflammatory reaction caused by filaricidal treatment (Bryceron, 1977; Henson *et al.*, 1979; Guerra-Caceres *et al.*, 1980). Money (1960) reported that the number of eosinophil count decreased during the DEC treatment of patient with onchocerciasis. Guerra-Caceres *et al.* (1980) also described the eosinopenia in patient with onchocerciasis at 12 hours after the treatment of DEC. When ivermectin was used for patient

with onchocerciasis, Awadzi *et al.* (1985) reported that there was a slight fall in eosinophil counts maximal at 36 hours, followed by a steady rise, so that a definite increase above pretreatment levels had occurred by day 8, and by day 28 the level was more than twice the initial level. In our study, there was no significant change in eosinophil count during the treatment of ivermectin in *C. apella* infected with *D. gracile*. Although the increase in WBC and neutrophil counts was revealed at 1 day after treatment, the present study suggested that ivermectin might not induce severe inflammatory reaction in *C. apella* infected with *D. gracile*.

ACKNOWLEDGMENT

We wish to thank Dra. E. Kasamatsu, chief of Department of Pathology, Instituto de Investigaciones en Ciencias de la Salud, and her colleagues for their kind cooperation. We also appreciate Lic. Y. Akimoto for her helpful assistance in this study.

REFERENCES

- 1) Awazi, K., Shulz-Key, H., Haddoch, D.R.W., Gilles, H.M. & Aziz, M.A. (1985): The chemotherapy of onchocerciasis X. An assessment of four single treatment regimens of MK-933 (Ivermectin) in human onchocerciasis. *Ann. Trop. Med. Parasitol.*, 79, 63-78.
- 2) Bryceson, A.D.M., Warrell, D.A. & Pope, H.M. (1977): Dangerous reaction to treatment of onchocerciasis with diethylcarbamazine. *Brit. Med. J.*, 1, 742-744.
- 3) Chandrashekar, R., Rao, U.R. & Subrahmanyam, D. (1984): Effect of diethylcarbamazine on serum dependent cell-mediated immune reactions to microfilariae *in vitro*. *Tropenmed. Parasit.*, 35, 47-49.
- 4) Eberhard, M.L. (1982): Chemotherapy of filariasis in squirrel monkeys. *Labo. Ani. Sci.*, 32, 397-400.
- 5) Freedman, D.O., Zierdt, W.S., Lujan, A. & Nutman, T.B. (1989): The efficacy of ivermectin in the chemotherapy of gastrointestinal helminthiasis in humans. *J. Infect. Dis.*, 159, 1151-1153.
- 6) Gibson, D.W., Conner, D.H., Brown, H.L., Fuglsang, H., Amderson, J., Duke, B.O.L. & Buck, A.A. (1976): Onchocercal dermatitis: Ultrastructural studies of microfilariae and host tissues, before and after treatment with diethylcarbamazine (Hetrazan). *Am. J. Trop. Med. Hyg.*, 25, 74-87.
- 7) Greene, B.M., Taylor, H.R., Cupp, E.W., Murphy, R.T., White, A.T., Aziz, M.A., Shulz-key, H., D'Anma, S.A., Newland, H.S., Goldschmidt, L.P., Auer, C., Hanson, A.P., Feeman, S.V., Reber, E.W. & William, P.N. (1985): Comparison of ivermectin and diethylcarbamazine in the treatment of onchocerciasis. *N. Engl. J. Med.*, 313, 133-138.
- 8) Guerra-Caceres, J.G., Bryceson, A.D.M., Quakyi, I. & Spry, C.J.F. (1980): Studies on the mechanisms of adverse reactions produced by diethylcarbamazine in patients with onchocerciasis-Mazzotti reaction. *Parasitol. Immunol.*, 2, 121-131.
- 9) Hammerberg, B. & Staniunas, R.J. (1982): Diethylcarbamazine-enhanced activation of complement by intact microfilariae of *Dirofilaria immitis* and their *in vitro* products. *J. Parasit.*, 65, 809-816.
- 10) Hawking, F. (1952): A histological study of onchocerciasis treated with Hetrazan, *Br. Med.*, 1, 992-994.

- 11) Henson, P.M., Mackenzie, C.D. & Spector, W.G. (1979): Inflammatory reactions in onchocerciasis: A report on current knowledge and recommendation for further study. Bull. WHO., 57, 667–682.
- 12) King, C.H., Greene, B.M. & Spagnuolo, P.J. (1983): Diethylcarbamazine citrate, an antifilarial drug, stimulates human granulocyte adherence. Antimicrob. Agents. Chemother., 24, 453–456.
- 13) Knott, J. (1930): A method for microfilarial surveys on day blood. Trans. Roy. Soc. Trop. Med. Hyg., 33, 191–197.
- 14) Kumoraswami, V., Ottesen, E.A., Vijayasekaran, V., Devi, S.U., Swaminathan, M., Aziz, M.A., Sarma, G.R., Prabhaker, R. & Tripathy, S.P. (1988): Ivermectin for the treatment of *Wuchereria bancrofti* filariasis. Efficacy and adverse reactions. JAMA., 259, 3150–3153.
- 15) Money, G.L. (1960): 'Hetrazan' eosinopenia in onchocerciasis. A preliminary communication. J. Trop. Med. Hyg., 63, 238–241.
- 16) Piessens, W.F. & Beldekas, N. (1979): Diethylcarbamazine enhances antibody mediated cellular adherence to *Brugia malayi* microfilariae. Nature, 282, 845–847.
- 17) Sakamoto, M. & Zea, G.F. (1983): The change of blood picture of patients with onchocerciasis following administration of diethylcarbamazine. Trop. Med., 25, 47–50.
- 18) Soboslay, P.T., Newland, H.S., White, A.T., Erttmann, K.D., Albiez, E.J., Taylor, H.R., Williams, P.N. & Greene, B.M. (1987): Ivermectin effect on microfilariae of *Onchocerca volvulus* after a single oral dose in humans. Trop. Med. Parasit., 38, 8–10.
- 19) Yagi, K., Minezawa, M & Grock, R.T. (1986): Helminth parasites of Bolivian Cebid monkeys. Kyoto University Overseas Research, Reports of New Monkeys, 6, 51–55.