

# Dysgerminoma of the Left Ovary in a Patient with Balanced Translocation 46X, t(X:1) (q22;q21): A Case Report

Koh Nagata , Takako Shimada, Chiaki Eishi, Masaki Nishi, Toru Murakami, Kazuaki Ohashi, Itsuki Kajimura, Kiyonori Miura

Obstetrics and Gynecology, Nagasaki University Hospital, Nagasaki, Japan

Correspondence: Koh Nagata, Obstetrics and Gynecology, Nagasaki University Hospital, Nagasaki, Japan, Tel +81 95 819 7363, Fax +81 95 819 7365, Email k.nagata.nagasaki.obgyn@gmail.com

**Abstract:** We report a case of dysgerminoma in a 22-year-old woman diagnosed with chromosomal abnormality, balanced translocation 46X,t(X:1)(q22;q21). She had received hormone replacement therapy for 7 years for primary amenorrhea. She visited a primary care physician because of lower abdominal distension, and a large tumor in the pelvis was discovered. She was admitted to our hospital for further examination of the pelvic tumor. She underwent laparotomy and was diagnosed with stage IIIA1 dysgerminoma (pT3apN0pM0) of the left ovary. Young female patients without the Y chromosome who are treated for primary amenorrhea may also develop malignant germ cell tumors; therefore, gynecologists should provide hormone replacement therapy and periodic pelvic evaluation.

**Keywords:** primary amenorrhea, balanced translocation, dysgerminoma

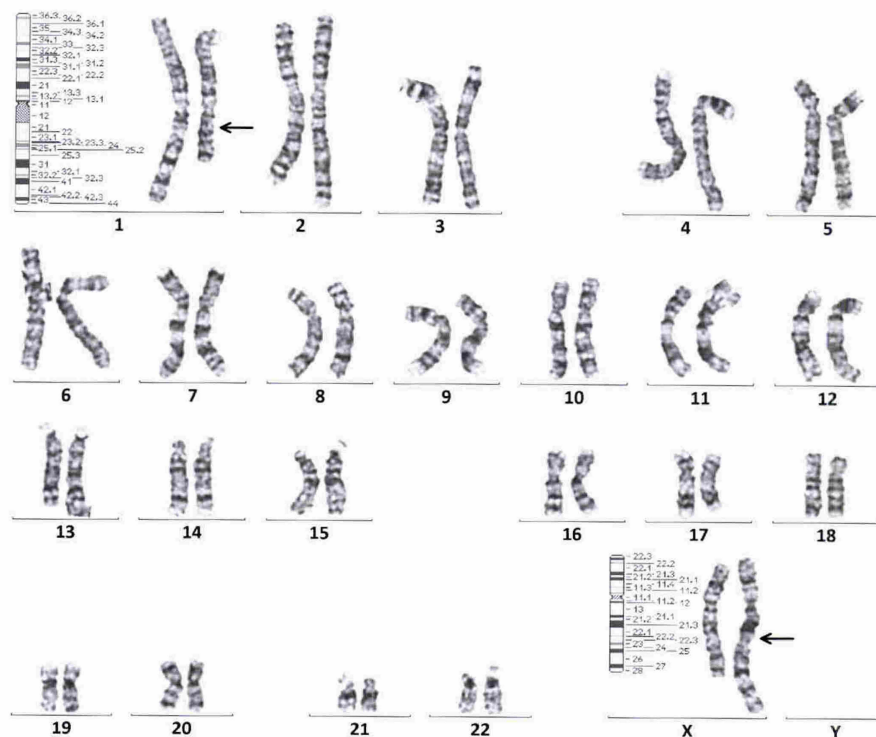
## Introduction

Gonadoblastoma is a rare ovarian tumor derived from the sex cord cells. In particular, it is associated with malignant germ cell tumors and accounts for <5% of all malignant ovarian tumors.<sup>1</sup> In most cases, gonadoblastoma is related to dysplasia of the Y chromosome.<sup>2</sup> However, rare cases of gonadoblastoma in young women without the Y chromosome have been reported.<sup>3–20</sup>

We report a case of dysgerminoma in a young woman with balanced translocation of the X chromosome without Y chromosome mosaicism, and discuss the causes of this disease and a literature review.

## Case Report

A 22-year-old nulliparous woman was admitted to our hospital. At the age of 15 years, she was referred to our hospital because of primary amenorrhea. She was not of short stature, with height 1.59 m and weight 49.5 kg, and body mass index 19.6 kg/m<sup>2</sup>. She had no abnormal findings in the limbs and neck. Her external genitalia were normal female type. Her vulva was of normal maturity, but no pubic or axillary hair was noted. Transabdominal ultrasound revealed an about 3 cm mass that appeared to be her uterus. Hormone assay were as follows: free triiodothyronine 5.14 (2.37–3.91) pg/ml, free thyroxine 1.79 (0.95–1.57) ng/dL, thyroid-stimulating hormone 0.011 (0.48–5.08) μIU/ml, luteinizing hormone 36.54 mIU/ml, follicle-stimulating hormone 89.34 mIU/ml, prolactin 6.64 ng/ml, estradiol <5.0 pg/ml, and progesterone 0.23 ng/ml. Her karyotyping was balanced translocation, 46X,t(X:1)(q22;q21) (Figure 1). She was diagnosed with primary amenorrhea caused by balanced translocation, 46X,t(X:1)(q22;q21), and she received estrogen and progestin replacement therapy for 7 years. During that period, she had regular menstrual cycles. When she was 22 years old, she visited a primary care physician because of lower abdominal distension. A pelvic tumor of ~12 cm was detected and she was referred to our department for further examination of the tumor. Her complete blood count and biochemical



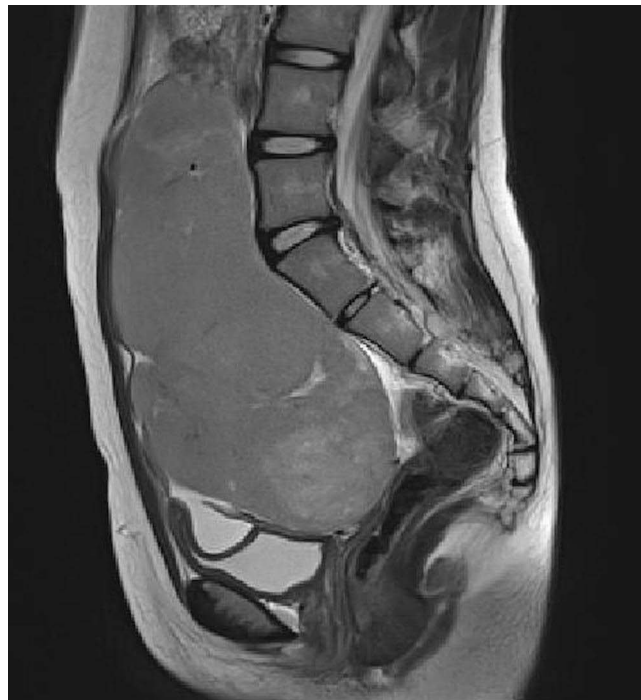**Figure 1** Chromosome banding of the patient showed balanced translocation 46X,t(X:1)(q22;q21) without the Y chromosome.

examination were as follows: white blood cell count 2600 (3300–8600)/ $\mu$ L (Segments 42%, lymphocytes 39.2%, eosinophils 2.4%, monocytes 9.8%, basophils 0.4%); hemoglobin 11.5 (11.6–14.8) g/dl; D-dimer 7.0  $\mu$ g/ml; lactate dehydrogenase 2070 (124–222) U/L; soluble interleukin-2 receptor 1, 122 (121–613) U/ml; carbohydrate antigen 125 68.1 ( $\leq$ 35.0) U/ml; carbohydrate antigen 19–9 9.6 ( $\leq$ 37.0) U/ml; carcinoembryonic antigen 0.3 ( $\leq$ 5.0) ng/ml; estradiol 35.9 pg/ml; prostaglandin 0.07 ng/ml; testosterone 21.5 ng/dl;  $\alpha$ -fetoprotein 2.0 ng/ml; and human chorionic gonadotropin (hCG)- $\beta$  113 mIU/ml.

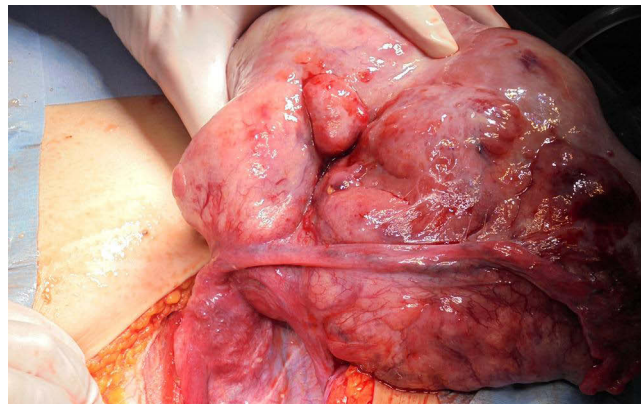
A large tumor was detected in the pelvis by magnetic resonance imaging. The tumor had a high signal on T2-weighted imaging (Figure 2), low signal on T1-weighted imaging, and decreased diffusing capacity on diffusion-weighted imaging. Para-aortic lymph node swelling was suspected by computed tomography. Because of the elevated lactate dehydrogenase and hCG- $\beta$ , imaging findings, and the patient's age, we suspected a malignant germ cell tumor, especially dysgerminoma, and performed left salpingo-oophorectomy and partial omentectomy. A small uterus and 18-cm solid tumor of the left ovary were detected during the operation (Figure 3). The right fallopian tube was normal, but the right ovary was not detected. The histopathological diagnosis of the left ovarian tumor was dysgerminoma (Figure 4), International Federation of Gynecology and Obstetrics (FIGO) stage IIIA1, pT3aN0M0 (positive ascites cytology and metastasis of the greater omentum). The removed ovarian tumor specimen was strongly positive when stained for c-kit (Figure 5). The patient was treated postoperatively with four courses of chemotherapy with bleomycin (20 mg/m<sup>2</sup>), etoposide (100 mg/m<sup>2</sup>) and cisplatin (20 mg/m<sup>2</sup>) for FIGO stage IIIA1 dysgerminoma. Post-chemotherapy imaging showed lymph node shrinkage and a decrease in hCG- $\beta$  to 1.6 mIU/ml.

## Discussion

Gonadoblastoma is a rare ovarian tumor derived from the sex cord cells. It occurs in young women with a mean age of 18 years,<sup>21</sup> and some cases have been detected during pregnancy.<sup>22</sup> In particular, it is associated with malignant germ cell tumors, and accounts for <less than 5% of all malignant ovarian tumors.<sup>1</sup>



**Figure 2** Preoperative pelvic magnetic resonance imaging revealed an 18-cm bifurcated mass with high signal intensity on T2-weighted imaging.

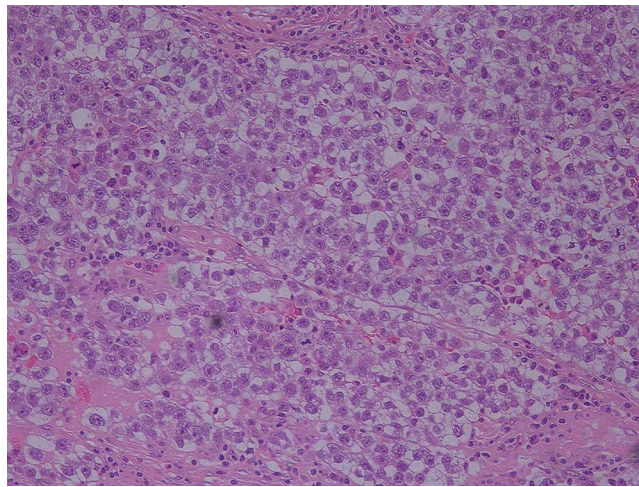


**Figure 3** A small uterus and 18-cm solid tumor in the left ovary were detected intraoperatively. The right fallopian tube was normal, but the right ovary was not detected.

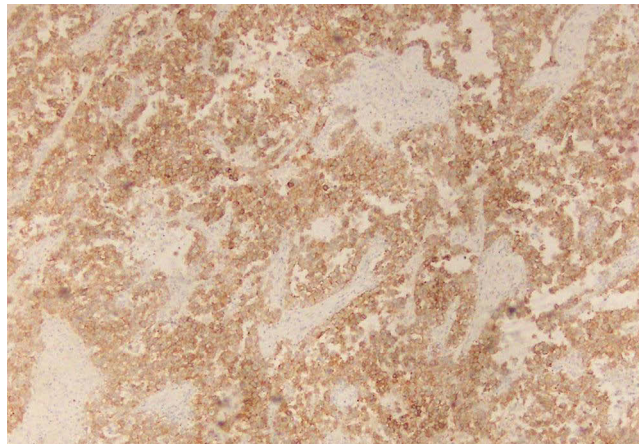
Dysgerminoma is the most common malignant germ cell tumor of the ovaries.<sup>23–27</sup> Dysgerminoma occurs in adolescents and young women and is bilateral in 10–15% of cases.<sup>25,26</sup> Fertility-sparing surgery is considered to have no effect on prognosis, and unilateral salpingo-oophorectomy and early postoperative chemotherapy are recommended.<sup>28</sup> Clinical trials in patients with malignant germ cell tumors have shown that BEP (Bleomycin, Etoposide, and Cisplatin) is the standard regimen for chemotherapy, with response rates as high as 100% in early-stage cases and 75% in advanced cases.<sup>29</sup>

In most cases, gonadoblastoma is related to Y chromosome dysplasia.<sup>2,30</sup> The risk of developing gonadal malignancy in patients with 46,XY is reported to be 15–45%, whereas the risk is 15–40% in patients with 45,X/46,XY and other chromosomal variants.<sup>31–34</sup> Most of the patients with 45X/46XY mosaicism who have streak gonads need early prophylactic gonadectomy to avoid developing a malignant tumor, including dysgerminoma.<sup>35</sup>

However, rare cases of dysgerminoma in phenotypically normal females have been reported, and to the best of our knowledge, only 18 cases have been reported.<sup>3–21</sup> As examples of cases of dysgerminoma without the Y chromosome



**Figure 4** Histopathological diagnosis was dysgerminoma in the left ovary. Large round cells proliferated like a solid nest with lymphocytic infiltration in the stroma. The cell borders were clear and round with enlarged nuclei, clear cytoplasm, and coarse chromatin staining.



**Figure 5** The ovarian tumor was stained strongly with c-kit.

except for phenotypically normal female, dysgerminoma in Turner syndrome patients without the Y chromosome has also been reported.<sup>36</sup> The majority of chromosome karyotypes in Turner syndrome are 45X, X chromosome monosomy.<sup>37</sup> The factors related to the phenotype of Turner syndrome patients are short stature homeobox-containing gene on Xp22<sup>38</sup> and Xp-, Yp- homologous lymphogenic genes.<sup>39</sup> Most previous cases of dysgerminoma and Turner syndrome have had Y chromosome mosaicism. It has been reported that 12% of Turner syndrome patients with Y chromosome mosaicism develop gonadoblastoma or malignant germ cell tumor, which is an indication for prophylactic gonadectomy.<sup>40</sup> Cools et al have reported that 1% of Turner syndrome patients without Y chromosome mosaicism also develop gonadoblastoma or malignant germ cell tumor.<sup>7</sup>

Kit gene mutations may be involved in the mechanism by which dysgerminoma develops in patients without the Y chromosome.<sup>25,26,34</sup> C-kit is a tyrosine kinase receptor, which is significant growth factor receptor for normal germ cell migration and development, and is expressed in dysgerminoma.<sup>25,26,41</sup> Cheng et al reported that kit amplification occurred in 27% of dysgerminomas, and that kit mutations occurred in more than one-third of dysgerminomas, especially in advanced cases.<sup>26</sup>

Our case had balanced translocation of X chromosome 46X,t(X:1)(q22;q21), which means translocation of q22 in chromosome X and q21 in chromosome 1. The fact that our patient's chromosomal type was balanced translocation and place of translocation was the long arm might be related to her normal phenotype. The resected ovarian tumor specimen

was strongly positive when stained for c-kit (Figure 5), suggesting that c-kit mutation was involved in the development of dysgerminoma in this case without the Y chromosome.

Only a few studies about the relationship between c-kit mutation and dysgerminomas have been reported.<sup>26,30,31,36,41</sup> It is important to accumulate case reports to further elucidate the mechanism of dysgerminoma.

In conclusion, patients diagnosed with primary amenorrhea may develop an ovarian tumor depending on their chromosomal karyotype or somatic gene mutation; therefore, gynecologists should provide hormone replacement therapy and periodic pelvic evaluation.

## Ethics Approval and Informed Consent

The case report involving a human participant was reviewed and approved by the Ethics committee of Nagasaki University Hospital, Nagasaki, Japan. After the patient has completed treatment at our hospital, she was followed at a medical facility in another prefecture. Therefore, the phone call to the patient, in which she provided verbal informed consent for the case details and images to be published was witnessed, and the contents were recorded in the patient's medical records. The date and facility where the examination or treatment was performed are not stated, and numbers included in pathological tests and imaging tests are omitted, so that individuals cannot be identified by test results or treatment details.

## Acknowledgments

We thank Cathel Kerr, BSc, PhD from Edanz Group for editing a draft of this manuscript.

## Disclosure

The authors declare that the research was conducted in the absence of any commercial or financial relationships that could be construed as a potential conflict of interest.

## References

1. Parker SL, Tong T, Bolden S, et al. Cancer statistics, 1997. *CA Cancer J Clin*. 1997;47(1):5–27. doi:10.3322/canjclin.47.1.5
2. Kildal W, Kraggerud SM, Abeler VM, et al. Genome profiles of bilateral dysgerminomas, a unilateral gonadoblastoma, and a metastasis from a 46, XY phenotypic female. *Hum Pathol*. 2003;34(9):946–949. doi:10.1016/S0046-8177(03)00345-9
3. Raafey MA, Abdulwaasey M, Fatima SS, et al. Bilateral gonadoblastoma with dysgerminoma in a phenotypically normal female with 46XX karyotype: report of a rare case and literature review. *Cureus*. 2020;12(7):e8990. doi:10.7759/cureus.8990
4. Krawczyk MA, Styczewska M, Birkholz-Walerzak D, et al. Bilateral ovarian germ cell tumor in a 46, XX female with Nijmegen Breakage syndrome and hypergonadotropic hypogonadism. *J Clin Res Pediatr Endocrinol*. 2022;14(2):251–257. doi:10.4274/jcrpe.galenos.2021.2021.0151
5. Yilmaz B, Gungor T, Bayramoglu H, et al. Bilateral ovarian gonadoblastoma with coexisting dysgerminoma in a girl with 46,XX karyotype. *J Obstetr Gynaecol Res*. 2010;36(3):697–700. doi:10.1111/j.1447-0756.2010.01225.x
6. McCuaig Jeanna M, Abdul N, Barry R, et al. Case report: use of tumor and germline Y chromosomal analysis to guide surgical management in a 46,XX female presenting with gonadoblastoma with dysgerminoma. *Int J Gyne Pathol*. 2017;36(5):466–470. doi:10.1097/PGP.0000000000000349
7. Lawrence R, Mary D, Bernard C, et al. Classic and ‘Dissecting’ gonadoblastoma in a phenotypical girl with a 46,XX peripheral karyotype and no evidence of a disorder of sex development. *Int J Gyne Pathol*. 2019;38(6):581–587. doi:10.1097/PGP.0000000000000551
8. Jung H, Yun BS, Jung YY, et al. Dissecting gonadoblastoma of the ovary coexistent with an atypical endometriotic cyst: incidental detection in cystectomy specimen of a woman with 46,XX karyotype. *Diagnostics*. 2022;12:660. doi:10.3390/diagnostics12030660
9. Erhan Y, Toprak AS, Ozdemir N, et al. Gonadoblastoma and fertility. *J Clin Pathol*. 1992;45:828–829. doi:10.1136/jcp.45.9.828
10. Kim M-J, Ahn H-J, Kim J-Y, et al. Gonadoblastoma overgrown by dysgerminoma in women with 46,XX karyotype- A report of two cases. *Korean J Pathol*. 2003;37:66–70.
11. Chandrapattan P, Jena A, Patnayak R, et al. Gonadoblastoma with dysgerminoma presenting as virilizing disorder in a young child with 46,XX karyotype: a case report and review of the literature. *Case Rep Endocrinol*. 2022;6:5666957.
12. Esin S, Baser E, Kucukozkan T, et al. Ovarian gonadoblastoma with dysgerminoma in a 15-year-old girl with 46,XX karyotype: case report and review of the literature. *Arch Gynecol Obstet*. 2012;285:447–451. doi:10.1007/s00404-011-2073-9
13. Kanagal D, Prasad K, Rajesh A, et al. Ovarian gonadoblastoma with dysgerminoma in a young girl with 46,XX karyotype: a case report. *J Clin Diagn Res*. 2013;7(9):2021–2022. doi:10.7860/JCDR/2013/6412.3393
14. Pang S, Zhang L, Shi Y, et al. Unclassified mixed germ cell-sex cord-stromal tumor with multiple malignant cellular elements in a young woman: a case report and review of the literature. *Int J Clin Exp Pathol*. 2014;7(8):5259–5266.
15. Koo Y-J, Chun Y-K, Kwon Y-S, et al. Ovarian gonadoblastoma with dysgerminoma in a woman with 46XX karyotype. *Pathol Int*. 2011;61(3):171–173. doi:10.1111/j.1440-1827.2010.02636.x
16. Obata NH, Nakashima N, Kawai M, et al. Gonadoblastoma with dysgerminoma in one ovary and gonadoblastoma with dysgerminoma and York sac tumor in the contralateral ovary in a girl with 46XX karyotype. *Gynecol Oncol*. 1995;58(1):124–128. doi:10.1006/gyno.1995.1195

17. Baron J, Warenik-Szymankiewica A, Miedzianowski J, et al. New aspects of diagnosing and treating pure gonadal dysgenesis 46XY and 46XX. *Endokrynol Pol.* 1993;44(4):483–496.
18. Elemenoglou J, Korkolopoulou P, Zizi A, et al. A case of gonadoblastoma in a normal woman with tubal pregnancy. *Arch Geschwulstforsch.* 1990;60(3):223–226.
19. Talerman A, van der Harten JJ. Mixed germ cell-sex cord stroma tumor of the ovary associated with isosexual precocious puberty in a normal girl. *Cancer.* 1977;40(2):889–894. doi:10.1002/1097-0142(197708)40:2<889::AID-CNCR2820400244>3.0.CO;2-0
20. Pratt-Thomas HR, Cooper JM. Gonadoblastoma with tubal pregnancy. *Am J Clin Pathol.* 1976;65(1):121–125. doi:10.1093/ajcp/65.1.121
21. Prat J, Cao D, Carinelli SJ, et al. Germ cell-sex cord-stromal tumors. In: *WHO Classification of Tumours of Female Reproductive System.* 4th ed. Lyon, France: International Agency for Research on Cancer Press; 2014:67–68.
22. Albrektsen G, Heuch I, Kvale G. Full-term pregnancies and incidence of ovarian cancer of stromal and germ cell origin: a Norwegian prospective study. *Br J Cancer.* 1997;75(5):767–770. doi:10.1038/bjc.1997.136
23. Scully RE, Young RH, Clement PB. Tumors of the ovary, maldeveloped gonads, fallopian tube and broad ligament. *Armed Forces Inst Pathol.* 1998;189(1):145.
24. Cheng L, Thomas A, Roth LM, Zheng W, Michael H, Karim FWA. OCT4: a novel biomarker for dysgerminoma of the ovary. *Am J Surg Pathol.* 2004;28(10):1341–1346. doi:10.1097/01.pas.0000135528.03942.1f
25. Roth LM, Talerman A. Recent advances in the pathology and classification of ovarian germ cell tumors. *Int J Gynecol Pathol.* 2006;25(4):305–320. doi:10.1097/01.pgp.0000225844.59621.9d
26. Cheng L, Roth LM, Zhang S, et al. KIT gene mutation and amplification in dysgerminoma of the ovary. *Cancer.* 2011;2011:2096–2103.
27. Pectasides D, Pectasides E, Kassanos D. Germ cell tumors of the ovary. *Cancer Treat Rev.* 2018;34(5):427–441. doi:10.1016/j.ctrv.2008.02.002
28. National cancer institute. NCI ovarian germ cell tumors treatment (PDQ) health professional version (05/22/2008). Available from: <https://www.cancer.gov/types/ovarian/hp/ovarian-germ-cell-treatment-pdq>. Accessed 06 March 2023.
29. Williams S, Blessing JA, Liao SY, et al. Adjuvant therapy of ovarian germ cell tumors with cisplatin, etoposide, and bleomycin: a trial of the Gynecologic Oncology Group. *J Clin Oncol.* 1994;12(4):701–706. doi:10.1200/JCO.1994.12.4.701
30. Vandembark GR, deCastro CM, Taylor H, et al. Cloning and structural analysis of the human c-kit gene. *Oncogene.* 1992;7(7):1259–1266.
31. Cools M, Drop SLS, Wolffenbuttel KP, et al. Germ cell tumors in the intersex gonad: old paths, new directions, moving frontiers. *Endocr Rev.* 2006;27(5):468–484. doi:10.1210/er.2006-0005
32. Pleskacova J, Hersmus R, Oosterhuis JW, et al. Tumor risk in disorders of sex development. *Sex Dev.* 2010;4(4–5):259–269. doi:10.1159/000314536
33. Rocha VBC, Guerra-Júnior G, Marques-de-Faria AP, de Mello MP, Maciel-Guerra AT. Complete gonadal dysgenesis in clinical practice: the 46, XY karyotype accounts for more than one third of cases. *Fertil Steril.* 2011;96(6):1431–1434. doi:10.1016/j.fertnstert.2011.09.009
34. Michala L, Goswami D, Creighton SM, et al. Swyer syndrome: presentation and outcomes. *BJOG.* 2008;115(6):737–741. doi:10.1111/j.1471-0528.2008.01703.x
35. Haddad NG, Walvoord EC, Cain MP, et al. Seminoma and a gonadoblastoma in an infant with mixed gonadal dysgenesis. *J Pediatr.* 2003;143(1):136. doi:10.1016/S0022-3476(03)00132-X
36. Gawrychowska A, Izycka-świeszewska E, Lipska-Ziętkiewicz BS. Dysgerminoma with a somatic exon 17 KIT mutation and SHH pathway activation in a girl with Turner syndrome. *Diagnostics.* 2020;10(12):1067. doi:10.3390/diagnostics10121067
37. Maeda T, Ohno M, Matsunobu A, et al. A cytogenetic survey of 14,835 consecutive liveborns. *Jpn J Hum Genet.* 1991;36(1):117–129. doi:10.1007/BF01876812
38. Rao E, Weiss B, Fukami M, et al. Pseudoautosomal deletions encompassing a novel homeobox gene cause growth failure in idiopathic short stature and Turner syndrome. *Nat Genet.* 1997;16(1):54–63. doi:10.1038/ng0597-54
39. Ogata T, Matsuo N. Turner syndrome and female sex chromosome aberrations: deduction of the principal factors involved in the development of clinical features. *Hum Genet.* 1995;95(6):607–629. doi:10.1007/BF00209476
40. Lee PA, Houk CP, Ahmed SF, et al. Consensus statement on management of intersex disorders. *Pediatrics.* 2006;118:e488. doi:10.1542/peds.2006-0738
41. Tian Q, Frierson HF, Krystal GW, et al. Activating c-kit gene mutations in human germ cell tumors. *Am J Pathol.* 1999;154(6):1643–1647. doi:10.1016/S0002-9440(10)65419-3

International Medical Case Reports Journal

Dovepress

Publish your work in this journal

The International Medical Case Reports Journal is an international, peer-reviewed open-access journal publishing original case reports from all medical specialties. Previously unpublished medical posters are also accepted relating to any area of clinical or preclinical science. Submissions should not normally exceed 2,000 words or 4 published pages including figures, diagrams and references. The manuscript management system is completely online and includes a very quick and fair peer-review system, which is all easy to use. Visit <http://www.dovepress.com/testimonials.php> to read real quotes from published authors.

Submit your manuscript here: <https://www.dovepress.com/international-medical-case-reports-journal-journal>