

1 **Effect of anti-angiogenesis induced by chemotherapeutic monotherapy,**
2 **chemotherapeutic/bisphosphonate combination therapy and anti-VEGFA**
3 **mAb therapy on tooth extraction socket healing in mice**

4 Yuri Akita¹, Shinichiro Kuroshima^{1,2, *}, Kazunori Nakajima¹, Hiroki Hayano¹, Riho Kanai¹,
5 Muneteru Sasaki¹, Takashi Sawase¹

6 ¹ Department of Applied Prosthodontics, Graduate School of Biomedical Sciences, Nagasaki
7 University, 1-7-1, Sakamoto, Nagasaki, 852-8588, Japan

8 ² Oral & Maxillofacial Implant Center, Nagasaki University Hospital, 1-7-1, Sakamoto, Nagasaki,
9 852-8588, Japan

10

11 **Yuri Akita and Shinichiro Kuroshima contributed equally to this work.**

12

13

14 *Corresponding author and person to whom reprints should be addressed:*

15 Shinichiro Kuroshima, D.D.S, Ph.D

16 Department of Applied Prosthodontics, Graduate School of Biomedical Sciences, Nagasaki
17 University, 1-7-1, Sakamoto, Nagasaki, 852-8588, Japan.

18 Oral & Maxillofacial Implant Center, Nagasaki University Hospital, 1-7-1, Sakamoto, Nagasaki,
19 852-8588, Japan.

20 Phone: +81-95-819-7685.

21 Fax: +81-95-819-7689.

22 e-mail: kuroshima@nagasaki-u.ac.jp

23

24 **Keywords:** bisphosphonate, chemotherapy, blood vessels, osteonecrosis of the jaw, angiogenesis

25

26

1 **Abstract**

2 Osteonecrosis of the jaw (ONJ), which is a rare but severe adverse effect, mainly occurs in
3 oncology patients receiving chemotherapeutic agents and bisphosphonates. However, the combined
4 impact of chemotherapy and bisphosphonates on wound healing after tooth extraction remains
5 unknown. The aim of this study was to determine the precise etiology of ONJ induced by
6 chemotherapy and bisphosphonate combination therapy. Mice received zoledronate (ZA)
7 monotherapy, cyclophosphamide (CY) monotherapy, or CY/ZA combination therapy. The
8 maxillary first molars were extracted 3 weeks after the initiation of drug treatment. Moreover, anti-
9 vascular endothelial growth factor A (VEGFA) monoclonal antibody (mAb) was administered once
10 every 2 days just after tooth extraction for 2 weeks. Soft and hard tissue wound healing were
11 evaluated 2 and 4 weeks post-extraction using histomorphometry, microcomputed tomography, and
12 immunohistochemistry. ZA monotherapy did not induce impaired oral wound healing and ONJ-like
13 lesions 2 and 4 weeks post-extraction, respectively. Tooth extraction socket healing worsened with
14 severe anti-angiogenesis by CY monotherapy and CY/ZA combination therapy 2 weeks post-
15 extraction. However, CY monotherapy rarely induced ONJ-like lesions with severe angiogenesis
16 suppression, whereas CY/ZA combination therapy frequently induced ONJ-like lesions with severe
17 angiogenesis inhibition 4 weeks post-extraction. Interestingly, anti-VEGFA mAb therapy delayed
18 osseous wound healing with normal soft tissue wound healing of tooth extraction sockets, although
19 this therapy significantly suppressed blood vessel formation. Our findings suggest that anti-
20 angiogenesis alone is not the main cause of ONJ-like lesions induced by CY/ZA combination
21 therapy. The combination of suppressed osteoclasts and anti-angiogenesis, in addition to other risk
22 factors such as chemotherapy, may contribute to the development of ONJ.

23

24

25

1 **Introduction**

2 Osteonecrosis of the jaw (ONJ), which was first reported as “avascular necrosis of the jaws”
3 [1], is a rare but severe adverse effect observed in patients taking antiresorptive drugs such as
4 bisphosphonates and anti-receptor activator of nuclear factor kappa-B ligand antibody (denosumab)
5 [2,3]. Recently, medication-related ONJ has been proposed in place of antiresorptive-related ONJ
6 since anti-angiogenic agents such as bevacizumab also induced ONJ in oncology patients, although
7 these patients have other risk factors such as chemotherapy and steroid therapy use [2]. ONJ
8 significantly increases the Oral Health Impact Profile, resulting in a decreased patient oral health-
9 related quality of life due to difficulty in receiving optimal dental treatments [4]. Approximately
10 70% of ONJ patients have received tooth extractions [3]. Tooth extraction injures soft and hard
11 tissues with open wounds. Normally, wound repair occurs with new bone formation in extraction
12 sockets and wound closure by soft tissue regeneration. Blood vessel formation is an essential factor
13 in recruiting immune cells including polymorphonuclear cells (PMNs) and supporting bone
14 formation and soft tissue reconstruction during healing processes. Several vascular endothelial
15 growth factors (VEGFs), which are produced by macrophages, dendritic cells, fibroblasts,
16 osteoblasts, and endothelial cells, are required for angiogenesis in wounds. Studies have reported
17 that bisphosphonates inhibit blood vessel formation [5,6], suggesting that angiogenesis suppression
18 by bisphosphonates is a pathoetiology of ONJ. However, some reports have indicated that
19 bisphosphonate therapy does not suppress angiogenesis in oral wounds [7-10]. Moreover, it has not
20 been reported that denosumab inhibits angiogenesis [3], although both bisphosphonates and
21 denosumab cause the same pathophysiology in ONJ. Therefore, it remains controversial whether
22 angiogenesis suppression is a crucial factor in inducing ONJ following tooth extraction.

23 ONJ primarily occurs in malignant patients taking not only antiresorptive drugs or anti-
24 angiogenic agents, but also one or more chemotherapeutic drugs [3]. Chemotherapy, which has
25 been widely used for malignancies, is one of the risk factors for ONJ [2]. In particular, ONJ

1 develops most commonly in multiple myeloma patients who receive alkylating agents and
2 zoledronate combination therapy [11]. Alkylating agents, which are prescribed for multiple
3 myeloma, bind to DNA and prevent proper DNA replication, resulting in cancer cell death [12].
4 Alkylating agents also induce adverse effects because they cause serious damage in both cancer
5 cells and normal cells. However, whether alkylating agents affect soft and hard tissue wound
6 healing following tooth extraction remains unknown. Moreover, the mechanisms by which
7 antiresorptive and chemotherapeutic combination therapy contribute to the development of ONJ
8 remain unclear, although many clinical studies have reported that chemotherapeutic agents and
9 bisphosphonate and/or denosumab combination therapies induced ONJ following tooth extraction.
10 Therefore, the aim of this study was to investigate the combined effect of chemotherapy and
11 bisphosphonate therapy on soft and hard tissue wound healing following tooth extraction to
12 elucidate the pathophysiology of ONJ.

13

14 **Materials and methods**

15 **Animals, tooth extraction, and bisphosphonate therapy and chemotherapy**

16 Male C57BL/6J mice (9-week-old; CLEA Japan Inc., Osaka, Japan) were randomly
17 divided into three treatment groups and one control group (four groups total). Mice were
18 subcutaneously administered zoledronate (Zometa, Novartis, Stein, Switzerland) at 0.05 mg/kg
19 twice a week (designated as ZA, n = 7) [8]. Mice were intraperitoneally injected with 150 mg/kg of
20 cyclophosphamide (C7397, Sigma-Aldrich, St. Louis, MO, USA) twice a week before tooth
21 extraction and once a week post-extraction (designated as CY, n = 7). Mice received combination
22 treatment of intraperitoneal CY (150 mg/kg twice a week before extraction and once a week post-
23 extraction) and subcutaneous ZA (0.05 mg/kg twice a week) (designated as CY/ZA, n = 7). Saline
24 was used as a control (vehicle control; designated as VC, n = 7). Three weeks after the initiation of
25 drug therapy, both maxillary first molars were extracted. Mice were euthanized 2 and 4 weeks post-

1 extraction (Fig. 1a, b). Animal care and experimental procedures were performed in accordance
2 with the Guidelines for Animal Experimentation of Nagasaki University, with approval from the
3 Ethics Committee for Animal Research

4 **Anti-vascular endothelial growth factor A (VEGFA) monoclonal antibody (mAb) therapy**

5 To investigate the net effect of anti-angiogenesis on tooth extraction wound healing, anti-
6 VEGFA mAb therapy was carried out. Female C57BL/6J mice (8-week-old; CLEA Japan Inc.)
7 were used. Mice (n = 4) received 100 µg of anti-VEGFA mAb (clone 2G11-2A05; BioLegend, San
8 Diego, CA, USA) intraperitoneally once every 2 days for 2 weeks [13] just after extraction of both
9 maxillary first molars. Intraperitoneal injection of an equivalent volume of rat IgG2a (BLD-400516;
10 BioLegend, San Diego, CA, USA) was also performed as a control (n = 4). Euthanasia was
11 performed 2 weeks post-extraction.

12 **Microcomputed tomography (microCT)**

13 Right maxillae were dissected 2 and 4 weeks after tooth extraction, fixed in 10% neutral
14 buffered formalin for 24 hours, and visualized using microCT at 20-µm voxel resolution and 90-kV
15 tube voltage (R_mCT2, Rigaku Co. Ltd., Tokyo, Japan) [14]. Extraction sockets were segmented
16 and reconstructed using a semi-manual contouring method [15] with TRI/3D-Bon (Ratoc System
17 Engineering, Tokyo, Japan). In tooth extraction sockets, bone fill of sockets (bone volume/tissue
18 volume, BV/TV), trabecular number (Tb.N), trabecular thickness (Tb.Th), trabecular separation
19 (Tb.Sp), and bone mineral density (BMD) were semi-automatically measured in accordance with
20 the guidelines for assessment of bone microstructures using microCT [16].

21 **Histomorphometric analysis of oral wound healing**

22 Hematoxylin and eosin (H-E) staining was performed using a standard staining protocol
23 to evaluate soft and hard tissues. Left maxillae were dissected 2 and 4 weeks after tooth extraction
24 and fixed in 10% neutral formalin at euthanasia. Maxillary bones were demineralized in 10%

1 EDTA, paraffin embedded, and sectioned at 5- μ m thickness in serial sagittal sections. Tartrate-
2 resistant acid phosphatase (TRAP) staining and Masson's trichrome staining were conducted to
3 visualize osteoclasts and collagen fibers, respectively, with commercial kits following the
4 manufacturer's instructions (HT15 and 386A, respectively; Sigma-Aldrich). The bones in tooth
5 extractions were then histomorphometrically assessed to detect the following: 1) osteoclast number
6 per bone surface (osteoclast perimeter) (OC.N/BS, #/mm); 2) living bone area (%); 3) necrotic bone
7 area (%); 4) number of empty lacunae (#/mm²); 5) osteocyte numbers (#/mm²); 6) collagen area
8 (%); and 7) PMN infiltration (#/mm²). Collagen fibers were quantified in the connective tissue [area
9 of interest (AOI), 200 μ m \times 500 μ m] above extraction sockets. PMN infiltration was assessed by
10 quantifying the number of inflammatory cells in the connective tissue within 100 μ m of the bone
11 surface (AOI, 100 μ m \times 500 μ m). Necrotic bone was defined as the portion of bone in which there
12 was \geq 10 adjacent empty or pyknotic osteocyte lacunae, since such bone is not vital [8,17].

13 **Immunohistochemical analyses**

14 Immunofluorescent staining was performed to visualize blood vessels as follows. Sections
15 were fixed, dehydrated, subjected to antigen retrieval, and blocked with nonspecific protein.
16 Sections were then incubated with a CD31 rabbit anti-mouse primary antibody (1:100 dilution;
17 ab56299, Abcam, Cambridge, MA, USA) overnight at 4°C. Fluorescent-conjugated goat anti-rat
18 Alexa Flour 594 (1:200 dilution; Invitrogen, Carlsbad, CA, USA) was used as the secondary
19 antibody. VECTASHIELD Antifade Mounting Medium with DAPI (H-1200 Vector Laboratories,
20 Burlingame, CA, USA) was also used. Stained sections were visualized using immunofluorescent
21 microscopy (Axio Scope A1, Zeiss, Oberkochen, Germany). Blood vessel numbers and areas were
22 quantitatively analyzed by semiautomatically counting the number and area of vessels in the
23 connective tissue above extraction sockets (AOI, 200 μ m \times 500 μ m) to evaluate blood vessel
24 formation, as previously described [7-9].

25 **Statistics**

1 Statistical analyses were blindly conducted. The Shapiro-Wilk test was performed to assess
2 normality. In the comparison of four groups (VC, CY, ZA, and CY/ZA), one-way analysis of
3 variance and the Kruskal-Wallis test were used for parametric and non-parametric data, respectively.
4 In the comparison between IgG2a and mAb groups, Student's *t*-test and the Mann-Whitney *U*-test
5 were used for parametric and non-parametric data, respectively. All statistical analyses were
6 conducted using Systat 12 (Systat Software, Chicago, IL, USA). An α -level of 0.05 was used for
7 statistical significance. All data are presented as mean \pm SEM.

8

9 **Results**

10 **Effect of administered drugs on gross wound healing in tooth extraction sockets**

11 Open wounds were observed in CY (9 of 14 extraction sockets) and CY/ZA (14 of 14
12 extraction sockets) 2 weeks post-extraction (Fig. 2a, b). Indeed, CY monotherapy and CY/ZA
13 combination therapy significantly increased the open wound area in tooth extraction sockets,
14 although the wound area was significantly larger in CY/ZA compared with CY (Fig. 2c).
15 Conversely, open wounds were frequently observed in CY/ZA (13 of 14 extraction sockets) 4
16 weeks post-extraction, whereas wounds were almost covered by epithelium in CY (1 of 14
17 extraction sockets) (Fig. 2d, e). The open wound area was significantly larger in CY/ZA compared
18 with all other groups 4 weeks post-extraction (Fig. 2f). Sustained exposed bones with open wounds
19 for 8 successive weeks is one of the definitions of ONJ [2,3]. Hence, exposed bones with open
20 wounds for 4 successive weeks were designated as ONJ-like lesions in this study. Exposed bones
21 with open wounds for 2 weeks were designated as impaired wound healing of tooth extraction in the
22 present study.

23 **Effect of administered drugs on osseous wound healing in tooth extraction sockets**

24 Osseous wound healing of tooth extraction sockets seemed to be impaired in CY and
25 CY/ZA, but not VC and ZA 2 weeks post-extraction (Fig. 3a). Indeed, CY monotherapy and

1 CY/ZA combination therapy significantly decreased bone fills in tooth extraction sockets with
2 decreased Tb.N, decreased Tb.Th and increased Tb.Sp, as compared with VC and ZA (Fig. 3b-e).
3 BMD in CY was significantly decreased compared with VC, while BMD in CY/ZA was the same
4 as VC (Fig. 3f).

5 Osseous wound healing of tooth extraction sockets appeared to be suppressed in CY and
6 CY/ZA 4 weeks post-extraction (Fig. 3g). CY/ZA combination therapy significantly suppressed
7 bone fill in tooth extraction sockets with decreased Tb.N, decreased Tb.Th, increased Tb.Sp, and
8 decreased BMD as compared with all other groups (Fig. 3h-l). CY monotherapy significantly
9 induced impaired osseous wound healing compared with VC and ZA. Osseous wound healing in
10 CY/ZA was significantly more impaired than that in CY (Fig. 3h-l).

11 **Effect of administered drugs on soft and hard tissue wound healing 2 weeks post-extraction**

12 Localized and extended open wounds were grossly detected in CY and CA/ZA,
13 respectively (Fig. 4a). ZA monotherapy and CY monotherapy for 5 weeks significantly suppressed
14 osteoclast numbers, even when CY/ZA combination therapy was administered (Fig. 4a, b). ZA
15 monotherapy, CY monotherapy, and CY/ZA combination therapy significantly decreased the living
16 bone area compared with VC (Fig. 4c). CY monotherapy and CY/ZA combination therapy
17 significantly increased the necrotic bone area and the number of empty lacunae compared with VC
18 and ZA monotherapy (Fig. 4d, e). Additionally, CY monotherapy and CY/ZA combination therapy
19 significantly decreased the number of osteocytes compared with VC (Fig. 4f). CY/ZA combination
20 therapy significantly suppressed collagen production compared with all other groups (Fig. 4g, h).
21 CY monotherapy and CY/ZA combination therapy significantly increased PMN infiltration,
22 although PMN infiltration in CY/ZA was severer than that in CY (Fig. 4g, i).

23 **Effect of administered drugs on soft and hard tissue wound healing 4 weeks post-extraction**

24 Open wounds were frequently observed following CY/ZA combination therapy but not VC,
25 ZA monotherapy, or CY monotherapy (Fig. 5a). ZA administration significantly suppressed

1 osteoclast numbers in tooth extraction sockets, irrespective of CY administration (Fig. 5a, b).
2 However, ZA monotherapy did not change the living bone area compared with VC (Fig. 5c).
3 CY/ZA combination therapy and CY monotherapy significantly decreased the living bone area in
4 extraction sockets compared with VC and ZA monotherapy (Fig. 5c). CY/ZA combination therapy
5 significantly increased the necrotic bone area compared with all other therapies (Fig. 5d). The
6 number of empty lacunae was the same between VC and ZA monotherapy, however, CY
7 monotherapy and CY/ZA combination therapy significantly increased the number of empty lacunae
8 compared with VC and ZA monotherapy (Fig. 5e). Additionally, CY monotherapy and CY/ZA
9 combination therapy significantly decreased the number of osteocytes compared with VC (Fig. 5f).
10 CY/ZA combination therapy significantly decreased collagen production and increased PMN
11 infiltration in soft tissues of tooth extraction sockets compared with VC, ZA monotherapy, and CY
12 monotherapy (Fig. 5g–i).

13 **Effect of administered drugs on blood vessels in the connective tissue of tooth extraction** 14 **sockets 2 and 4 weeks post-extraction**

15 Blood vessel formation was measured to compare the effect of CY monotherapy and
16 CY/ZA combination therapy. Surprisingly, CY monotherapy and CY/ZA combination therapy
17 significantly suppressed the number and area of blood vessels as compared with VC and ZA
18 monotherapy 2 weeks post-extraction (Fig. 6a–c). Interestingly, these anti-angiogenic effects by CY
19 monotherapy and CY/ZA combination therapy were significantly sustained until 4 weeks post-
20 extraction (Fig. 6d–f).

21 **Effect of anti-VEGFA mAb therapy on wound healing in tooth extraction sockets**

22 No open wounds were observed in both IgG2a and anti-VEGFA mAb 2 weeks post-
23 extraction (Fig. 7b, c). Anti-VEGFA mAb therapy significantly delayed bone formation of tooth
24 extraction sockets compared with IgG2a therapy, although the necrotic bone area and numbers of
25 empty lacunae and osteocytes were the same between groups (Fig. 7d–h). Conversely, collagen

1 production was the same between groups, although PMN infiltration was significantly increased in
2 anti-VEGFA mAb compared with IgG2a (Fig.7i–k). Anti-VEGFA mAb therapy significantly
3 suppressed the number of blood vessels without alteration of vessel surfaces (Fig. 7l–n).

4 5 **Discussion**

6 In the present study, we demonstrated that: 1) severe angiogenesis suppression by
7 alkylating chemotherapeutic agent CY alone is a not the definitive cause of ONJ-like lesions,
8 although CY monotherapy delayed osseous wound healing; 2) CY/ZA combination therapy
9 frequently induced ONJ-like lesions, although CY/ZA combination therapy also significantly
10 inhibited angiogenesis in the soft tissue of tooth extraction sockets; and 3) anti-VEGFA mAb
11 therapy delayed osseous wound healing but not soft tissue healing of tooth extraction sockets.

12 Chemotherapeutic agents, which are pivotal drugs for the treatment of malignancies, have
13 adverse effects on normal cells. The alkylating agent CY constitutes a major class of front-line
14 chemotherapeutic agents that inflict cytotoxic DNA damage as their mode of action. CY damages
15 both cancer cells and normal cells by inhibiting DNA replication [18]. To our knowledge, no
16 reports have focused on the effect of CY monotherapy on wound healing following tooth extraction.
17 Therefore, in this study, we investigated the effect of CY monotherapy on hard and soft tissue
18 wound healing following tooth extraction. CY monotherapy influenced osteoclasts and osteocytes
19 with decreased bone fill and decreased BMD after CY administration. This finding was partially in
20 accordance with that of a previous study, which demonstrated that weekly 20 mg/kg CY injections
21 for more than 5 weeks significantly decreased osteoblast and osteoclast numbers with bone loss in
22 rat mandibular condyles [19]. CY induces myelosuppression [20], suggesting that immune
23 responses may be influenced. Bacteremia may occur in up to 96% of cases following bacterial
24 invasion into extraction sockets [21,22]. Elimination of invasive bacteria in extraction sockets
25 supports wound closure. Network development of blood vessels in wound sites plays an important

1 role in accumulating neutrophils, osteoclast precursors, monocyte-macrophage lineages, and PMNs
2 during wound healing [23]. Neutrophils, PMNs, and monocyte-macrophage lineages fight invading
3 bacteria within soft tissue wounds, resulting in soft tissue regeneration [24,25]. In the current study,
4 the influence of CY on PMN infiltration and collagen production in the soft tissue of extraction
5 sockets decreased in a time-dependent manner, although CY significantly suppressed angiogenesis,
6 irrespective of administration duration. CY has been demonstrated to inhibit angiogenesis by
7 preventing endothelial cell growth through suppressed basic fibroblast growth factor expression *in*
8 *vitro* and *in vivo* [26]. Conversely, a recent study showed that CY metronomic chemotherapy,
9 which suppressed only angiogenesis without immune suppression, has been developed for use in
10 oncology patients [27,28]. Moreover, CY enhanced the recruitment of immune cells such as PMNs
11 and macrophages via high mobility group box 1 protein [29]. Therefore, our findings suggested that
12 CY monotherapy may specifically inhibit blood vessel formation, but not affect immune cells such
13 as PMNs. As a result, CY monotherapy rarely induced ONJ-like lesions with severe angiogenesis
14 suppression, although this therapy induced impaired osseous wound healing 2 and 4 weeks post-
15 extraction.

16 ONJ develops most commonly in malignant patients taking intravenous bisphosphonates
17 following tooth extraction with incidences ranging 1.6–14.8% [3]. Malignant patients may take
18 multiple chemotherapeutic agents simultaneously. Thus, we investigated the effect of ZA and CY
19 combination therapy on tooth extraction socket healing. First, the effect of ZA monotherapy was
20 examined. ZA is usually administered intravenously in humans. It has been demonstrated that
21 subcutaneous injection of ZA (0.1 mg/kg at 5 times for 20 days) improved the survival rate without
22 reducing the number of metastases in a murine prostate cancer bone metastasis model. This therapy
23 also significantly increased trabecular bone with the preservation of bone structures in long bones
24 [30]. These effects of subcutaneous ZA injection on tumor-bearing mice are comparable to those of
25 intravenous ZA injection. Hence, in this study, subcutaneous injection of ZA was applied to

1 C57B6/J mice. Interestingly, ZA monotherapy did not induce ONJ-like lesions with open wounds,
2 although ZA monotherapy affected soft and hard tissue wound healing 2 weeks, but not 4 weeks,
3 post-extraction. ZA did not affect the number of blood vessels, regardless of administration duration.
4 We previously demonstrated that ZA monotherapy did not suppress angiogenesis in the soft tissue
5 of extraction sockets during wound healing processes [8,9]. Thus, the present findings are in
6 agreement with our previous findings. Conversely, ZA has been demonstrated to have a negative
7 effect on cultured oral epithelial cells and fibroblasts [31]. Additionally, ZA had a negative
8 influence on cell viability of human umbilical vascular endothelial cells [32]. Short-term ZA
9 monotherapy (12 days) inhibited tooth extraction socket healing with inhibited angiogenesis 5 days
10 post-extraction [33], although the most recent study has demonstrated that subcutaneous
11 alendronate monotherapy did not suppress angiogenesis with normal wound healing 3, 5, 7, 10, and
12 21 days post-extraction [10]. International task force on ONJ also agrees with no anti-angiogenesis
13 with animal study using bisphosphonates [2]. However, ZA monotherapy actually suppressed
14 angiogenesis in cancer patients [34] and ONJ mainly occurs in malignant patients taking ZA.
15 Accordingly, ZA-induced anti-angiogenesis may not be an exact causative factor of BRONJ in
16 human, although inhibition of blood vessel formation by ZA monotherapy negatively affects the
17 early phase of wound healing processes following tooth extraction. Anti-angiogenesis induced by
18 ZA monotherapy may specifically occur at malignant sites but not at wound sites, such as soft
19 tissues of extraction sockets.

20 Next, we evaluated the effect of CY and ZA combination therapy. The effects of CY/ZA
21 combination therapy on tooth extraction wound healing significantly differed from that of ZA
22 monotherapy 2 and 4 weeks post-extraction. CY/ZA combination therapy severely impaired hard
23 tissue healing. Surprisingly, only 20% of bone fill in tooth extraction sockets was observed
24 following CY/ZA combination therapy even 4 weeks post-extraction. Open wounds frequently
25 remained with severely reduced collagen production and significant PMNs infiltration in soft tissue

1 wounds. As a result, CY/ZA combination therapy severely influenced soft and hard tissues of
2 extraction sockets, resulting in frequent induction of ONJ-like lesions. Moreover, angiogenesis
3 inhibition following CY monotherapy and CY/ZA combination therapy was almost the same. Thus,
4 our findings demonstrated that both CY and ZA are requisite for the development of ONJ-like
5 lesions in mice.

6 Finally, to address whether anti-angiogenesis is a critical factor in wound healing following
7 tooth extraction, we investigated the net effect of anti-angiogenesis on tooth extraction socket
8 healing at the early phase of wound healing processes using anti-VEGFA mAb. Blood vessels are
9 required for the recruitment of immune cells to tooth extraction sites, and bone formation and soft
10 tissue regeneration in the tooth extraction sockets. Hence, anti-VEGFA mAb therapy delayed
11 osseous wound healing of tooth extraction sockets. Other factors except for anti-angiogenesis may
12 induce normal soft tissue healing of tooth extraction sockets without inhibition of collagen
13 production, although which factors positively affect soft tissue healing remains unknown in the
14 present study. It has been reported that ONJ occurred in cancer patients treated with an anti-
15 angiogenic agent, bevacizumab, although these patients already had many other risk factors for ONJ
16 such as the use of chemotherapeutic drugs and abnormal immune responses [35]. This report
17 concluded that the incidence of ONJ in metastatic breast cancer patients treated with
18 bisphosphonates was not increased even when bevacizumab was used in combination with
19 bisphosphonate therapies [35]. A recent study showed that suppression of blood vessel formation
20 may not be a crucial factor in the development of ONJ [36]. Additionally, normal angiogenesis has
21 been reported in most histological studies of bisphosphonate-related ONJ [37,38]. It has not been
22 reported whether denosumab has anti-angiogenic effects on tooth extraction sockets. Hence, our
23 findings and accumulating scientific data support the finding that suppressed angiogenesis alone is
24 not a definitive cause of ONJ, although an anti-angiogenic effect may negatively influence osseous
25 wound healing of tooth extraction. It has been reported that administration duration of anti-

1 angiogenesis agents such as bevacizumab was relatively long in ONJ patients (e.g., one report was 6
2 months, another report was 2 years) [39,40]. Hence, further animal studies investigating the effects
3 of long-term anti-VEGFA mAb therapy on tooth extraction socket healing are required to clearly
4 manifest the relationship between anti-angiogenesis and BRONJ in mice.

5 In summary, we demonstrated that suppressed angiogenesis did not induce ONJ-like
6 lesions in mice. The combination of osteoclast suppression and angiogenesis inhibition, in addition
7 to other factors such as the use of chemotherapeutic drugs and compromised immune reactions,
8 may be essential for the development of ONJ. Moreover, ZA monotherapy did not evoke ONJ-like
9 lesions in mice, unlike in humans, indicating that caution should be exercised during the evaluation
10 of impaired wound healing when using experimental rodent models.

11

12 **Acknowledgements**

13 This work was supported by JSPS KAKENHI Grant Nos. 25870523 and 15K11258.

14

15 **Conflict of interest**

16 The authors declare that they have no conflict of interest.

17

18 **References**

- 19 1. Marx RE (2003) Pamidronate (Aredia) and zoledronate (Zometa) induced avascular necrosis of
20 the jaws: a growing epidemic. *J Oral Maxillofac Surg* 61:1115-7
- 21 2. Khan AA, Morrison A, Hanley DA, Felsenberg D, McCauley LK et al. (2015) Diagnosis and
22 management of osteonecrosis of the jaw: a systematic review and international consensus. *J*
23 *Bone Miner Res* 30:3-23 doi:10.1002/jbmr.2405
- 24 3. Ruggiero SL, Dodson TB, Fantasia J, Goodday R, Aghaloo T, Mehrotra B, O'Ryan F, Surgeons
25 AAOSM (2014) American Association of Oral and Maxillofacial Surgeons position paper on
26 medication-related osteonecrosis of the jaw--2014 update . *J Oral Maxillofac Surg* 72:1938-56
27 doi:10.1016/j.joms.2014.04.031

- 1 4. Miksad RA, Lai KC, Dodson TB, Woo SB, Treister NS, Akinyemi O, Bihrlle M, Maytal G,
2 August M, Gazelle GS, Swan JS (2011) Quality of life implications of bisphosphonate-
3 associated osteonecrosis of the jaw. *Oncologist* 16:121-32 doi:10.1634/theoncologist.2010-
4 0183
- 5 5. Bezzi M, Hasmim M, Bieler G, Dormond O, Rüegg C (2003) Zoledronate sensitizes endothelial
6 cells to tumor necrosis factor-induced programmed cell death: evidence for the suppression of
7 sustained activation of focal adhesion kinase and protein kinase B/Akt. *J Biol Chem* 278:43603-
8 14 doi:10.1074/jbc.M308114200
- 9 6. Sharma D, Hamlet SM, Petcu EB, Ivanovski S (2016) The effect of bisphosphonates on the
10 endothelial differentiation of mesenchymal stem cells. *Sci Rep* 6:20580 doi:10.1038/srep20580
- 11 7. Kuroshima S, Go VA, Yamashita J (2012) Increased numbers of nonattached osteoclasts after
12 long-term zoledronic acid therapy in mice. *Endocrinology* 153:17-28 doi: 10.1210/en.2011-
13 1439
- 14 8. Kuroshima S, Yamashita J (2013) Chemotherapeutic and antiresorptive combination therapy
15 suppressed lymphangiogenesis and induced osteonecrosis of the jaw-like lesions in mice. *Bone*
16 56:101-9 doi:10.1016/j.bone.2013.05.013
- 17 9. Kuroshima S, Mecano RB, Tanoue R, Koi K, Yamashita J (2014) Distinctive tooth-extraction
18 socket healing: bisphosphonate versus parathyroid hormone therapy. *J Periodontol* 85:24-33
19 doi:10.1902/jop.2013.130094
- 20 10. Tanoue R, Koi K, Yamashita J (2015) Effect of Alendronate on Bone Formation during Tooth
21 Extraction Wound Healing. *J Dent Res* 94:1251-8 doi:10.1177/0022034515592867
- 22 11. Fliefel R, Tröltzsch M, Kühnisch J, Ehrenfeld M, Otto S (2015) Treatment strategies and
23 outcomes of bisphosphonate-related osteonecrosis of the jaw (BRONJ) with characterization of
24 patients: a systematic review. *Int J Oral Maxillofac Surg* 44:568-85
25 doi:10.1016/j.ijom.2015.01.026
- 26 12. Fu D, Calvo JA, Samson LD (2012) Balancing repair and tolerance of DNA damage caused by
27 alkylating agents. *Nat Rev Cancer* 12:104-20 doi:10.1038/nrc3185
- 28 13. Lu R, Kujawski M, Pan H, Shively JE (2012) Tumor angiogenesis mediated by myeloid cells is
29 negatively regulated by CEACAM1. *Cancer Res* 72:2239-50 doi:10.1158/0008-5472.CAN-11-
30 3016
- 31 14. Sasaki M, Kuroshima S, Aoki Y, Inaba N, Sawase T (2015) Ultrastructural alterations of
32 osteocyte morphology via loaded implants in rabbit tibiae. *J Biomech* 48:4130-41
33 doi:10.1016/j.jbiomech.2015.10.025

- 1 15. Kuroshima S, Kovacic BL, Kozloff KM, McCauley LK, Yamashita J (2013) Intra-oral PTH
2 administration promotes tooth extraction socket healing. *J Dent Res* 92:553-9
3 doi:10.1177/0022034513487558
- 4 16. Bouxsein ML, Boyd SK, Christiansen BA, Guldberg RE, Jepsen KJ, Müller R (2010)
5 Guidelines for assessment of bone microstructure in rodents using micro-computed tomography.
6 *J Bone Miner Res* 25:1468-86 doi:10.1002/jbmr.141
- 7 17. Yamashita J, Koi K, Yang DY, McCauley LK (2011) Effect of zoledronate on oral wound
8 healing in rats. *Clin Cancer Res* 17:1405-14 doi: 10.1158/1078-0432.CCR-10-1614
- 9 18. Cheung-Ong K, Giaever G, Nislow C (2013) DNA-damaging agents in cancer chemotherapy:
10 serendipity and chemical biology. *Chem Biol* 20:648-59 doi:10.1016/j.chembiol.2013.04.007
- 11 19. Wang TM, Shih C (1986) Study of histomorphometric changes of the mandibular condyles in
12 neonatal and juvenile rats after administration of cyclophosphamide. *Acta Anat (Basel)* 127:93-
13 9
- 14 20. Vadhan-Raj S, Broxmeyer HE, Hittelman WN, Papadopoulos NE, Chawla SP, Fenoglio C,
15 Cooper S, Buescher ES, Frenck RW, Holian A (1992) Abrogating chemotherapy-induced
16 myelosuppression by recombinant granulocyte-macrophage colony-stimulating factor in
17 patients with sarcoma: protection at the progenitor cell level. *J Clin Oncol* 10:1266-77
- 18 21. Okabe K, Nakagawa K, Yamamoto E (1995) Factors affecting the occurrence of bacteremia
19 associated with tooth extraction. *Int J Oral Maxillofac Surg* 24:239-42
- 20 22. Tomás I, Alvarez M, Limeres J, Potel C, Medina J, Diz P (2007) Prevalence, duration and
21 aetiology of bacteraemia following dental extractions. *Oral Dis* 13:56-62 doi:10.1111/j.1601-
22 0825.2006.01247.x
- 23 23. Singer AJ, Clark RA (1999) Cutaneous wound healing. *N Engl J Med* 341:738-46
24 doi:10.1056/NEJM199909023411006
- 25 24. Fournier BM, Parkos CA (2012) The role of neutrophils during intestinal inflammation.
26 *Mucosal Immunol* 5:354-66 doi:10.1038/mi.2012.24
- 27 25. Leoni G, Neumann PA, Sumagin R, Denning TL, Nusrat A (2015) Wound repair: role of
28 immune-epithelial interactions. *Mucosal Immunol* 8:959-68 doi:10.1038/mi.2015.63
- 29 26. Browder T, Butterfield CE, Kräling BM, Shi B, Marshall B, O'Reilly MS, Folkman J (2000)
30 Antiangiogenic scheduling of chemotherapy improves efficacy against experimental drug-
31 resistant cancer. *Cancer Res* 60:1878-86

- 1 27. Hanahan D, Bergers G, Bergsland E (2000) Less is more, regularly: metronomic dosing of
2 cytotoxic drugs can target tumor angiogenesis in mice. *J Clin Invest* 105:1045-7
3 doi:10.1172/JCI9872
- 4 28. Kerbel RS, Kamen BA (2004) The anti-angiogenic basis of metronomic chemotherapy. *Nat*
5 *Rev Cancer* 4:423-36 doi:10.1038/nrc1369
- 6 29. Guerriero JL, Ditsworth D, Catanzaro JM, Sabino G, Furie MB, Kew RR, Crawford HC, Zong
7 WX (2011) DNA alkylating therapy induces tumor regression through an HMGB1-mediated
8 activation of innate immunity. *J Immunol* 186:3517-26 doi:10.4049/jimmunol.1003267
- 9 30. Ji Hung TT, Chan J, Russell PJ, Power CA (2011) Zoledronic acid preserves bone structure and
10 increases survival but does not limit tumour incidence in a prostate cancer bone metastasis
11 model. *PLoS One* 6:e19389 doi:10.1371/journal.pone.0019389
- 12 31. Ravosa MJ, Ning J, Liu Y, Stack MS (2011) Bisphosphonate effects on the behaviour of oral
13 epithelial cells and oral fibroblasts. *Arch Oral Biol* 56:491-8
14 doi:10.1016/j.archoralbio.2010.11.003
- 15 32. Walter C, Klein MO, Pabst A, Al-Nawas B, Duschner H, Ziebart T (2010) Influence of
16 bisphosphonates on endothelial cells, fibroblasts, and osteogenic cells. *Clin Oral Investig* 14:35-
17 41 doi:10.1007/s00784-009-0266-4
- 18 33. Kobayashi Y, Hiraga T, Ueda A, Wang L, Matsumoto-Nakano M, Hata K, Yatani H, Yoneda T
19 (2010) Zoledronic acid delays wound healing of the tooth extraction socket, inhibits oral
20 epithelial cell migration, and promotes proliferation and adhesion to hydroxyapatite of oral
21 bacteria, without causing osteonecrosis of the jaw, in mice. *J Bone Miner Metab* 28:165-75
22 doi:10.1007/s00774-009-0128-9
- 23 34. Santini D, Vincenzi B, Dicuonzo G, Avvisati G, Massacesi C, Battistoni F, Gavasci M, Rocci L,
24 Tirindelli MC, Altomare V, Tocchini M, Bonsignori M, Tonini G (2003) Zoledronic acid
25 induces significant and long-lasting modifications of circulating angiogenic factors in cancer
26 patients. *Clin Cancer Res* 9:2893-7
- 27 35. Guarneri V, Miles D, Robert N, Diéras V, Glaspy J, Smith I, Thomssen C, Biganzoli L, Taran T,
28 Conte P (2010) Bevacizumab and osteonecrosis of the jaw: incidence and association with
29 bisphosphonate therapy in three large prospective trials in advanced breast cancer. *Breast*
30 *Cancer Res Treat* 122:181-8 doi:10.1007/s10549-010-0866-3
- 31 36. Francini F, Pascucci A, Francini E, Miano ST, Bargagli G, Ruggiero G, Petrioli R (2011)
32 Osteonecrosis of the jaw in patients with cancer who received zoledronic acid and bevacizumab.
33 *J Am Dent Assoc* 142:506-13

- 1 37. Lesclous P, Abi Najm S, Carrel JP, Baroukh B, Lombardi T, Willi JP, Rizzoli R, Saffar JL,
2 Samson J (2009) Bisphosphonate-associated osteonecrosis of the jaw: a key role of
3 inflammation?. *Bone* 45:843-52 doi:10.1016/j.bone.2009.07.011
- 4 38. Hansen T, Kunkel M, Weber A, James Kirkpatrick C (2006) Osteonecrosis of the jaws in
5 patients treated with bisphosphonates - histomorphologic analysis in comparison with infected
6 osteoradionecrosis. *J Oral Pathol Med* 35:155-60 doi:10.1111/j.1600-0714.2006.00391.x
- 7 39. Hopp RN, Pucci J, Santos-Silva AR, Jorge J (2012) Osteonecrosis after administration of
8 intravitreal bevacizumab. *J Oral Maxillofac Surg* 70:632-5 doi:10.1016/j.joms.2011.02.104
- 9 40. Santos-Silva AR, Belizário Rosa GA, Castro Júnior G, Dias RB, Prado Ribeiro AC, Brandão
10 TB (2013) Osteonecrosis of the mandible associated with bevacizumab therapy. *Oral Surg Oral*
11 *Med Oral Pathol Oral Radiol* 115:e32-6 doi:10.1016/j.oooo.2013.02.001

12
13

14 **Figure legends**

15 **Fig. 1** Experimental design. (a) Time schedules for ZA monotherapy, CY monotherapy, and CY/ZA
16 combination therapy. Tooth extraction was performed 3 weeks after the onset of drug treatments.
17 Euthanasia was conducted 2 and 4 weeks post-extraction. VC: vehicle control, CY:
18 cyclophosphamide, ZA: zoledronate. (b) Both maxillary first molars (M1) were selected as tooth
19 extraction sites. M2 and M3 indicate second and third molars, respectively.

20 **Fig. 2** Effect of administered drugs on gross wound healing in tooth extraction sockets. (a)
21 Representative gross wound healing 2 weeks post-extraction. Black dotted lines indicate second
22 (M2) and third molars (M3). Red dotted lines indicate the outlines of wounds. (b) No open wounds
23 were observed in VC and ZA. Open wounds were observed in 64.2% of CY and 100% of CY/ZA.
24 (c) Increased wound areas were observed in CY and CY/ZA compared with VC and ZA, although
25 the wound area in CY/ZA was significantly larger than that in CY. (d) Representative gross wound
26 healing 4 weeks post-extraction. Black dotted lines indicate second (M2) and third molars (M3).
27 Red dotted lines indicate the outlines of wounds. (e) No open wounds were observed in VC and ZA.

1 Open wounds were noted in only 7.14% of CY and 100% of CY/ZA. (f) The wound area in CY/ZA
2 was significantly larger than that in all other groups. $n = 7/\text{group}$; *, $p < 0.05$, ***, $p < 0.001$,
3 compared with VC. †, $p < 0.05$, ††, $p < 0.01$, †††, $p < 0.001$, compared with other groups except for
4 VC.

5 **Fig. 3** Effect of administered drugs on osseous wound healing 2 and 4 weeks post-extraction. (a)
6 Representative cross-sectional microcomputed tomography (microCT) images of tooth extraction
7 sockets 2 weeks post-extraction. M1 and M2 indicate first molars and second molars, respectively.
8 (b) Bone fill of tooth extraction sockets in CY and CY/ZA was significantly impaired compared
9 with VC and ZA. (c) Trabecular number (Tb.N) in CY and CY/ZA was significantly decreased
10 compared with VC and ZA. (d) Trabecular thickness (Tb.Th) was significantly smaller in CY
11 compared with VC and ZA. Tb.Th was smaller in CY/ZA compared with VC without significant
12 difference. (e) Trabecular separation (Tb.Sp) was significantly greater in CY and CY/ZA compared
13 with VC and ZA. (f) Increased bone mineral density (BMD) was observed in ZA compared with
14 other groups. Decreased BMD was noted in CY and CY/ZA compared with VC. (g) Representative
15 cross-sectional microCT images of tooth extraction sockets 4 weeks post-extraction. Yellow dotted
16 lines indicate the mesial and distal roots of tooth extraction sockets. (h) Bone fill of tooth extraction
17 sockets in CY and CY/ZA was significantly impaired compared with VC. Significantly greater bone
18 fill was noted in ZA compared with VC. (i) Tb.N in ZA, CY, and CY/ZA was significantly
19 decreased compared with VC. (j) Tb.Th was significantly smaller in CY/ZA compared with VC,
20 whereas Tb.Th was greater in ZA compared with VC. (k) Tb.Sp was significantly greater in CY and
21 CY/ZA compared with VC and ZA. (l) Increased BMD was observed in ZA compared with VC.
22 Decreased BMD was noted in CY and CY/ZA compared with VC. $n = 7/\text{group}$; *, $p < 0.05$, **, $p <$
23 0.01 , ***, $p < 0.001$, compared with VC. †, $p < 0.05$, ††, $p < 0.01$, †††, $p < 0.001$, compared with
24 other groups except for VC.

1 **Fig. 4** Effect of administered drugs on tooth extraction socket healing 2 weeks post-extraction. (a)
2 Representative sagittal H-E- and TRAP-stained images of tooth extraction sockets. Bar: 200 μ m and
3 50 μ m, respectively. In H-E-stained images, localized and extended open wounds were grossly
4 observed in CY and CY/ZA, respectively. In TRAP-stained images, black arrowheads indicate
5 osteoclasts on bone surfaces. (b) Osteoclast numbers were significantly decreased in ZA, CY, and
6 CY/ZA compared with VC. (c) The living bone area was significantly decreased in CY and CY/ZA
7 compared with VC and ZA. (d) The necrotic bone area was significantly increased in CY and
8 CY/ZA compared with VC and ZA. (e) The number of empty lacunae was significantly increased in
9 CY and CY/ZA compared with VC and ZA. (f) The number of osteocytes was significantly
10 decreased in CY and CY/ZA compared with VC and ZA. (g) Representative trichrome-stained
11 images of tooth extraction sockets. Bar: 200 μ m. Yellow dotted lines indicate the border between
12 alveolar bone and connective tissues. (h) The collagen area was significantly decreased in CY/ZA
13 compared with all other groups. (i) PMN infiltration in CY and CY/ZA was significantly decreased
14 compared with that in VC and ZA. Significantly more PMN infiltration was observed in CY/ZA
15 compared with CY. $n = 7/\text{group}$; *, $p < 0.05$, **, $p < 0.01$, ***, $p < 0.001$, compared with VC. †, $p <$
16 0.05 , ††, $p < 0.01$, †††, $p < 0.001$, compared with other groups except for VC.

17 **Fig. 5** Effect of administered drugs on tooth extraction socket healing 4 weeks post-extraction. (a)
18 Representative sagittal H-E- and TRAP-stained images of tooth extraction sockets. Bar: 200 μ m and
19 50 μ m, respectively. In H-E-stained images, extended open wounds were grossly observed in
20 CY/ZA. In TRAP-stained images, black arrowheads indicate osteoclasts on bone surfaces. (b)
21 Osteoclast numbers were significantly decreased in ZA and CY/ZA compared with VC and CY. (c)
22 The living bone area was significantly decreased in CY and CY/ZA compared with VC and ZA. (d)
23 The necrotic bone area was significantly increased in CY/ZA compared with all other groups. (e)
24 The number of empty lacunae was significantly increased in CY and CY/ZA compared with VC. (f)

1 The number of osteocytes was significantly decreased in CY and CY/ZA compared with VC. (g)
2 Representative trichrome-stained images of tooth extraction sockets. Bar: 200 μm . Yellow dotted
3 lines indicate the border between alveolar bone and connective tissues. (h) Collagen area was
4 significantly decreased in CY/ZA compared with all other groups. (i) A significantly greater
5 number of PMNs were observed in CY/ZA compared with all other groups. $n = 7/\text{group}$; *, $p < 0.05$,
6 ***, $p < 0.001$, compared with VC. ††, $p < 0.01$, †††, $p < 0.001$, compared with other groups except
7 for VC.

8 **Fig. 6** Effect of administered drugs on the formation of blood vessels in soft tissue wounds. (a)
9 Representative immunostaining using anti-CD31 antibody 2 weeks post-extraction. Nuclei were
10 stained with DAPI. White arrowheads indicate CD31-positive vessels. Ep: epithelium, Ct:
11 connective tissue, Ab: alveolar bone, Bar: 100 μm . (b) The number of blood vessels was
12 significantly decreased in CY and CY/ZA compared with VC and ZA. The number of blood vessels
13 was the same between CY and CY/ZA. (c) Vessel surface was significantly decreased in ZA, CY,
14 and CY/ZA compared with VC. (d) Representative immunostaining using anti-CD31 antibody 4
15 weeks post-extraction. Nuclei were stained with DAPI. White arrowheads indicate CD31-positive
16 vessels. Bar: 100 μm . (e) The number of blood vessels was the same between VC and ZA but
17 significantly decreased in CY and CY/ZA compared with VC and ZA. (f) Vessel area was the same
18 between VC and ZA but significantly smaller in CY and CY/ZA compared with VC and ZA. $n =$
19 $7/\text{group}$; *, $p < 0.05$, **, $p < 0.01$, ***, $p < 0.001$, compared with VC. †, $p < 0.05$, †††, $p < 0.001$,
20 compared with other groups except for VC.

21 **Fig. 7** Effect of anti-VEGFA mAb on tooth extraction socket healing. (a) Time schedule for IgG2a
22 and anti-VEGFA mAb therapy. IgG2a and mAb therapies were performed once every 2 days just
23 after tooth extraction for 2 weeks. (b) Representative gross wound healing 2 weeks post-extraction.
24 M2 and M3 indicate the second and third molars, respectively. (c) No open wounds were observed

1 following both IgG2a and mAb therapies. (d) Representative H-E-stained images of tooth extraction
2 sockets. Open wounds and necrotic bone were not grossly observed. Bar: 200 μm . (e) The living
3 bone area was significantly decreased in mAb compared with IgG2a. (f-h) The necrotic bone area,
4 number of empty lacunae, and osteocyte number were the same between IgG2a and mAb. (i)
5 Representative trichrome-stained images of tooth extraction sockets. Yellow dotted lines indicate
6 the border between alveolar bone and connective tissues. Bar: 200 μm . (j) Collagen production was
7 the same between IgG2a and mAb. (k) Significant PMN infiltration was observed in mAb
8 compared with IgG2a. (l) Representative immunostaining for CD31. Nuclei were stained with
9 DAPI. White arrowheads indicate CD31-positive vessels. Bar: 100 μm . (m) The number of blood
10 vessels was significantly decreased in mAb compared with IgG2a. (n) Vessel surface was similar
11 between IgG2a and mAb. $n = 4/\text{group}$; **, $p < 0.01$.

12

FIG. 1.

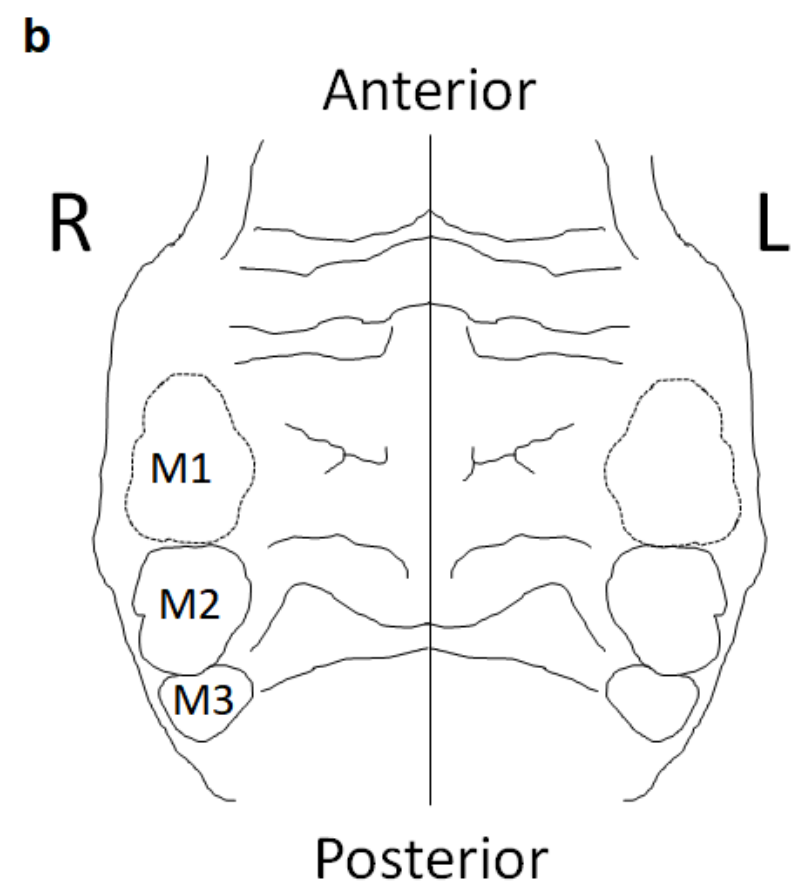
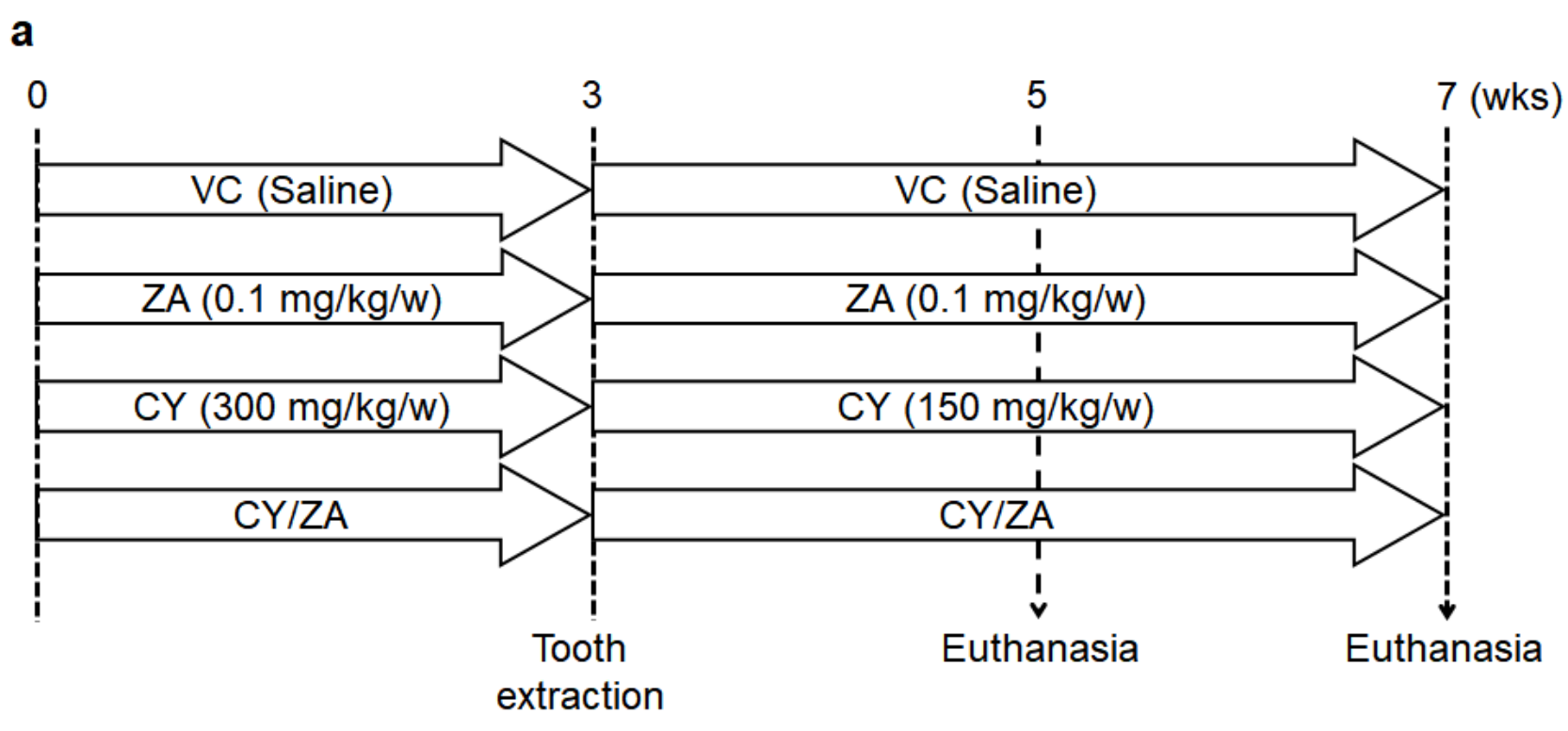
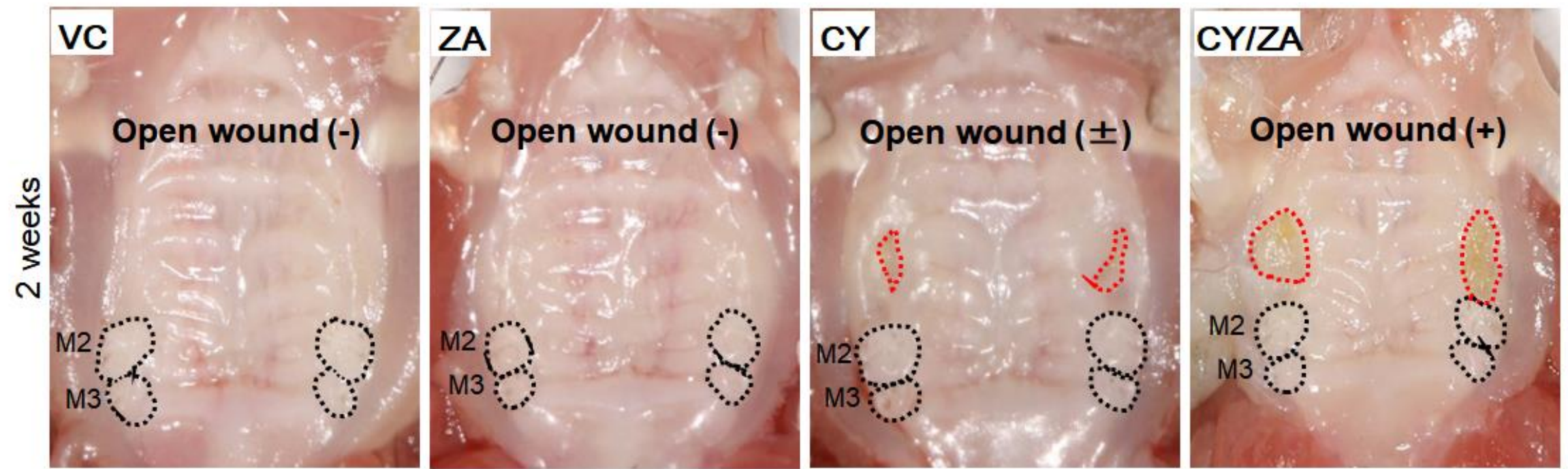
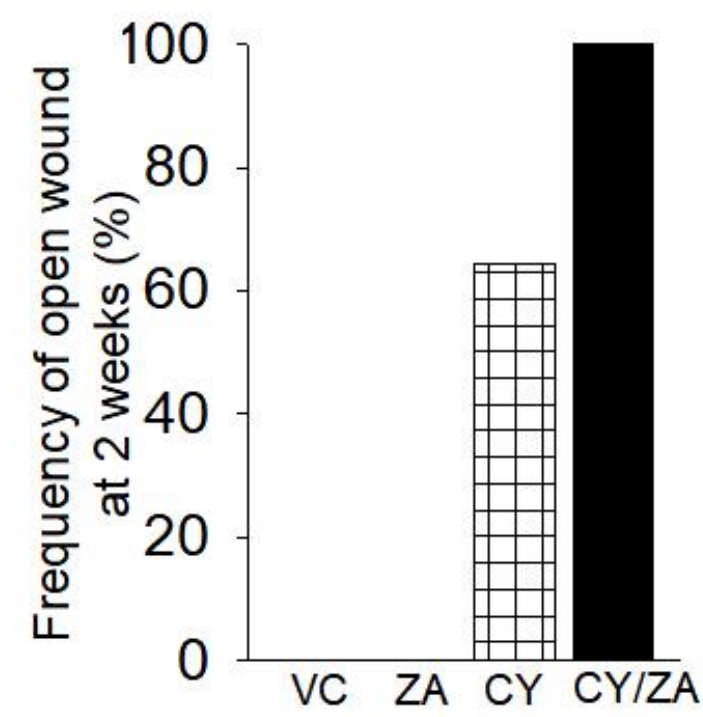


FIG. 2.

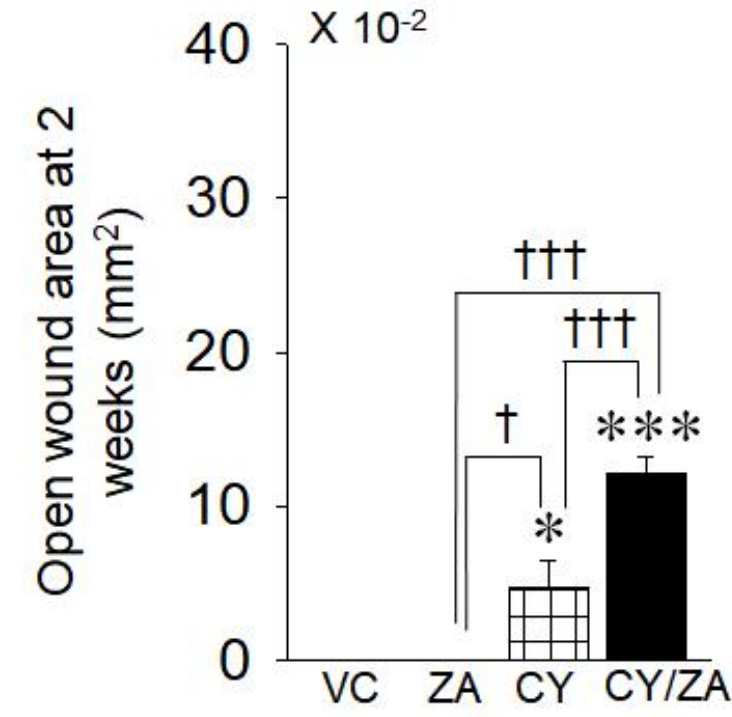
a



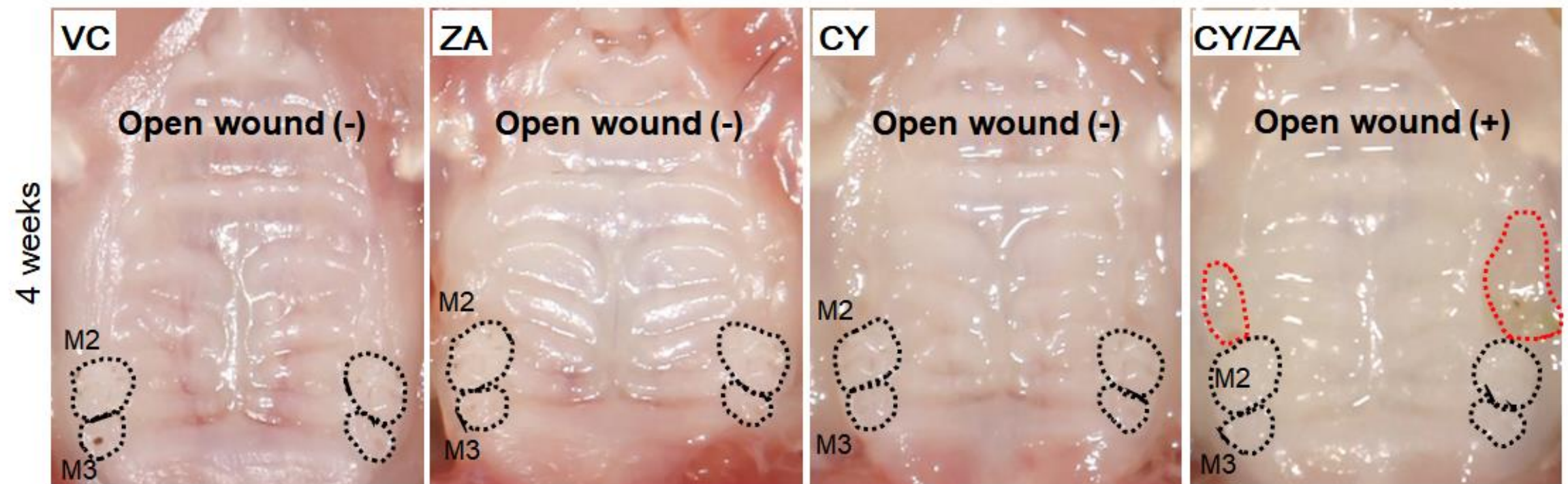
b



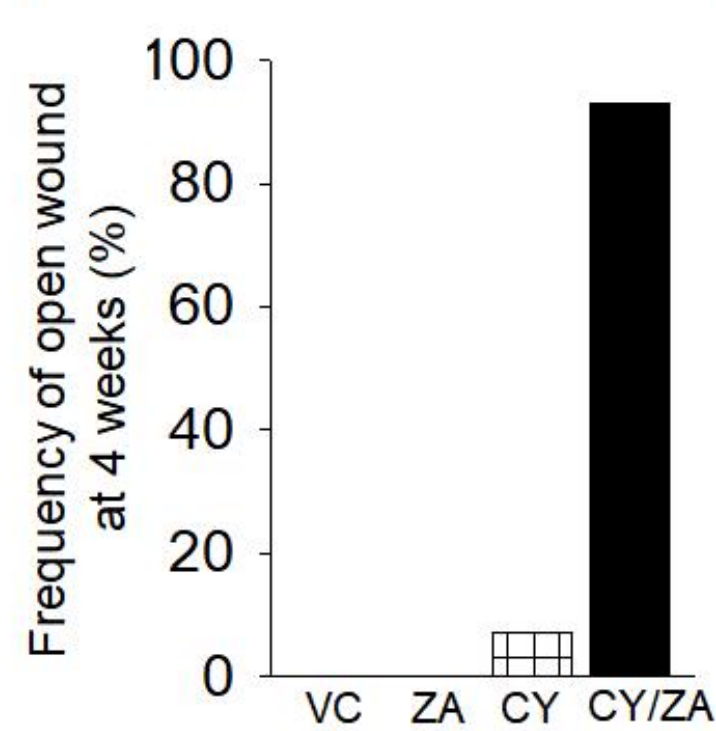
c



d



e



f

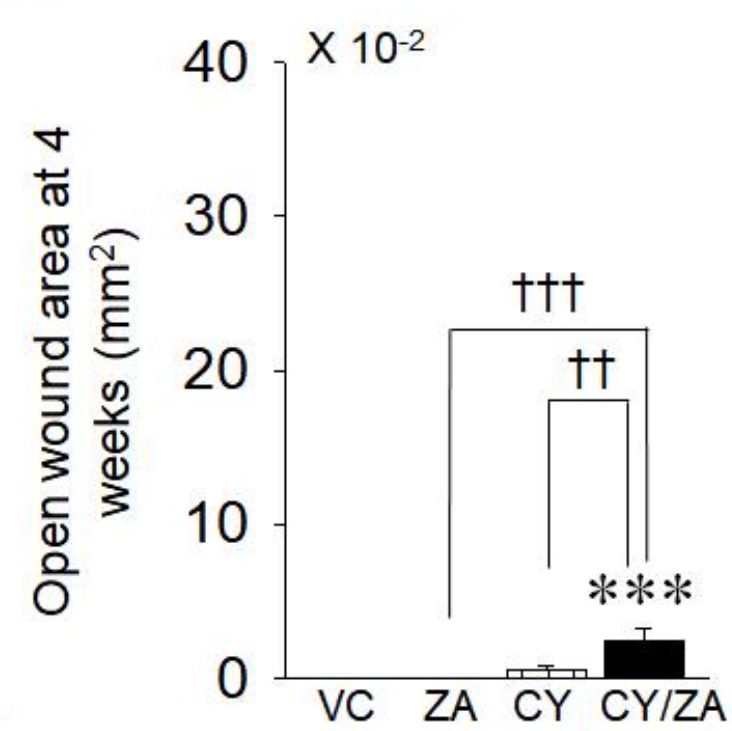
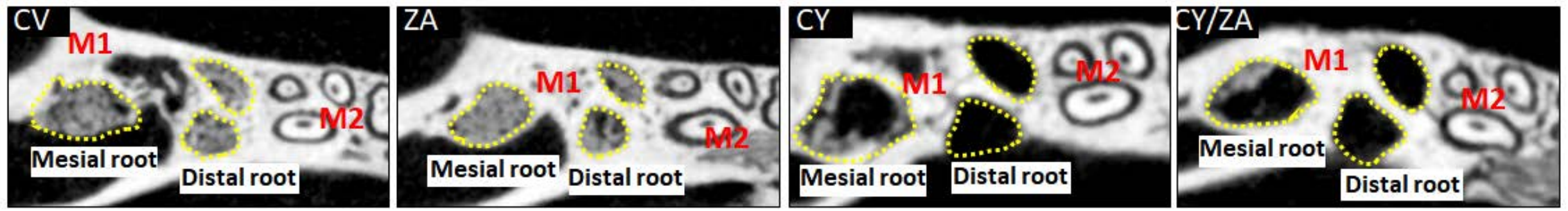
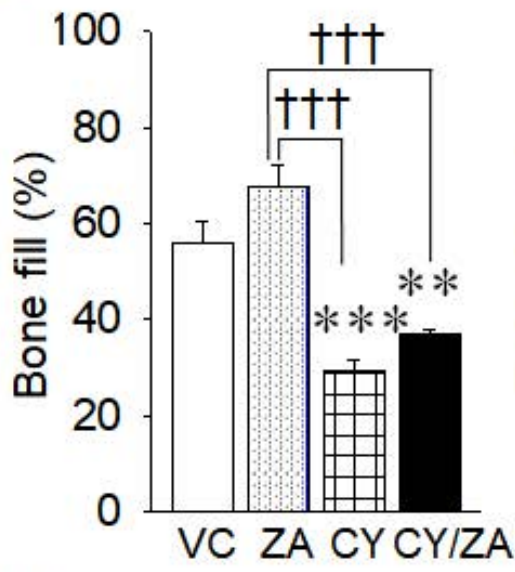


FIG. 3.

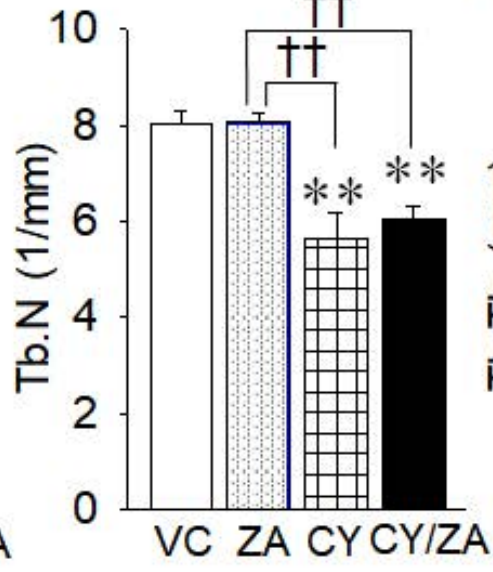
a



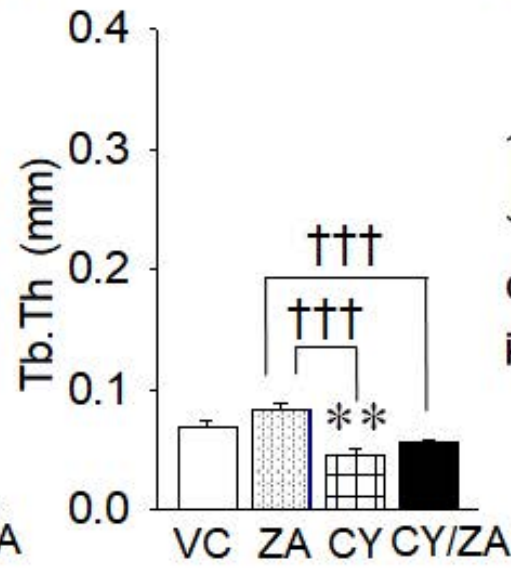
b



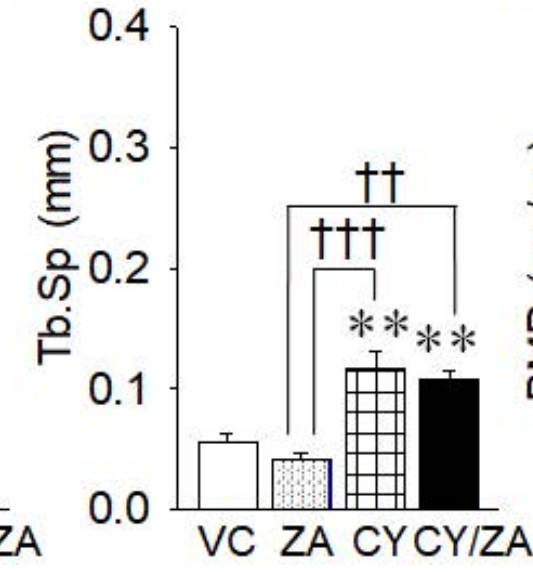
c



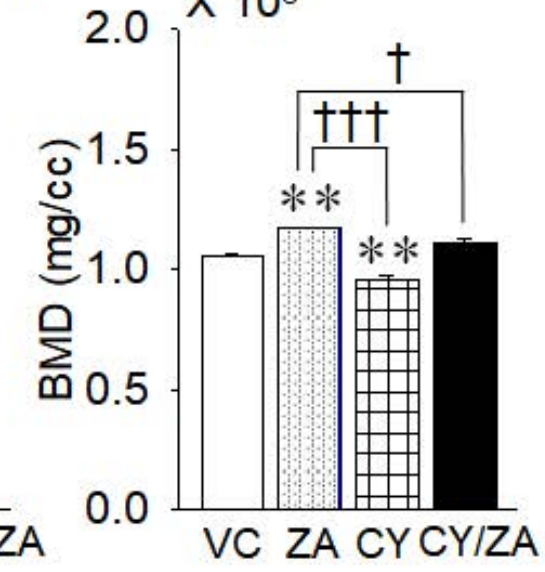
d



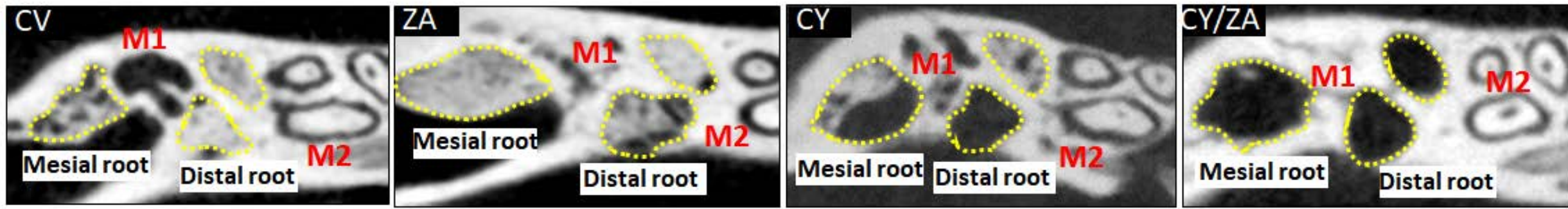
e



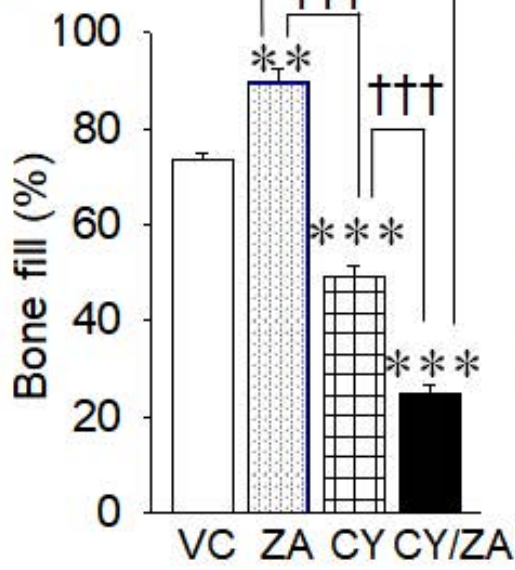
f



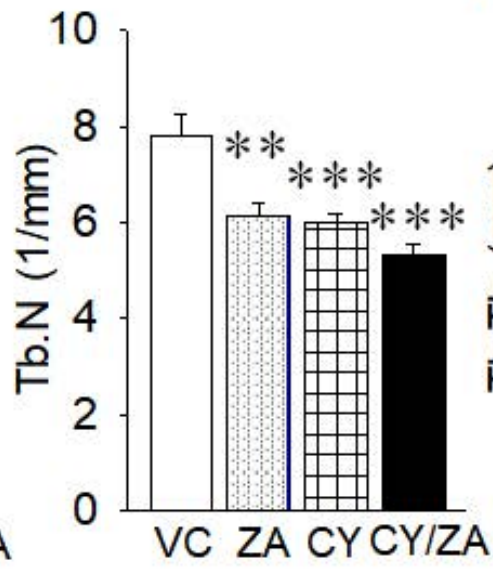
g



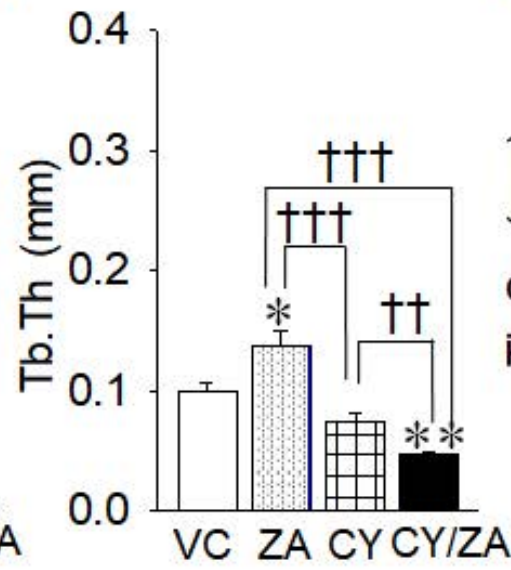
h



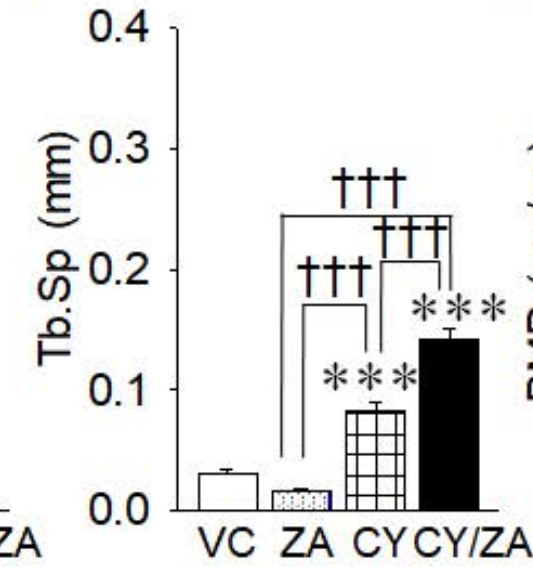
i



j



k



l

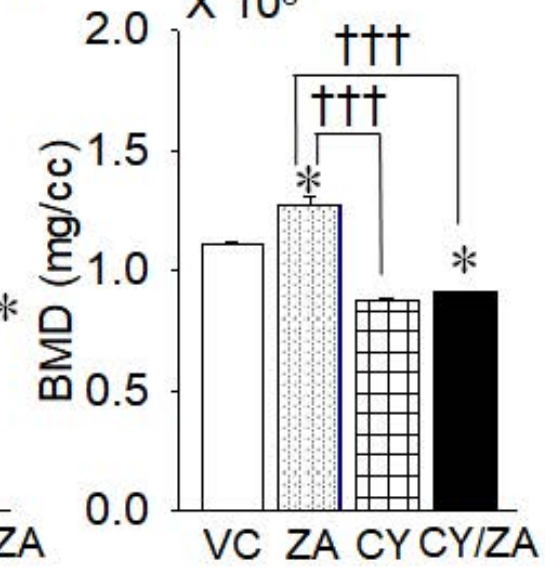
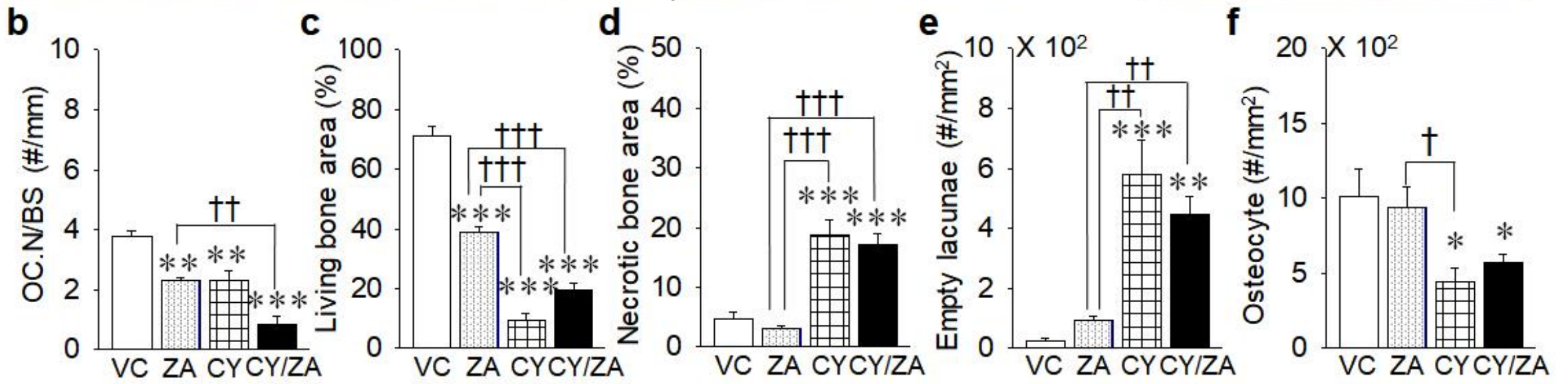
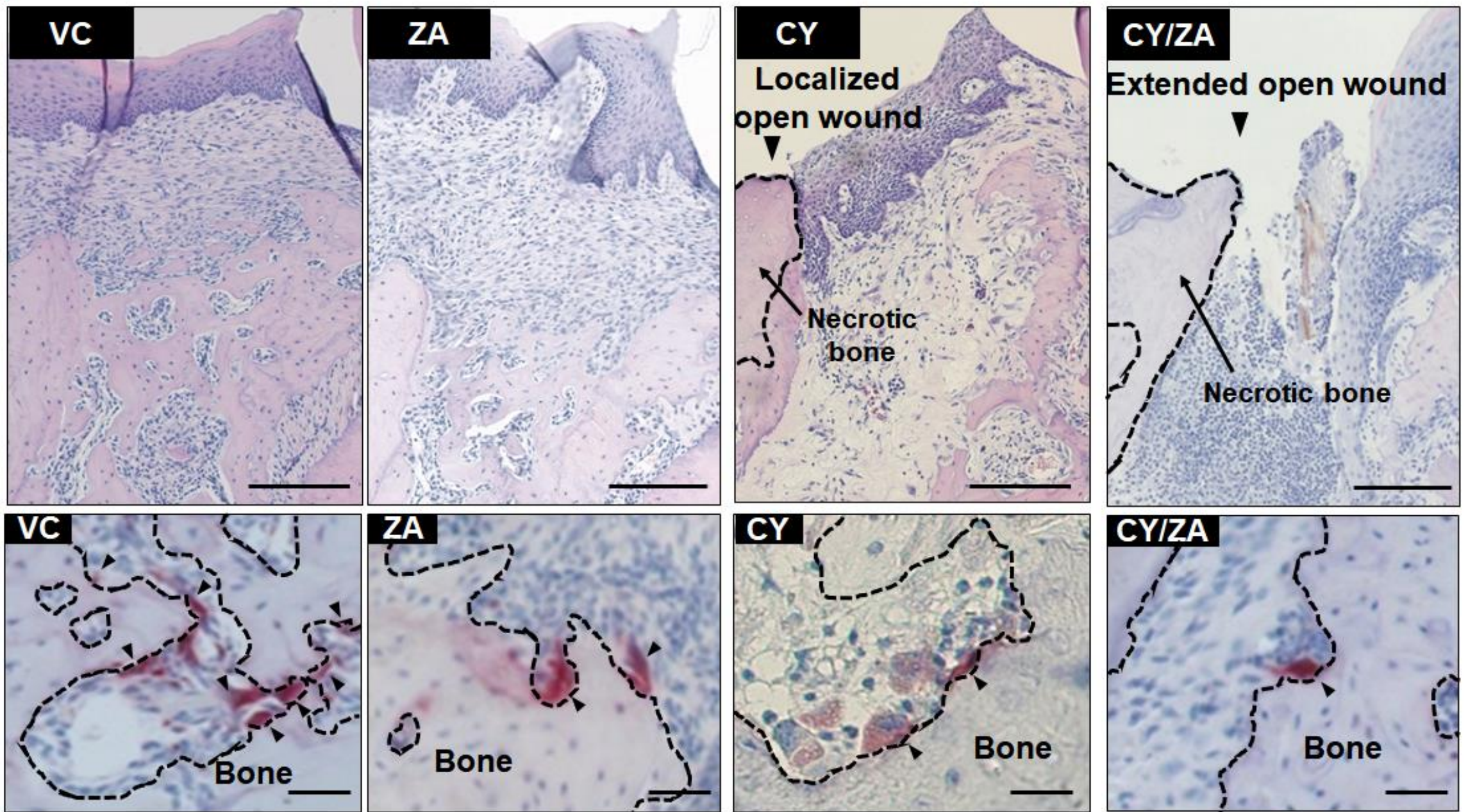


FIG. 4.

a



g

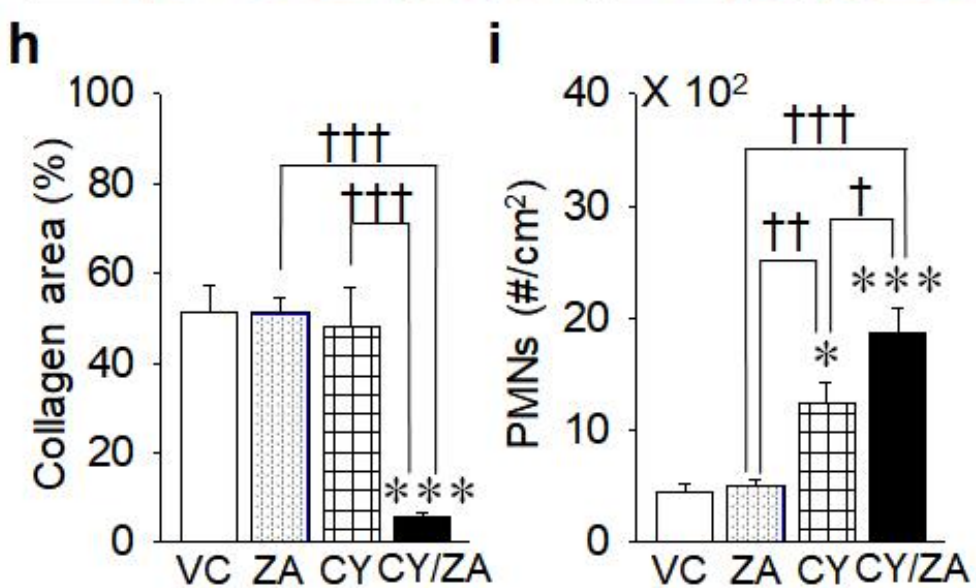
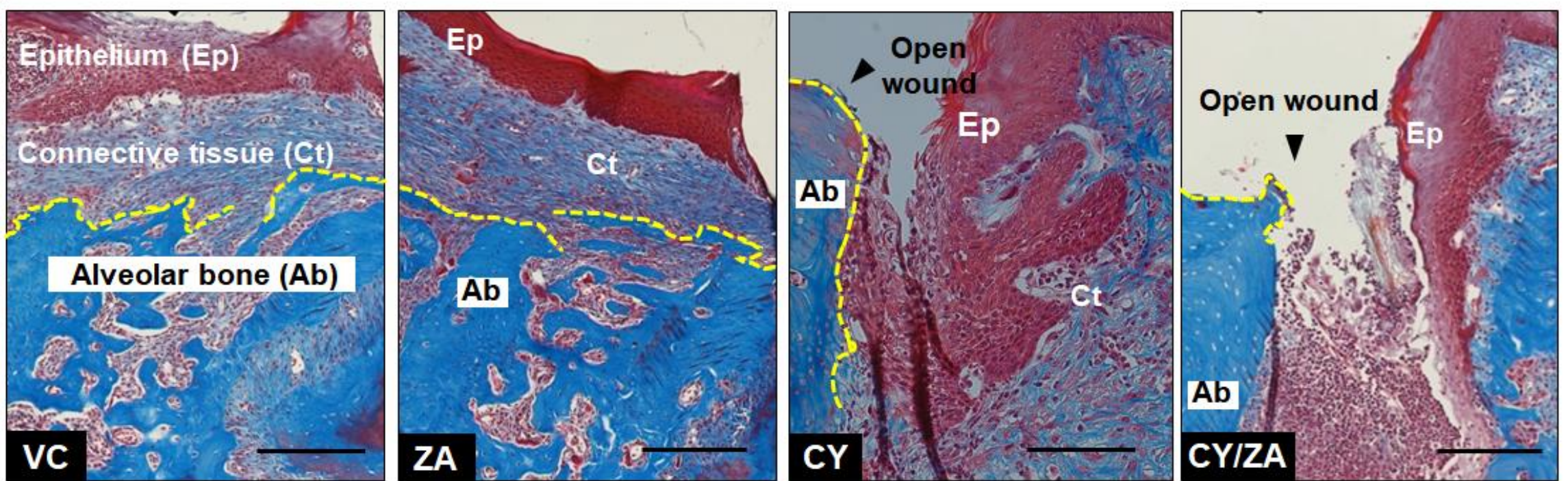
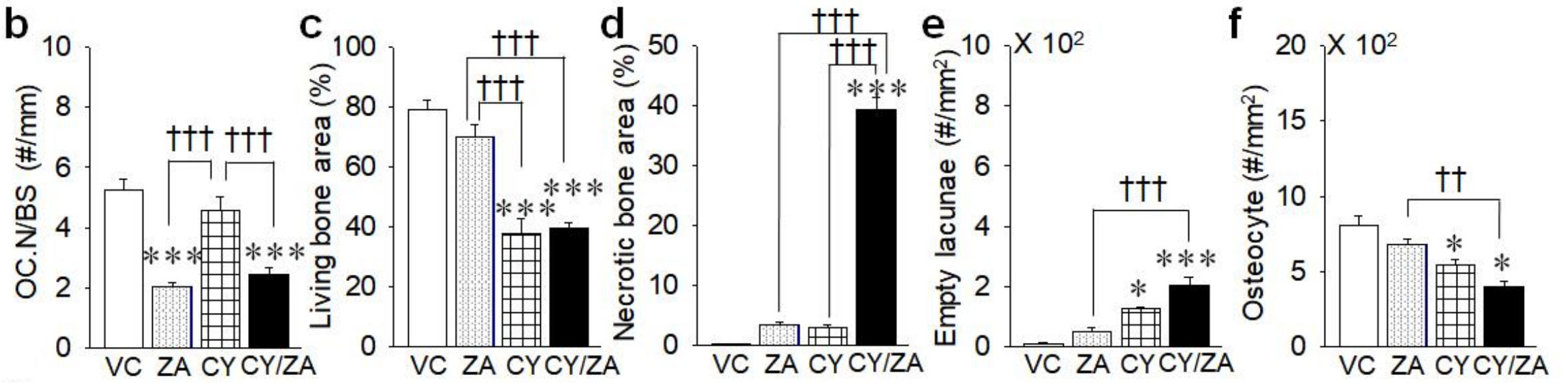
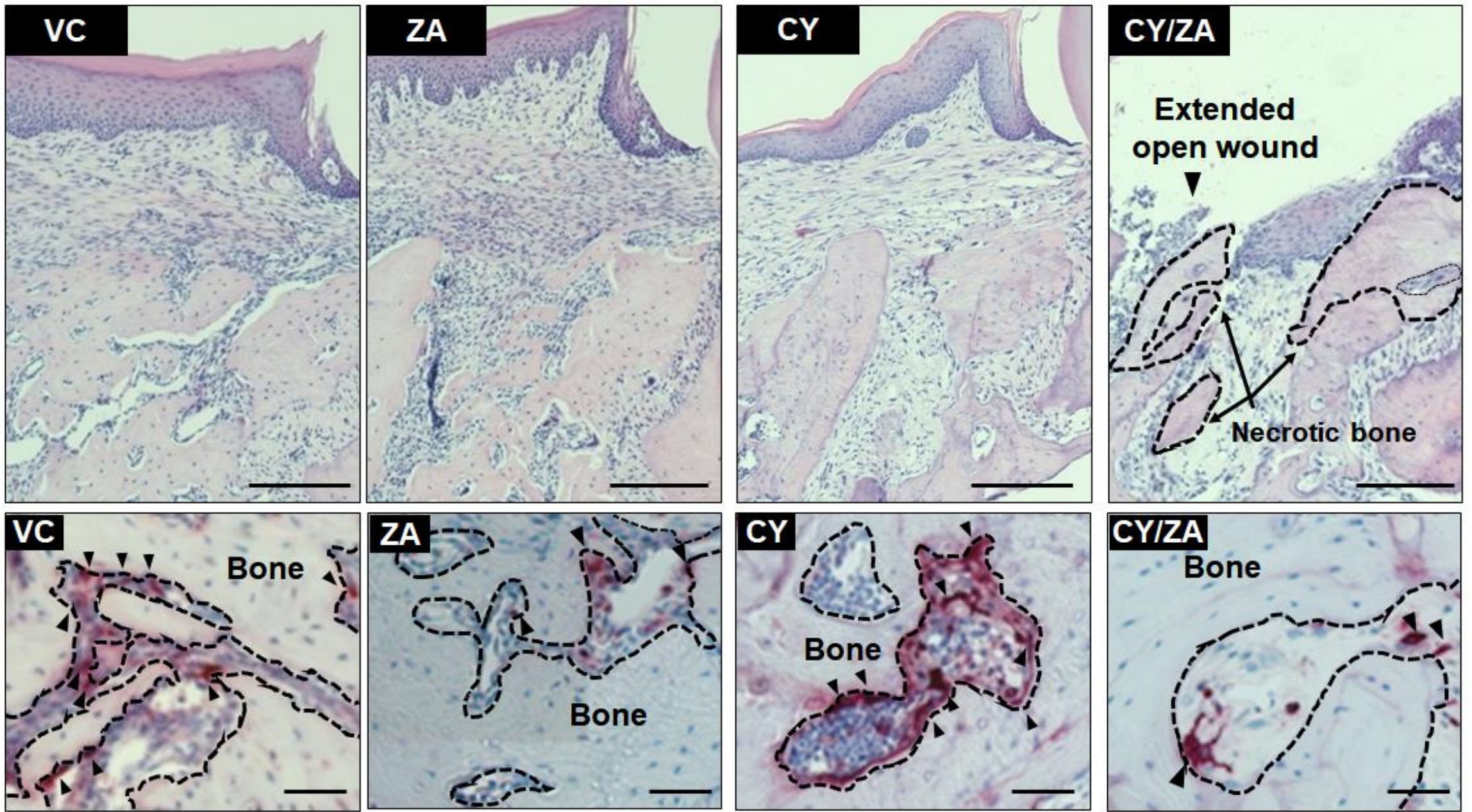


FIG. 5.

a



g

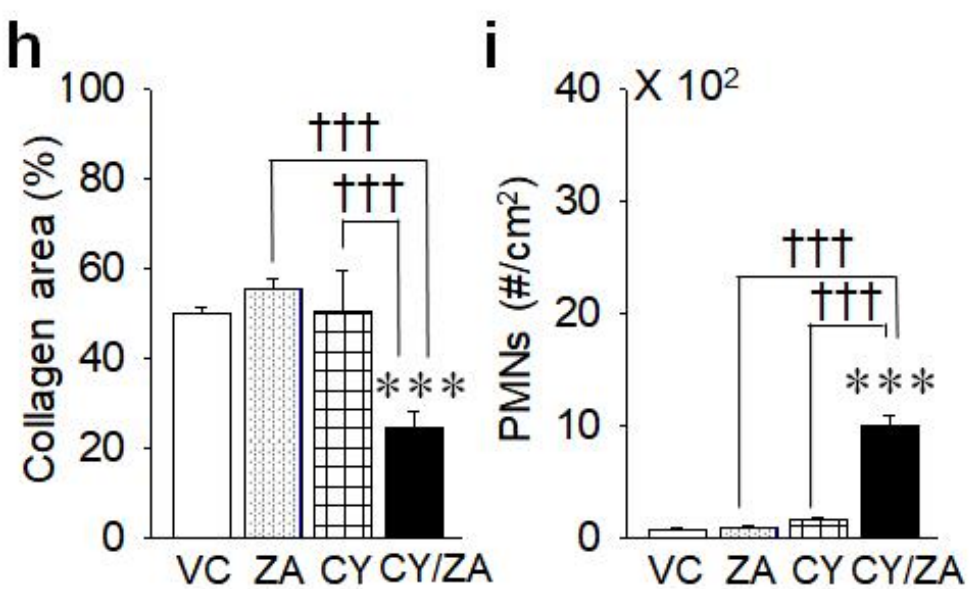
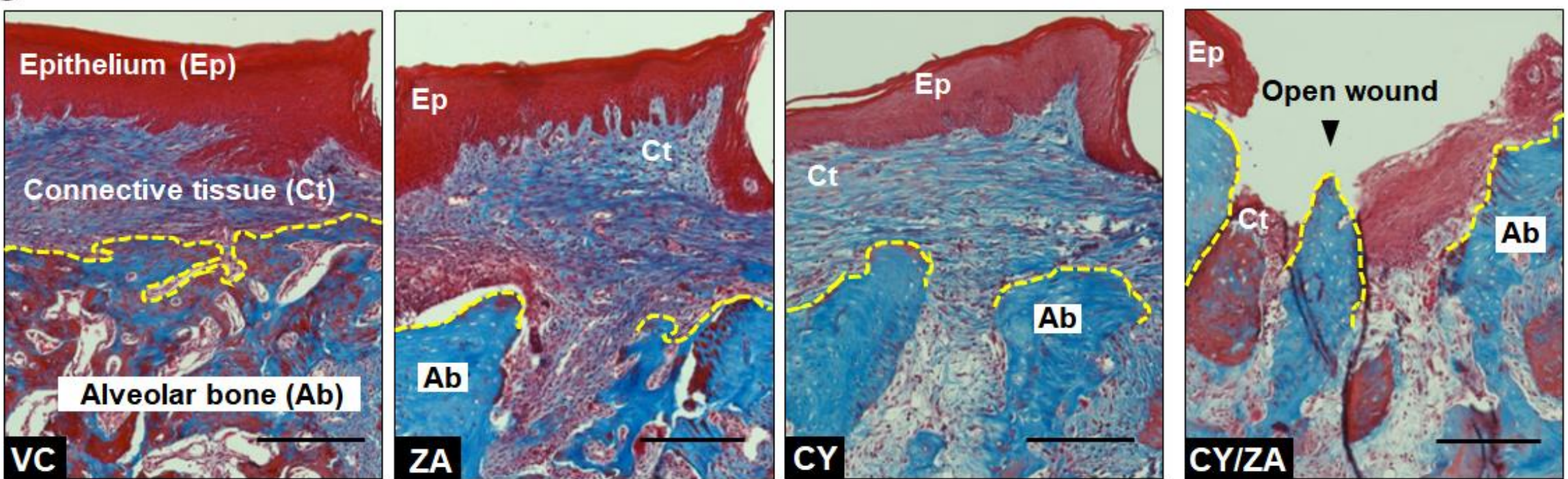
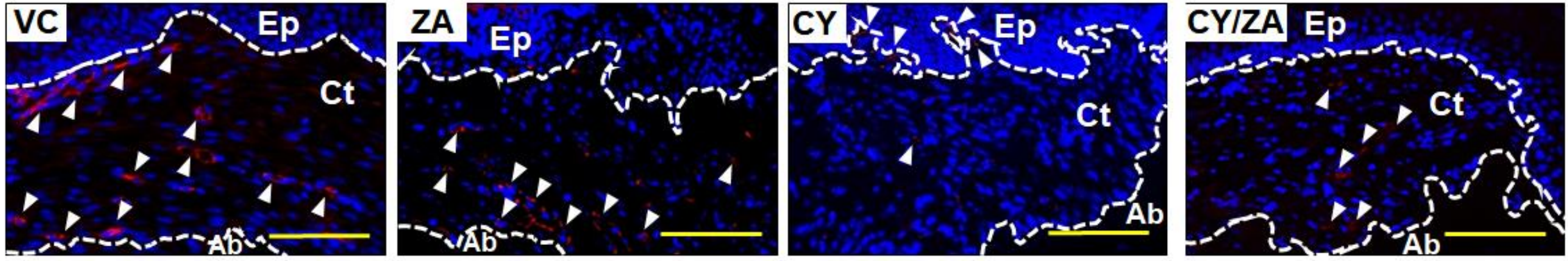
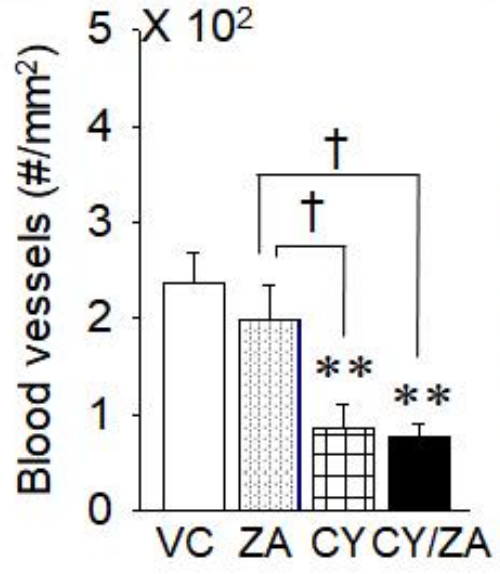


FIG. 6.

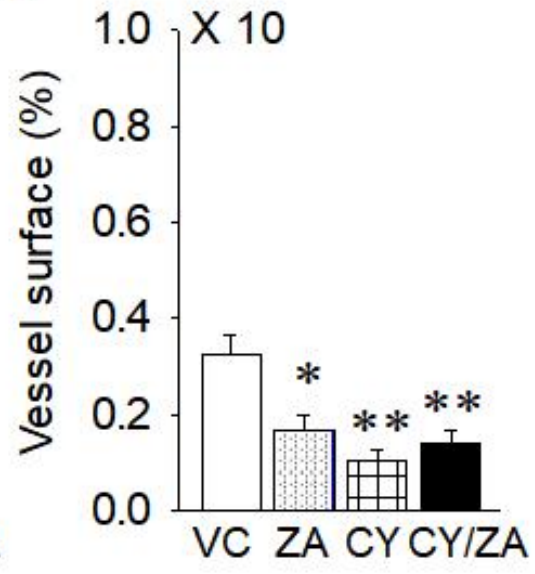
a



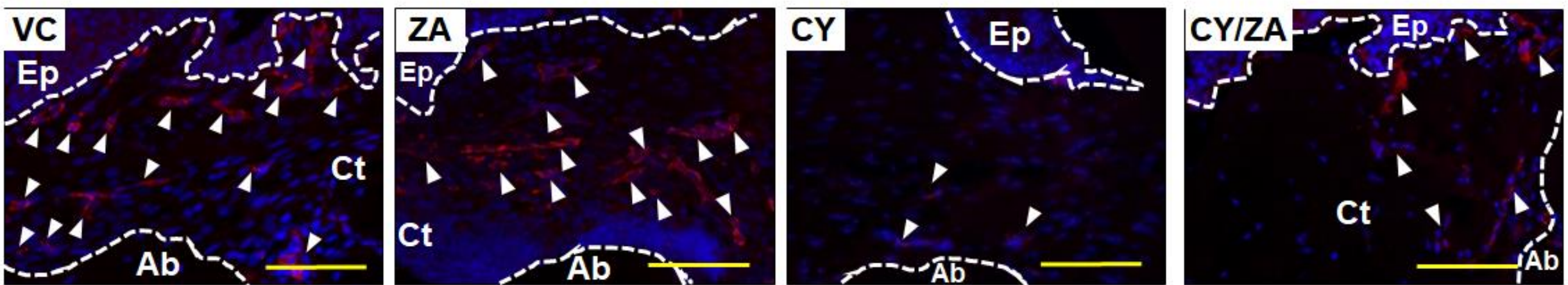
b



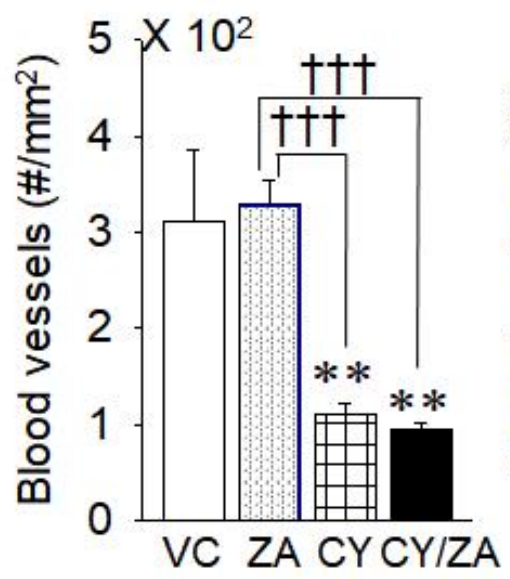
c



d



e



f

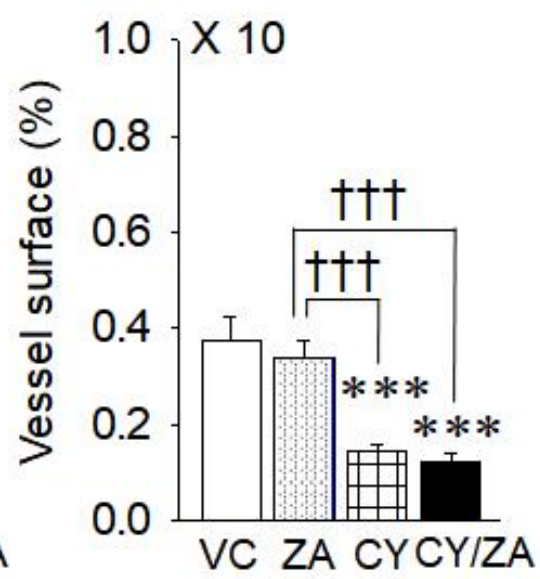


FIG. 7.

