

Case Report

Management of gingival hyperplasia associated with sore mucositis in an acute leukemia patient

Harushi YOSHIDA¹, Makiko HORAI², Minoru MASUNISHI¹, Tomoko HATA², Tomoyuki NOGAMI¹, Terumi AYUSE¹, Yoshitaka IMAIZUMI², Yasushi MIYAZAKI², Takao AYUSE¹

¹ Department of Special Care Dentistry, Nagasaki University Hospital, Nagasaki, Japan

² Department of Hematology, Nagasaki University Hospital, Nagasaki, Japan

Gingival enlargement is a prominent symptom in patients with myelomonocytic leukemia (AML-M4) and acute monocytic leukemia (AML-M5). Poor oral hygiene may aggravate the condition. However, patients are apt to avoid oral care out of fear of the pain and hemorrhage associated with the myelopoietic disorder. Here we report a case of a patient with AML-M4 in whom oral care intervention from an early stage improved the quality of life by relieving the pain associated with mucositis and gingival overgrowth aggravated by preceding periodontal lesions.

ACTA MEDICA NAGASAKIENSIA 60: 129–133, 2016

Key words: pain relief, gingival overgrowth, acute leukemia, oral care, moisturizer

Introduction

Acute myeloid leukemia (AML) is a malignancy of the hematopoietic progenitor cells that provokes bleeding and fever as a result of infection¹. The main symptoms are fatigue, weight loss, fever and gingival bleeding. Among the oral manifestations, gingival hyperplasia is frequently encountered by patients with AML. Gingival involvement, which is more likely to occur in the subtypes of French American British classification (FAB), was reported in acute myelomonocytic leukemia (AML-M4) and acute monocytic leukemia (AML-M5) at a prevalence of 18.5 % and 66.7% respectively². Younger patients were implicated in most of the gingival hyperplastic case reports, which revealed that chemotherapy alleviated the gingival lesions without any routine periodontal treatments³.

However, the pathogens of periodontitis may aggravate gingival enlargement⁴, resulting in sore mucous lesions. Pa-

tients with sore stomatitis cannot tolerate oral cleaning even with a soft brush. As a result, they are apt to avoid oral care out of fear of the pain and hemorrhage associated with the myelopoietic disorder. Consequently, few authors have described the contribution of oral care in middle-aged or elder AML patients with preceding periodontitis, and the role of oral care among those patients still remains unclear. Here, we report a middle-aged AML patient with a prominent gingival hyperplasia whose quality of life (QOL) was gradually improved as a result of pain relief affected by oral care intervention using a moisturizing gel and sponge sweepers.

Case study

A 57-year-old male patient was referred to the oral maxillofacial surgery clinic complaining of malaise and eating problems due to pain from mucous lesions and gingival en-

Address correspondence: Harushi Yoshida, D.D.S., Ph. D., Department of Special Care Dentistry, Nagasaki University Hospital, 7-1 Sakamoto 1-chome, Nagasaki 852-8501, Japan

Tel: +81-95-819-7717, Fax: +81-95-819-7714, E-mail: harushi@nagasaki-u.ac.jp (H. Yoshida)

Received August 28, 2015; Accepted December 8, 2015

largement. Hepatitis B and liver cirrhosis were noted in the medical history. Since the antibiotics administered intravenously were ineffective and hematological data revealed leukocytosis, anemia and thrombocytopenia (Table 1), he was referred to the department of hematology where a diagnosis of acute myelomonocytic leukemia (AML-M4) was established. In the view of the deterioration in liver function due to cirrhosis, cytarabine (Ara-C) administration was reduced to 60 mg/body on the first to 12th days of chemotherapy (day 1-12) in combination with daunorubicin (DNR) 50 mg/body administered from day10 to day12. Totally, a regimen of Ara-C (60 mg/ body x 12 days) and DNR (50 mg/body x 3 days) was conducted, resulting in neutropenia and a reduction in blast cell rate from 89% to 0 % by day 12.

On day 4, bedside oral care was commenced under the condition of myelopoietic suppression. Regarding oral manifestations, the gingivae grew to the tops of the mandible teeth and oral hygiene was very poor. Around the mandibular right canine, white degenerated epithelium was observed on the gingiva (Fig.1). Although spontaneous pain was controlled by non-steroid anti-inflammatory drugs, the mechanical application of tooth brushes produced such severe discomfort that he refused tooth surface cleansing by the nursing staff. To assess humidity on the oral mucosal epithelium, we triply measured water content in the epithelium of the buccal

mucosa by translation from the capacitance using a moisture-checking device (Moisture Checker Mucus[®], Life Co. Ltd., Koshigaya Japan, Fig. 2)⁵⁾, which indicated an average value of 32.6 % on day 4 (reference value $\geq 30\%$).

To clean the oral mucosae and maintain moisture in the oral cavity, dentists swept the mouth using wet sponge sweepers topped with an oral moisturizing gel containing whey proteins (ConCool Mouth Gel[®], Weltec Co. Ltd., Osaka, Japan) (Fig.3) three times in the first week after gargling with sodium gualenate hydrate in combination with 4% lidocaine for prevention of discomfort during rinsing. On day 12, the white epithelium around the canine was carefully detached using the sweepers and removed with forceps. In order to prevent pain, the nursing staff commenced mucosal cleaning using sponge sweepers 4 days after completion of induction chemotherapy (day 16) and the patient was able to conduct tooth brushing by himself 4 days later (day 20). At the same time, lidocaine was excluded from the gargling agents.

The gingival enlargement was reduced, revealing the half tooth crown on day 19, and the gingivae regressed to the cement enamel junction of the tooth resulting in calculus exposure on day 33. The moisture checking device showed an average value of 33.7 % on the buccal mucosa at day 33, suggesting that the humidity of the oral mucosa was main-

Table 1. Hematological data (Day 2)

Peripheral blood		Reference values
Red blood cell count ($10^6 / \mu l$)	2.4	4.27-5.70
Hemoglobin (g/dl)	7.6	13.5-17.6
Hematocrit (%)	22.4	39.8-51.8
White blood cell count ($10^3 / \mu l$)	78.3	3.9-9.8
Blast cell (%)	89	0
Neutrophil (%)	3	40-60
Stab cell (%)	0	1-10
Lymphocyte (%)	3	25-50
Monocyte (%)	2	1-14
Eosinophil (%)	1	0-5
Basophil (%)	1	0-2
Platelets count ($10^4 / \mu l$)	2.4	13.1-36.2
Blood chemistry		Reference values
CRP (mg/dl)	4.01	<0.17
Albumin (g/dl)	1.7	4.0-5.0
AST (U/l)	61	13-33
ALT (U/l)	28	8-42
LDH (U/l)	751	119-229

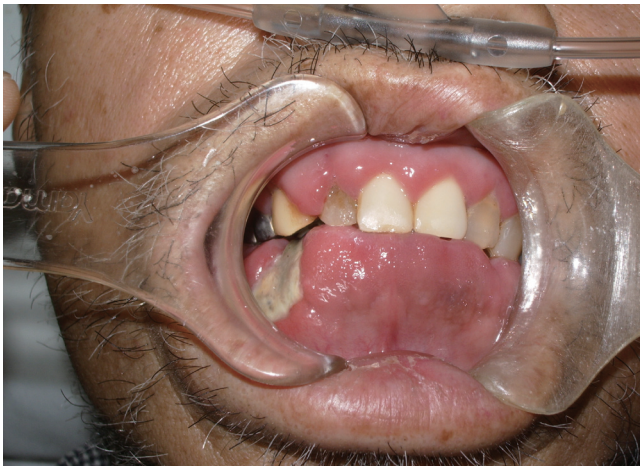

Figure 1 Gingival hyperplasia on day 4 of chemotherapy. The mandibular teeth were covered by the enlarged gingivae. White degenerated epithelium was located around the mandibular canine on the right side.

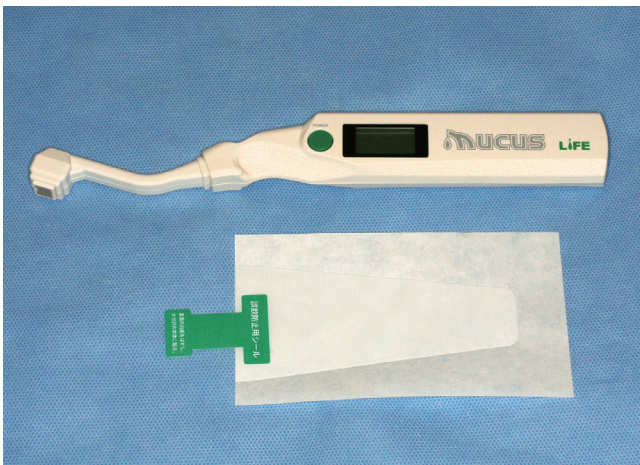


Figure 2 Moisture Checker of Mucus and sensor cover. The device is designed to measure weight present of water content in the oral mucosal epithelium by translation from the capacitance. Sensor cover is used in all cases.

tained within the normal range. Consolidation chemotherapy with Ara-C and mitoxantrone was commenced 24 days after completion of induction chemotherapy. After the second cycle of consolidation with Ara-C and aclarubicin, the patient underwent six courses of maintenance chemotherapy as described by Miyawaki et al⁶. On day 61, we performed a periodontal examination and found several periodontal pockets exceeding 4 mm in depth. Routine periodontal treatment has been conducted since then. The patient remains in remission and is free from sore mucous lesions and gingival enlargement to date (Fig 4).



Figure 3 A sponge sweeper (center) and moisturizing gel (right)

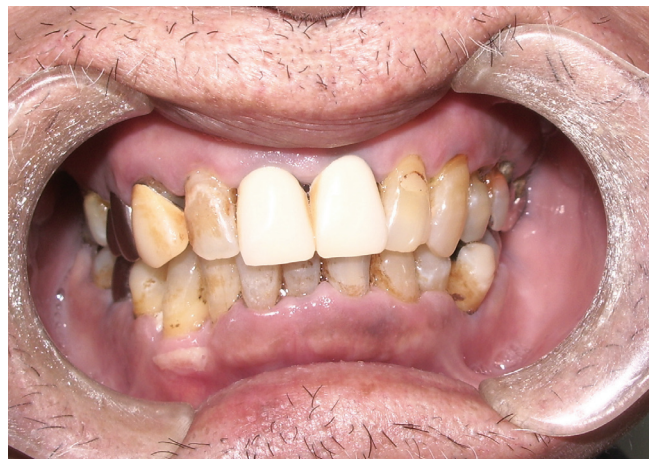

Figure 4 Regression of gingival enlargement on day 61. Note the gingival epithelium healing around the mandibular right canine.

Discussion

Gingival enlargement in AML patients was characterized as a symptom derived from underlying AML that improved without periodontal initial therapy after chemotherapy⁷. Histological findings disclosed blast cell infiltration in the overgrowing gingivae. Furthermore, blast cells were not detected after remission in a younger patient³. These findings suggest the implication of blast cells in the gingival overgrowth. Consequently, most reports place more emphasis on chemotherapy than on routine periodontal treatment in AML patients^{3,7}.

On the other hand, gingival hyperplasia might be stimulated by the bacterial pathogens of periodontitis in cases of poor oral hygiene⁴. After gingival regression, we detected calculus along the cement-enamel junction and pockets ex-

ceeding 4mm in depth, which suggested that periodontitis had preceded the onset of AML. The enlarged gingiva covering the mandibular tooth crowns was a more remarkable symptom than that reported in previous studies^{3,7)} and the mucosal pain was too severe to allow mechanical cleaning even after the disappearance of blast cells in the laboratory findings. Periodontal pathogens might be implicated in the aggravation of the gingival overgrowth.

Furthermore, sore stomatitis aggravation is a major concern for cancer patients subjected to chemotherapy due to hematopoietic suppression and disorders of the humoral and cell immune systems⁸⁾. In addition, dry mouth and saliva gland degeneration are provoked 2 weeks after commencement of chemotherapy⁹⁾. However, our case resulted in the maintenance of oral humidity. Besides overgrowth of the gingiva, tactile sensation around the stomatitis lesions also improved after day 16. These findings suggest that oral care using moisturizers contributes to the healing of mucous lesions by helping to prevent xerostomia.

With regard to the assessment of xerostomia, objective data in leukemia patients is lacking. The saxon test, or measurement of saliva discharge is conducted by chewing thick gauze for 2 minutes, is not a tolerable method for patients with sore mucositis¹⁰⁾. On the contrary, Moisture Checker Mucus[®], which measures the weight percentage of water content in the oral epithelium in a few seconds, is more tolerable for patients with painful stomatitis. In practice, we measured the water content of the mucous epithelium in triplicate within 30 seconds, which made it easy to assess the oral humidity in our patient.

Moisturizing agents are conducive to the reduction of oral micro-flora and the resolution of pain associated with oral mucositis. In clinical trials, the colony counts and genera of oral micro-flora decreased after the application of a moisturizing gel to the oral mucosa¹¹⁾. Moisturizing gels were also used to minimize pain provoked by cleansing in xerostomia patients under radiation therapy. A moisturizing gel containing whey proteins reviewed in animal experiments showed positive effects in the remission of ulcers induced by 5 FU in the oral mucosae¹²⁾. A growth factor in bovine whey protein extract was thought to protect cells against chemotherapy-induced death by apoptosis¹³⁾. We applied a whey protein moisturizing gel with a sponge sweeper to the sore gingivae covered with a degenerated white membrane around the mandible canine. The wet sponge sweeper helps to minimize pain provoked by cleansing the mucosae. As a result, the pain provoked by sweeping and brushing was gradually relieved, and the white degenerated membrane could be detached from the gingiva without severe bleeding and easily

removed with forceps after repeated moisturizing procedures on day 12 of induction. The moisturizer might contribute to a significant improvement in the patient's quality of life (QOL) as indicated by the pain relief that allowed the patient to exclude lidocaine from gargling agents by day 20.

In conclusion, moisturizing oral care from the early stage of chemotherapy may improve QOL in the patient with AML by promoting the relief of pain in the oral mucosae associated with deteriorated overgrown gingivae.

Conflict of Interest

The authors declare no conflict of interest.

Acknowledgment

We would like to express our gratitude to Prof. Brian Burke-Gaffney of the Nagasaki Institute of Applied Science for his considerable support in the preparation of the manuscript. We also thank Ms. Rio Takai, dental hygienist of the Medical Support Center at Weltec Co. for instruction regarding the use of the moisturizer.

References

- 1) Damon LE. Acute leukemia. In: *Current medical diagnosis and treatment* 2014 53th ed. (Papadakis MA, McPhee, SJ, eds. Lange, New York) pp. 501-504, 2013
- 2) Dreitzen S, McCrendie KB, Keating MJ, Luna MA. Malignant gingival and skin "infiltrates" in adult leukemia. *Oral Surg Oral Med Oral Pathol* 55: 572-579, 1983
- 3) Sonoi N, Soga Y, Maeda H et al. Histological and immunohistochemical features of gingival enlargement in a patient with AML. *Odontology* 100: 254-257, 2012
- 4) Shankarapillai R, Nair MA, George R, Walsh LJ. Periodontal and gingival parameters in young adults with acute myeloid leukaemia in Kerala, South India. *Oral Health Prev Dent* 8: 395-400, 2010
- 5) Sugiura Y, Soga Y, Nishide S et al. Evaluation of xerostomia in hematopoietic cell transplantation by a simple capacitance method device. *Support Care Cancer* 16: 1197-1200, 2008
- 6) Miyawaki S, Sakamaki H, Ohtake S et al. Japan Adult Leukemia Study Group of AML 97 Study. A randomized, postremission comparison of four courses of standard-dose consolidation therapy without maintenance therapy versus three courses of standard-dose consolidation with maintenance therapy in adults with acute myeloid leukemia: the Japan Adult Leukemia Study Group AML 97 Study. *Cancer* 104: 2726-2734, 2005
- 7) Wu J, Fantasia JE, Kaplan R. Oral manifestations of acute myelomonocytic leukemia: a case report and review of the classification of leukemia. *J Periodontol* 73: 664-668, 2002
- 8) Hayashi H, Kobayashi R, Suzuki A et al. Polaprezinc prevent oral mucositis in patients treated with high-dose chemotherapy followed by hematopoietic stem cell transplantation. *Anticancer Res* 34: 7271-7278, 2014

- 9) Jensen SB, Pederson AM, Reibel J, Nauntofte B. Xerostomia and hypofunction of the salivary glands in cancer therapy. *Support Care Cancer* 11: 207-225, 2003
- 10) Murakami M, Nishi Y, Kamashita Y, Nagaoka E. Relationship between medical and oral dryness diagnosed by oral moisture-checking device in patients with maxillofacial prostheses. *J Prosthodont Res* 53: 67-71, 2009
- 11) Rhodus NL, Bereuter J. Clinical evaluation of a commercially available oral moisturizer in relieving signs and symptoms of xerostomia in postirradiation head and neck cancer patients and patients with Sjogren's syndrome. *J. Otolaryngol* 29: 28-34, 2000
- 12) Clarke J, Butler R, Howarth G, Read L, Regester G. Exposure of oral mucosa to bioactive milk factors reduces severity of chemotherapy-induced mucositis in the hamster. *Oral Oncology* 38:478-485, 2002
- 13) Parrizas M, Saltiel AR, LeRoith D. Insulin-like growth factor 1 inhibits apoptosis using the phosphatidylinositol 3'-kinase and mitogen-activated protein kinase pathways. *J Biol Chem* 272: 154-161, 1997

