Short lingual osteotomy without fixation: A new strategy for mandibular osteotomy called the “Physiological Positioning Strategy”

Seigo Ohba[1, 2], Masashi Yoshida[3], Haruka Kohara[4], Takako Kawasaki[1], Tokutarou Minamizato[1], Takamitsu Koga[1], Yuya Nakatani[1], Estuko Watanabe[1, 5], Noriko Nakao[4], Noriaki Yoshida[4], Izumi Asahina[1]

1. Department of Regenerative Oral Surgery, Nagasaki University Graduate School of Biomedical Sciences
2. Division of Dentistry and Oral Surgery, Department of Sensory and Locomotor Medicine, Faculty of Medical Sciences, University of Fukui (present affiliation)
3. Department of Oral and Maxillofacial Surgery, Imakiire General Hospital
4. Department of Dental and Biomedical Materials Science, Nagasaki University Graduate School of Biomedical Sciences (current affiliation)
5. Department of Orthodontics and Dentofacial Orthopedics, Nagasaki University Graduate School of Biomedical Sciences

Corresponding author:
Seigo Ohba, DDS, PhD
23-3 Shimoaizuki, Matsuoka, Eiheiji-cho, Yoshida-gun Fukui 910-1193 Japan
Division of Dentistry and Oral Surgery,
Department of Sensory and Locomotor Medicine,
Faculty of Medical Sciences, University of Fukui
Tel: 81 776 61 8410
Fax: 81 776 61 8128
E-mail: sohba@u-fukui.ac.jp / seigoohba@gmail.com

Abstract

This article advocates the physiological positioning strategy (PPS) as a novel alternative treatment strategy to conventional orthognathic surgeries. Eighteen patients with skeletal mandibular prognathism were treated with surgery using the PPS. SNB and FMA as well as the Me position were measured after surgery to determine the skeletal stability, and the changes in the angle and perpendicular length of the upper and lower central incisors were also calculated after surgery to determine the dental stability. Excellent skeletal and dental stabilities were confirmed. The width of the jaw opening recovered early, and one temporomandibular joint disorder case was observed. Short lingual osteotomy with the PPS represents an effective new treatment approach for mandibular jaw deformities.

Key words: physiological positioning strategy; short lingual osteotomy; mandible; jaw exercise; maxilla-mandibular fixation

Introduction

Sagittal split ramus osteotomy (SSRO) and intraoral vertical ramus osteotomy (IVRO) are common orthognathic surgeries for jaw deformities.[1-3] SSRO has an advantage due to its shorter maxilla-mandibular fixation (MMF) period compared to IVRO because of the large bony contact and the rigid fixation.[4,5] However, movement of the mandibular bone segments is occasionally difficult because the distal segment becomes more prominent posteriorly as a larger amount of mandibular setback is needed. Moreover, the amount of bony interference in SSRO is greater than that in IVRO.[6] On the other hand, short lingual osteotomy (SLO) is a modified SSRO technique in which the mandibular osteotomy is extended anteriorly to overcome these SSRO shortcomings.[6,7]

In IVRO, the bone fixations are not necessary because the unrestricted proximal segment can be repositioned physiologically via jaw exercises.[8] Thus, IVRO can also be used for the treatment of temporomandibular disorder (TMD). However, IVRO usually requires a longer period of time for MMF than does SSRO.[4,5] To avoid this MMF with IVRO issue, we have proposed a technique consisting of IVRO with one-day MMF in which jaw exercises are started on the second day post-surgery. We have already reported on the postoperative stability with this approach.[9] However, there are some reports of maxillary artery injury during the IVRO operation because it is basically

blind surgery, which may cause life-threatening complications.[10,11] Almost 90% of the artery runs just inside the mandible ramus outside the lateral pterygoid muscle in Japanese people, whereas more than 45% of the artery runs inside the pterygoid muscle in Westerners.[12] Hence, we adopted the SLO technique, in which osteotomy sites are directly visible, unlike IVRO.

We believe that SLO can also be adapted without rigid fixation and can be followed with our unique regimen involving one-day MMF. We call this treatment strategy combining SLO and the previously reported postoperative management the "Physiological Positioning Strategy (PPS)". The purpose of this study was to confirm the efficacy of the PPS by demonstrating that it can provide good postoperative dental and skeletal stabilities without causing any TMD symptoms or progressive condylar resorption (PCR).

Patients and Methods

Eighteen patients (four males and 14 females) were diagnosed with skeletal mandibular prognathism and agreed to undergo orthognathic surgery followed by this regimen. The average age of the patients was 22.6 years (range: 18-34 years). The average amount of a mandibular setback was 6.14 mm (range: 1-15 mm), which was

less than 5 mm of difference in the setback amounts of both sides. SLO was performed according to a previous report.[6] Briefly, the lingual osteotomy is extended anteriorly from the posterior border of the ramus. However, no stripping of either the pterygomasseteric sling or the posterior border of the mandibular ramus was performed in our operation. All masseter muscles, medial pterygoid muscles, and stylomandibular ligaments were intact. After separation of the mandible, the maxilla and mandible were fixed with ligature wires with a splint placed on the maxillary arch.

We previously reported that PPS allows for a decrease in the stress due to MMF and an enhanced recovery of jaw function with long-term skeletal stability after IVRO.[9] We believed that this strategy could be adapted not only for IVRO but also for SSRO. The postoperative management was performed as shown in Figure 1. Briefly, on the second day post-surgery, the wires were replaced with elastic bands, and then jaw exercise was started with a splint in place. In jaw exercise, the patients opened their mouth by vocalising “a” and closed their mouth by vocalising “i”. Each episode of opening and closing was performed with one breath. After the fourth week post-surgery, the time spent wearing the splint was reduced by two hours every day. After the fifth week, the splint was worn for 12 hours a day for a week. After the sixth week, jaw exercise was continued with no splint. If the occlusal stability was confirmed during the seventh

week, orthodontic treatment was resumed. Otherwise, the patients continued to perform the jaw exercises with a splint for another week. All patients began the postoperative orthodontic treatment by the ninth week at the latest.

To assess the recovery of jaw opening after surgery, the jaw opening amount was reviewed pre-surgery and 3 days, 5 days, 1 week, 2 weeks, and 1, 3 and 6 months post-surgery. The amount of jaw opening was measured between the maxilla and mandibular central incisor edges. To assess the symptoms of TMD, pain, sounds and tenderness in the TMJ region were examined before and after surgery.

Cephalometric radiographs were taken pre-operatively (T1), immediately after (T2), and then 1 month (T3), 3 months (T4), and more than 6 months (T5) post-operatively examinations and used for the analyses in this study (Fig. 2). Skeletal changes were evaluated by the SNB, FMA and the antero-posterior or supero-inferior position of the Me. The Me was measured on the x-y coordinate with the SN plane for the x-axis and a perpendicular line to the SN plane through point Sella for the y-axis. The antero-posterior movement of the proximal segment was evaluated by measuring the angle (Ramus) between the posterior border of the mandible and the FH plane. Dental changes were evaluated at the angles between the FH and upper central incisor (U1-FH), the mandibular plane (MP) and the lower central incisor (L1-MP), the perpendicular

distance of the upper incisor edge from the palatal plane (PP) (U1⊥PP) and the perpendicular distance of the lower incisor edge from the MP (L1⊥MP).

Statistical analysis: Student's *t*-test was used to compare the average cephalometric measurements to evaluate the treatment changes at the different time points. A p-value ≤ 0.05 was considered to be significant.

Results

Skeletal changes (Table 1)

The SNB increased significantly by 0.81° and 1.06° for T4-T2 and T5-T2. It also increased significantly by 0.67° for T4-T3, and by 0.92° for T5-T3. Between T5 and T4, the change in the SNB was 0.25° without significance. All postoperative SNB measurements at all time points were significantly smaller than those taken at T1.

The FMA showed a tendency to increase after surgery; this difference was significant. It was completely stable after one month post-surgery.

The antero-posterior changes (*x*-axis) of the Me for T4-T2 and T5-T2 were significantly increased by 1.51 and 1.9 mm, respectively. There was a 23.09% horizontal relapse, showing that the Me moved posteriorly by 8.23 mm after surgery and then moved forward by 6.33 mm by six months post-surgery. There was a small

change between T5 and T4, which measured 0.39 mm. The vertical change (y-axis) of the Me post-surgery was 0.19 mm. The Me moved significantly upward by 1.22 mm between T4 and T2, while it moved upward by less than 1 mm between T5 and T2, although this small movement was statistically significant.

Ramus increased significantly by 2.92° for T2-T1. The ramus angle decreased significantly during the periods of T3-T2 (2.14°), T4-T2 (3.60°) and T5-T2 (4.20°). The angle at T5 was 1.28° lower than that at T1.

Dental Changes (Table 1)

The inclination of the maxillary incisor changed significantly after surgery due to decompensation of the tooth movement by orthodontic treatment. Therefore, the measurements of incisor inclination at T3, T4 and T5 were compared with T2 and then evaluated to determine the dental stability. The U1-FH was increased after surgery and was significantly different at T4 and T5 compared to T2, and at T5 compared to T3. The L1-MP was significantly decreased after surgery even if the values were negligibly small. In addition, the L1-FH changed, but with no significant differences observed in the measurements taken immediately after surgery.

The U1⊥PP was significantly decreased by 0.38 mm for T4-T3. The changes in the L1⊥MP were 0.37 and 0.33 mm for T3-T2 and T5-T3, respectively, which were also

significant. These changes were considered to be negligible.

Jaw opening (Table 2): Jaw opening was 47.6 mm pre-surgery and increased gradually but was 43.1 mm at three months post-surgery, showing recovery almost to the pre-surgery level. There were some TMD symptoms at five TMJs (13.9%) before surgery; pain at one and clicking at four were observed in 36 TMJs. No patients complained of pain and tenderness at their TMJ regions. A click was maintained in one of 36 TMJs, even though that patient did not report trismus or pain.

Discussion

Skeletal stability after three months post-surgery was confirmed in this study. The final amount of Me relapse was 1.90 mm horizontally and 0.75 mm vertically and was comparable to that of previous studies of postoperative skeletal stability after SSRO[1,13] or IVRO.[4,14] Some reports calculated a 2.5 mm anterior relapse after SSRO,[15,16] and Proffit et al.[17] advocated that skeletal stability could be concluded if the skeletal relapse was less than 2.0 mm. Therefore, our strategy is considered reliable for orthognathic surgical treatment.

The maxillary central incisor showed a tendency to undergo significant proclination after surgery. The mandibular incisor showed a tendency to undergo retroclination

without significance. These tendencies had largely disappeared by three months after surgery. We believe that these tooth movements should have compensated for the skeletal relapse that occurred by three months after surgery. Because tooth eruption is thought to occasionally result from the orthodontic force of elastic bands, titanium mini-screws were placed in the jaws for MMF and used for placement of the elastic bands rather than the teeth, resulting in the acquisition of excellent dental stability. The skeletal and dental stabilities after SLO in this study were equal to those after IVRO in our previous report.[9]

The proximal segment temporarily swung posteriorly after surgery. This phenomenon was believed to be due to the anterior movement of the condylar process by the traction force of the mandibular ligaments and the external pterygoid muscles. In addition, the inferior part of the mandibular ramus was retracted by soft tissues, including the stylomandibular ligament, because there was no stripping around the posterior border of the mandibular ramus. Jaw exercises after surgery using our method might help the proximal segment move anteriorly because the pterygomasseteric sling is attached to the proximal segment. The distal segment was not affected by the traction force because the pterygomasseteric sling was attached to the proximal segment in SLO. In addition, because there was no stripping of the posterior border of the mandibular ramus, we

considered that the superior-anterior traction force applied to the proximal segment created by the pterygomasseteric sling was alleviated by jaw exercise. These factors are thought to be important for explaining why the postoperative stability was achieved using this treatment strategy.

Ghali et al.[3] concluded that SSRO requires a longer operation because repositioning the condyle requires precise manipulations to rigidly fix the bone segments during the surgery. Malpositioning of the condyle occasionally causes TMD[18] and PCR.[19] We identified no cases of PCR in this study group, and this compares favourably with other osteotomy techniques. The use of a repositioning system reproduces the proper position of the proximal segment after SSRO,[20] but the technique is messy and time consuming. Moreover, even when the repositioning of the condyles is accurate, postoperative instability may still occur, and there is a risk of subsequent relapse. Therefore, in addition to the difficulty of positioning the proximal segment, we also wondered whether the pre-surgical position of the proximal segment is physiological for the newly reconstructed occlusion and jaw movement. No reports have definitively answered this question to date. For resolving the disadvantages of SSRO and IVRO, we developed the new treatment strategy, “Physiological Positioning Strategy”, for jaw deformities.

One of 36 TMJs exhibited clicking post-operatively, which had been observed before surgery, and 5 of these TMJs presented some symptoms before surgery. The newly established position of the condyle might be optimal for jaw movements. In contrast, repositioning of the proximal segment to the pre-surgical position in SSRO with rigid fixation might create non-physiological situations for the newly established occlusion and jaw movement. Consequently, the non-physiologically adapted condyle may induce remodelling changes and cause TMD or PCR.[18,19,21] Although there were no TMJ symptoms after IVRO in our previous report,[9] SLO is also adaptable for the PPS technique to induce the physiological position of the condyle. Furthermore, the extent of jaw opening was recovered almost to the pre-surgery level by three months after surgery (Table 2). Ueki et al.[22] previously reported that the amount of jaw opening was increased to the original level approximately 12-18 months after SSRO and IVRO. This suggests that the early jaw exercise in our strategy may result in the early adaptation of the TMJ and the masticatory muscle.

Our strategy was not associated with any problems in the process of bone healing and led to excellent postoperative skeletal and dental stability. Of course, a further follow-up study is needed because skeletal changes may occur more than one year after surgery. There are many other advantages, such as the lack of serious complications, a reduced

operation time, a reduced MMF duration, early recovery of jaw movement, and avoidance of TMD symptoms because the proximal segments may be induced to the physiological position by jaw exercise after osteotomy. Therefore, the presented method might be a reasonable treatment strategy for skeletal mandibular prognathism. Further studies are required to develop this new treatment approach for other conditions, such as mandibular retrusion, open bite and severe mandibular distortion.

References

1. Costa F, Robiony M, Politi M. Stability of sagittal split ramus osteotomy used to correct Class III malocclusion: review of the literature. Int J Adult Orthognath Surg 2001; 16: 121-126.
2. Paeng JY, Hong J, Kim CJ, Kim MJ. Comparative study of skeletal stability between bicortical resorbable and titanium screw fixation after sagittal split ramus osteotomy for mandibular prognathism. J Craniomaxillofac Surg 2012; 40: 660-664.
3. Ghali GE, Sikes JW. Intraoral vertical ramus osteotomy as the preferred treatment for mandibular prognathism. J Oral Maxillofac Surg 2000; 58: 313-315.
4. Chen CM, Lai SST, Wang CH, Wu JH, Lee KT, Lee HE. The stability of intraoral vertical ramus osteotomy and factors related to skeletal relapse. Aesth Plast Surg

2011; 25: 192-197.

5. Ueki K, Marukawa K, Shimada M, Nakagawa K, Yamamoto E. Change in condyler long axis and skeletal stability following sagittal split ramus osteotomy and intraoral vertical ramus osteotomy for mandibular prognathia. J Oral Maxillofac Surg 2005; 63: 1494-1499.

6. Yang HJ, Lee WJ, Yi WJ, Hwang SJ. Interferences between mandibular proximal and distal segments in orthognathic surgery for patients with asymmetric mandibular prognathism depending on different osteotomy techniques. Oral Surg Oral Med Oral Pathol Oral Radiol Endod 2010; 110: 18-24.

7. Simpson W. The short lingual cut in the sagittal osteotomy. J Oral Surg 1972; 30: 811-812.

8. Iannetti G, Fadda TM, Riccardi E, Mitro V, Filiaci F. Our experience in complications of orthognathic surgery: a retrospective study on 3236 patients. Eur Rec Med Phaemacol Sci 2013; 17: 379-384.

9. de Moraes PH, Rizzati-Barbosa CM, Olate S, Moreira RWF, de Moraes M. Condylar resorption after orthognathic surgery: a systematic review. Int J Morphol 2012; 30: 1023-1028.

10. Harada K, Okada Y, Nagura H, Enomoto S. A new repositioning system for the

proximal segment in sagittal split ramus osteotomy of the mandible. Int J Oral Maxillofac Surg 1994; 23: 71-73.

11. Hu J, Wang D, Zou S. Effects of mandibular setback on the temporomandibular joint: a comparison of oblique and sagittal split ramus osteotomy. J Oral Maxillofac Surg 2000; 58: 375-380.

12. Ohba S, Tasaki H, Tobita T, Minamizato T, Kawasaki T, Motooka N, Watanabe E, Yoshida N, Asahina I. Assessment of skeletal stability of intraoral vertical ramus osteotomy with one-day maxilla-mandibular fixation followed by early jaw exercise. J Craniomaxillofac Surg 2013; 41: 536-592.

13. Lanigan DT, Hey J, West RA. Hemorrhage following mandibular osteotomies: a report of 21 casses. J Oral Maxillofac Surg 1991; 49: 713-724.

14. Tuinzing DB, Greebe RB. Complications related to the intraoral vertical ramus osteotomy. Int J Oral Surg 1985; 14: 319-324.

15. Suwa F, Tekemura A, Ehara Y,Takeda N, Masu M. On the arteria maxillaris which passes medial to the pterygoideus lateralis muscle of the Japanese – patterns of origin of the inferior alveolar, the masseteric and the posterior temporal arteries -. Okajimas Folia Anat Jpn 1990; 67: 303-308.

16. Chou JIC, Fong HJ, Kuang SH, Gi LY, Hwang FY, Lai YC, Chang RC, Kao SY. A

retrospective analysis of the stability and relapse of soft and hard tissue change after bilateral sagittal split osteotomy for mandibular setback of 64 Taiwanese patients. J Oral Maxillofac Surg 2005; 63: 355-361.

17. Abeltins A, Jakobsone G, Urtane I, Bigestans A. The stability of bilateral sagittal ramus osteotomy and vertical ramus osteotomy after bimaxillary correction of class III malocclusion. J Craniomaxillofac Surg 1999; 15: 233-237.
18. Ayoub AF, Millett DT, Hasan S. Evaluation of skeletal stability following surgical correction of mandibular prognathism. Br J Oral Maxillofac Surg 2000; 38: 305-311.
19. Yoshioka I, Khanal A, Tominaga K, Horie A, Furuta N, Fukuda J. Vertical ramus versus sagittal split osteotomies: comparison of stability after mandibular setback. J Oral Maxillofac Sugr 2008; 66: 1138-1144.
20. Proffit WR, Philips C, Dann C, Turvey TA. Stability after surgical-orthognathic correction of skeletal class III malocclusion. I. Mandibular setback. Int J Adult Orthodon Orthognath Surg 1991; 6: 7-18.
21. Cutbirth M, Van Sickels JE, Thrash WJ. Condylar resorption after bicortical screw fixation of mandibular advancement. J Oral Maxillofac Surg 1998; 56: 178-182.
22. Ueki K, Marukawa K, Hoshiba Y, Nakagawa K, Degerliyurt K, Yamamoto E.

Assessment of the relationship between the recovery of maximum mandibular opening and the maxilla,amdibular fixation period after orthognathic surgery. J Oral Maxillofac Surg 2008; 66: 486-491.

23. Kim SG, Park SS. Incidence of complications and problems related to orthognathic surgery. J Oral maxillofac Surg 2007; 65: 2438-2444.

24. Epker BN. Modicications in the sagittal osteotomy of the mandible. J Oral Surg 35: 157-159, 1977.

25. Yoshioka I, Tanaka T, Habu M, Oda M, Kodama M, Kito S, Seta Y, Tominaga K, Sakoda S, Morimoto Y. Effect of bone quality and position of the inferior alveolar nerve canal in continuous, long-term, neurosensory disturbance after sagittal split ramus osteotomy. J Craniomaxillofac Surg 2012; 40: e178-e183.

Figures and figure legends

Figure 1. The treatment protocol is based on the floating bone concept.

Figure 2. The angles and points examined in this study:

① SNB: angle between the SN line and NB line.

② Mandibular plane angle (FMA): angle between the Frankfort horizontal (FH) plane

and mandibular plane (MP).

③ Me(x, y): perpendicular length from the menton to the x- or y-axis.

④ Ramus angle: angle between the FH plane and ramus plane.

⑤ U1-FH: angle between the axis of the upper central incision and FH plane.

⑥ L1-MP (IMPA): angle between the axis of the lower central incisor and the MP.

⑦ L1-FH (FMIA): angle between the axis of the lower central incision and the FH plane.

⑧ U1⊥PP: perpendicular length from the edge of the upper central incisor to the palatal plane.

⑨ L1⊥MP: perpendicular length from the edge of the lower central incisor to the mandibular plane.

Figure 1.

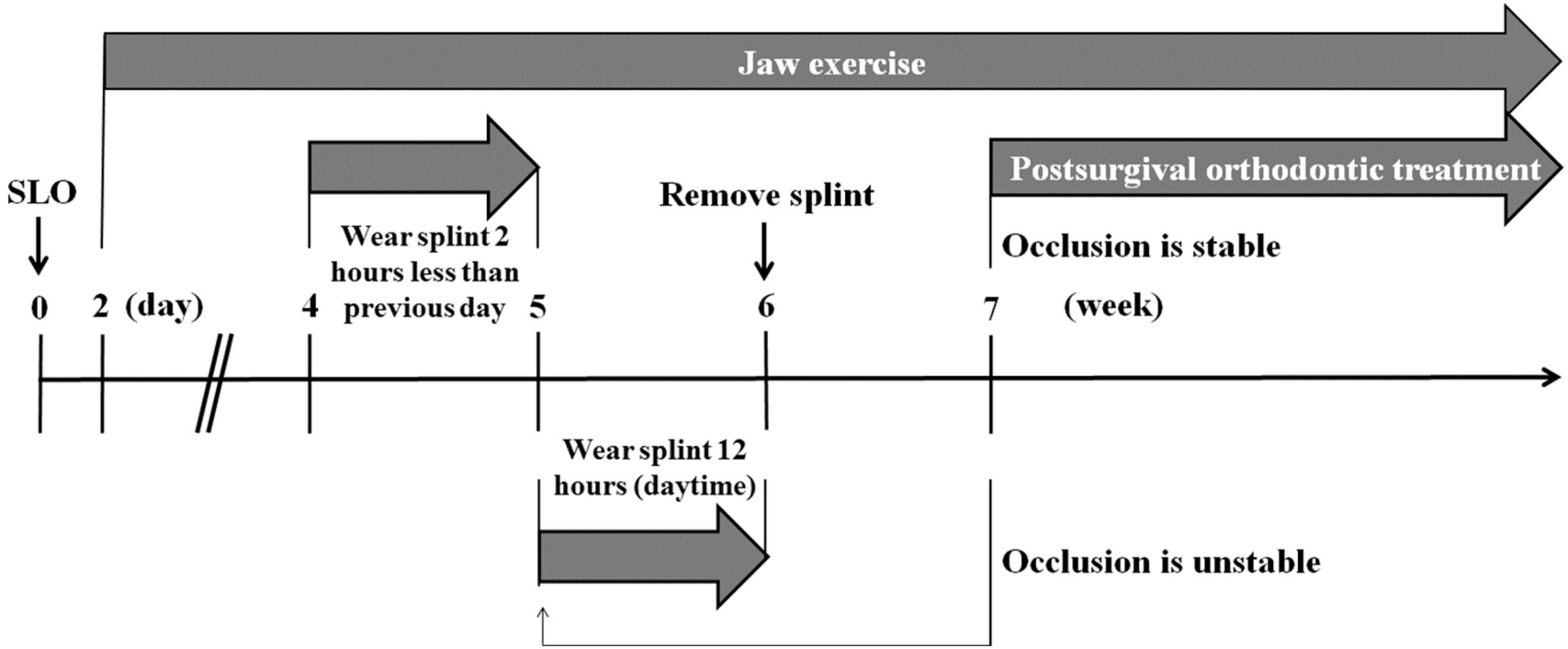
Jaw exercise
Postsurgival orthodontic treatment
SLO
Remove splint
Wear splint 2 hours less than previous day
Occlusion is stable
0
2 (day)
4
5
6
7
(week)
Wear splint 12 hours (daytime)
Occlusion is unstable

Figure 2.

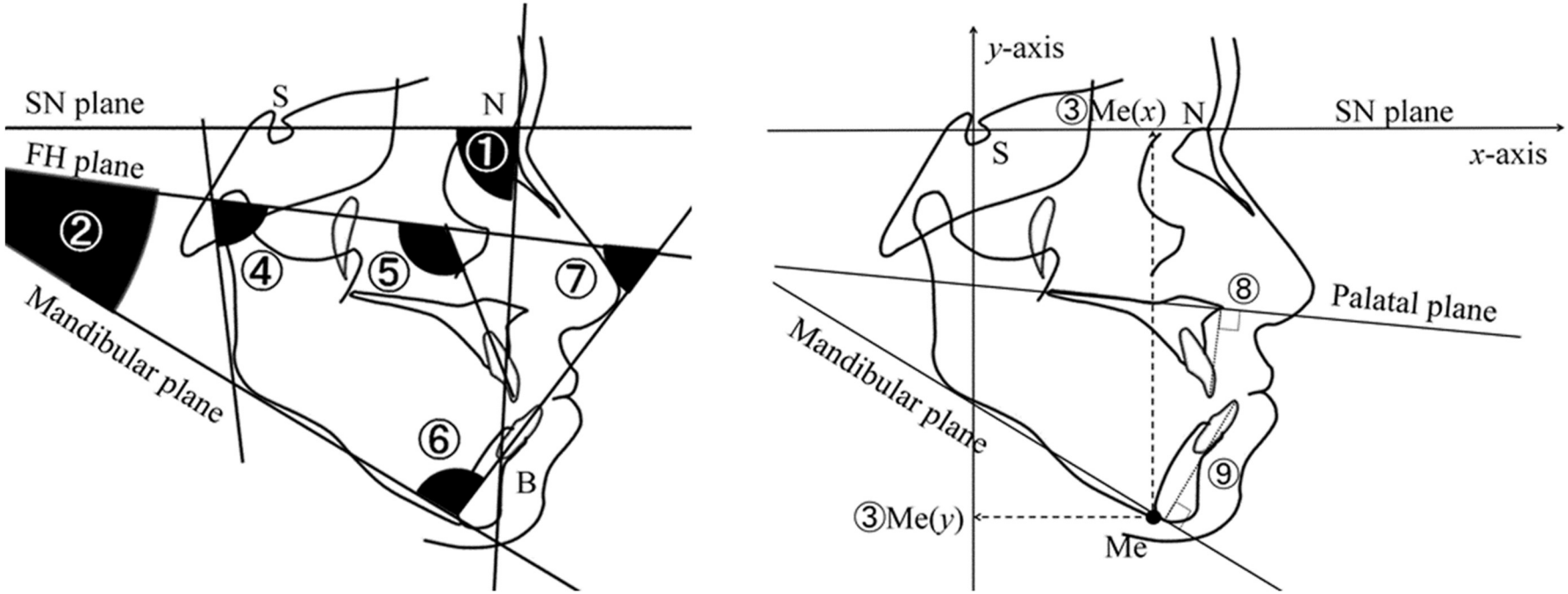
SN plane
S
N
FH plane
①
②
④
⑤
⑦
Mandibular plane
⑥
B
y-axis
③Me(x)
N
SN plane
S
x-axis
⑧
Palatal plane
Mandibular plane
⑨
③Me(y)
Me

Table 1. The skeletal and dental change after SLO without fixation.

	T1	T2	T3	T4	T5
SNA (º)	83.64	79.87 *[1]	80.01 *[1]	80.68 *[1, 2, 3]	80.93 *[1, 2, 3]
FMA (º)	26.77	28.12 *[1]	30.29 *[1, 2]	29.86 *[1, 2]	29.75 *[1, 2]
Ramus (º)	79.67	82.59 *[1]	80.45 *[2]	78.99 *[2, 3]	78.39 *[2, 3]
Me (*x*) (mm)	47.19	38.96 *[1]	30.09 *[1]	40.47 *[1, 2, 3]	40.86 *[1, 2, 3]
Me (*y*) (mm)	125.13	124.94	124.77	123.72 *[1, 2, 3]	124.09 *[2, 3]
U1-FH (º)	116.67	114.54	116.04	117.16 *[2]	118.33 *[2, 3]
L1-MP (º)	88.67	87.07 *[1]	85.21 *[1, 2]	84.93 *[1, 2]	85.20 *[1, 2]
L1-FH (º)	64.56	64.82	64.49	65.21	64.81
U1⊥PP (mm)	29.64	29.86 *[1]	30.00	29.62 *[3]	29.66
L1⊥MP (mm)	45.11	45.03	45.40 *[2]	45.19	45.07 *[3]

[1-3] represent significant difference compared with T1, T2 and T3, respectively. (: $p<0.005$)

Table 2. Jaw opening width.

	Pre	3D	5D	1W	2W	1M	3M	6M
Jaw opening amount (mm)	47.6	7.4 *	11.8 *	16.2 *	22.7 *	27.4 *	43.1	44.1

Pre; pre-surgery, D; day, W; week, M; month. *: $p<0.05$ (significant difference from the pre-operative value).