

Amelanotic melanoma of the mandible : A case report

Goro Kawasaki, DDS, PhD<sup>1</sup>, Souichi Yanamoto, DDS, PhD<sup>1</sup>,  
Izumi Yoshitomi, DDS, PhD<sup>1</sup> Akio Mizuno, DDS, PhD<sup>1</sup>,  
Shuichi Fujita, DDS, PhD<sup>2</sup>

<sup>1</sup>Department of Oral and Maxillofacial Surgery, Unit of Translational Medicine, Course of Medical and Dental Sciences, Nagasaki University Graduate School of Biomedical Sciences, Nagasaki, Japan (Chief: Prof. Akio Mizuno)

<sup>2</sup>Department of Oral Pathology and Bone Metabolism, Unit of Basic Medical Sciences, Course of Medical and Dental Sciences, Nagasaki University Graduate School of Biomedical Sciences, Nagasaki, Japan (Chief: Prof. Tohru Ikeda)

Key words: amelanotic melanoma, oral mucosa, immunohistochemistry

correspondence: Goro Kawasaki, DDS, PhD

Associate Professor, Department of Oral and Maxillofacial Surgery,  
Unit of Translational Medicine, Course of Medical and Dental Sciences,  
Nagasaki University Graduate School of Biomedical Sciences  
1-7-1, Sakamoto, Nagasaki, 852-8588, Japan  
TEL: +81-95-849-7696  
FAX: +81-95-849-7700  
E-Mail: [gkawa@net.nagasaki-u.ac.jp](mailto:gkawa@net.nagasaki-u.ac.jp)

## **Abstract**

Amelanotic melanoma of the oral mucosa is extremely rare. We describe herein our experience of amelanotic melanoma arising in the mandibular mucosa. An 85-year-old woman was referred to our clinic with swelling of the left lower gingival mucosa. The histopathological diagnosis was amelanotic melanoma of the mandible, as determined by immunohistochemical examination. The tumor cells were positive for S-100, Melan-A, HMB-45 and vimentin. The patient received irradiation therapy, but the response was poor.

## **Introduction**

Over 90% of all melanomas are malignant melanoma occurring on the skin surfaces, and slightly over 1% of melanomas arise from mucosal surfaces (1). The most common site for mucosal melanoma is the head and neck region (55%), followed by the anal/rectal region (24%), female genital tract (18%), and urinary tract (3%) (1). Oral melanomas comprise 50% of head and neck melanomas, and the most frequent site of oral melanoma is the palate, followed by maxillary gingiva. In a previous study, mandibular gingival melanomas comprised 7% of 703 cases of melanoma (1). Whereas pigmented melanoma is usually easy to diagnose clinically, amelanotic melanoma (AM), which lacks pigmentation, often requires biopsy for correct clinical diagnosis (2). Here, we report a case of AM arising in the mandibular mucosa.

## **Case report**

On September 27, 2001, an 85-year-old woman was referred to our clinic by her dentist because of swelling of the left lower gingival mucosa. The patient's medical history was not contributory. She had only one molar tooth in the mandible, and she had not used her full and partial dentures for about 2 years. About 2 weeks before visiting our clinic, she noticed swelling of the left lower alveolar ridge. Since the swelling increased gradually, she consulted her dentist, and was then referred to our clinic. Her general condition was good. Extraoral examination did not demonstrate any remarkable features. There were 3 palpable cervical and submandibular lymph nodes on the left side. Intraoral examination demonstrated elastic hard swelling that measured 48 × 27 × 18 mm, extending from the edentulous mucosa to the buccal mucosa in the left premolar and molar region (Fig.1). The surface of the lesion was rough, with ill-defined borders, and there was an induration around the tumor.

Panorama X-ray scan did not show any conspicuous masses. Computed tomographic (CT) scan of the head and neck demonstrated a mass invading the mylohyoid muscle in the left

mandibular and buccal region. Cortical bone resorption was observed in the left lower molar region and ramus of the mandible. The resorption of the mandibular body was not remarkable. Enhanced CT demonstrated uptake in the upper internal jugular nodes on the left side (Fig.2). Many lymph nodes exhibited rim enhancement. RI scintigraphy of Bone and Gallium demonstrated hot areas only in the left mandible and neck lymphadenopathy. There were no cutaneous lesions. After admission, an incisional biopsy was performed under local anesthesia. On clinical examination, there was no evidence of pigmentation in the specimen. There was no evidence of metastatic lesions on chest or abdomen CT. The patient declined surgical treatment, so we performed Linac X-ray radiotherapy (2 Gy per day) to treat the oral lesion and metastatic lymph nodes. At a total dose of 10 Gy, the patient exhibited lassitude, so we terminated radiotherapy. Bleeding from the tumor persisted, and the patient developed anemia and hypoparesis. She also contracted pneumonia. Although we attempted physical treatment, the patient's general condition worsened, and she died on October 17, 2001.

#### PATHOLOGICAL FINDINGS

Microscopically, the specimen exhibited diffuse proliferation of large round cells with bizarre nuclei and plump eosinophilic cytoplasm below the ulcerated surface (Fig.3). Nuclei were irregular-shaped and included small distinct nucleoli. Many mitotic figures were observed and multinucleate cells were scattered throughout the specimen. Melanin granules were not detected in the cytoplasm in H-E staining and Fontana-Masson staining. Immunohistochemically the tumor cells were positive for S-100 (Fig. 4), Melan-A (Fig. 5), HMB-45 and vimentin, but were negative for keratin, EMA, LCA, UCHL-1, CD20 and CD30. Ki-67 labeling index using MIB-1 antibody was 54.3%. On the basis of the histopathological findings, the lesion was diagnosed as amelanotic melanoma.

#### Discussion

Amelanotic melanoma (AM) is an extremely rare lesion, comprising 2% to 8% of all melanomas (2). Only 24 cases of oral AM have been reported in the English and Japanese literature (2-20), excluding the present case. The sites in those cases were palatal (n=9), maxillary gingiva (n=12), upper lip mucosa (n=1) and mandibular gingiva (n=2).

It is difficult to distinguish AM from other malignant lesions such as undifferentiated carcinoma, fibrosarcoma or malignant lymphoma. Immunohistochemistry is generally used for differential diagnosis of AM. The standard melanoma immunohistochemical antigens include

S-100 protein (a fairly sensitive but not overly specific antigen), HMB-45 (a marker of premelanosomes that stains melanoma cells and melanocytes in some nevi) (21) and Melan-A/MART-1 (an antigen on melanoma cells by cytotoxic T-lymphocytes) (22, 23). Gibson et al. (24) reported that 13 of 15 cases of AM were positive for S-100 protein. Adenocarcinomas such as breast or eccrine tumors and clear cell sarcoma can resemble AM morphologically, and also stain positively for S-100 protein. Wick et al. (25) performed S-100 immunohistochemical staining of various tumors, obtaining the following results: melanomas (n=67), 100% positive; eccrine carcinomas, 43%; metastatic visceral carcinomas, 25%; malignant schwannomas 100%; leiomyosarcomas, 80%. In contrast, although 62 (92%) of those 67 melanomas were positive for HMB-45, all other neoplasms they tested were negative for HMB-45. Melan-A is useful in the differential diagnosis of melanocytic tumors, since it is more sensitive than HMB-45. In the present case, because the specimen was positive for S-100 protein, HMB-45 and Melan-A, but negative for lymphoma-associated antigens, we diagnosed the tumor as AM. It is important to determine the existence of melanocytes in the specimen for differential diagnosis with melanoma. Detection of melanocytes is easy when they contain brown melanin granules. But AM cannot be diagnosed only by H-E stained specimen. The immunohistochemical examination using these antibodies is very helpful to identify the AM cells. Furthermore, the tumor in our case did not invade the bone remarkably, although the tumor was quite big and many metastatic lymph nodes were detected. General examination did not detect any extraoral lesions.

Mucosal AM is generally treated according to the guidelines for pigmented melanomas (21). Radical surgery is the most common treatment for oral melanoma (26). Furthermore, adjuvant postoperative radiotherapy is standard treatment for oral mucosal melanoma as it decreases the incidence of local recurrence after surgical resection, and some reports indicate that radiation therapy is effective for melanoma of the head and neck region (9, 27). We used radiation therapy in a palliative role, consulting with the patient and her family.

In general, the prognosis for patients with oral malignant melanoma is poorer than that of patients with cutaneous lesions. Two factors have been found to be associated with the prognosis of the disease: tumor size and evidence of metastatic disease. Graniel et al. (26) reported that, in their series of oral malignant melanomas, the only patients who survived free of disease for longer than 5 years were those with a small tumor (<4 cm), without evidence of lymph node metastasis, had complete tumor excision and were treated with radical surgical resection plus adjuvant radiotherapy. In the present case, many lymph node metastases were

observed, and tumor of the oral mucosa gradually increased in size. Radiation therapy was not effective in treating the present case, and the patient unfortunately died of cachexia.

#### Acknowledgements

We would like to thank the staff of the Department of Radiology and Cancer Biology, Unit of Translational Medicine, Course of Medical and Dental Sciences, for their help in preparing this manuscript.

#### References

1. M.J. Hicks, C.M. Flaitz. Oral mucosal melanoma: epidemiology and pathobiology. *Oral Oncol* 2000; 36: 152-69.
2. Kao SY, Yang JC, Li WY, Chang RC. Maxillary amelanotic melanoma: a case report. *J Oral Maxillofac Surg* 2001; 59: 700-3.
3. Furuhashi T, Kuno H, Teramoto M, Kurauchi J, Kurauchi T, Fukaya M. A case of amelanotic melanoma originating in the area of mandible. *Jpn J Oral Maxillofac Surg* 1979; 25: 1509-13.
4. Saku T, Takahashi H, Okabe H, Tsuda N, Okumura H, Sasaki M. Oral amelanotic melanoma--report of a case with desmoplastic changes at the site of lymph node metastasis. *Jpn J Cancer Clin* 1983; 29: 424-32.
5. Usui M, Shirasuna K, Morimoto T, Watatani K, Hayashido Y, Nishimura K, et al. Malignant melanoma in the upper alveolus: Report of a case. *Jpn J Oral Maxillofac Surg* 1985; 31: 1233-40.
6. Akizuki H, Ohno K, Yoshida H, Saito K, Michi K, Tachikawa T. A case of bilateral Warthin's tumors of parotid gland associated with amelanotic malignant melanoma of maxilla. *Jpn J Oral Maxillofac Surg* 1986; 32: 461-5.
7. Umeda M, Teranobu O, Nakanishi K, Shimada K. Treatment and prognosis of primary malignant melanoma of the oral cavity. *J Jpn Soc Cancer Ther.* 1990; 25: 2499-510.
8. Chu L, Abdul A, Takahashi T, Kojima A, Himiya T, Kusama K, et al. Amelanotic melanoma of the oral cavity. *J Nihon Univ Sch Dent.* 1993; 35: 124-9.
9. Van der Waal RI, Snow GB, Karim AB, van der Waal I. Primary malignant melanoma of the oral cavity: a review of eight cases. *Br Dent J* 1994; 176: 185-8.
10. Ohshima K, Ohtawa A, Yoshiga K, Takada K, Ogawa I, Takata T. A case of amelanotic malignant melanoma in the maxilla. *Jpn J Oral Maxillofac Surg* 1994; 40: 1006-8.

11. Tani R, Okamoto T, Sakamoto A, Yabumoto M, Toratani S, Takada K. A case of an amelanotic malignant melanoma successfully treated with LAK therapy. *Jpn J Oral Maxillofac Surg* 1994; 40: 825-7.
12. Barker BF, Carpenter WM, Daniels TE, Kahn MA, Leider AS, Lozada-Nur F, et al. Oral mucosal melanomas. *Oral Surg Oral Med Oral Pathol Oral Radiol Endod* 1997; 83: 672-9.
13. Shimazu K, Mohri M, Nishio M, Kamata M, Morimoto I. Amelanotic malignant melanoma in the palatal mucosa. *Pract Otol* 1997; 90: 331-8.
14. Shibuya Y, Yoshikawa T, Umeda M, Ri S, Teranobu O, Shimada K. A case of amelanotic malignant melanoma of the maxillary gingiva. *Jpn J Oral Maxillofac Surg* 1998; 44: 814-6.
15. Kimijima Y, Mimura M, Tanaka N, Kimijima S, Noguchi I, Amagasa T. A difficult-to-diagnose case of amelanotic malignant melanoma in the anterior alveolar of the maxilla. *Jpn J Oral Maxillofac Surg* 1999; 45: 703-5.
16. Ohno J, Fujita S, Tohjyo I, Yamaguchi A, Nishida M, Iizuka T. A case of amelanotic malignant melanoma of the oral mucosa that temporarily responded to a continuous intraarterial infusion of Interferon- $\beta$ . *J Jpn Soc Oral Tumor* 2000; 12: 327-31.
17. Ducic Y, Pulsipher DA. Amelanotic melanoma of the palate: report of a case. *J Oral Maxillofac Surg*. 2001; 59: 580-3.
18. Kuwazawa T, Okamoto T, Yamamura T, Ogiuchi Y, Uchiyama H, Ogiuchi H. A case of the multiple primary cancer involving maxillary amelanotic malignant melanoma and gastric cancer. *Jpn J Oral Maxillofac Surg* 2001; 47: 243-6.
19. Katsuno M, Kubota T, Matsui K, Takasaki S, Kobayashi S, Ota T. A case of amelanotic malignant melanoma in the hard palatal mucosa successfully treated with intra-tumoral injection of interferon. *Stomato-pharyngol* 2001; 13: 203-7.
20. Notani K, Shindoh M, Yamazaki Y, Nakamura H, Watanabe M, Kogoh T, et al. Amelanotic malignant melanomas of the oral mucosa. *Br J Oral Maxillofac Surg*. 2002; 40: 195-200.
21. Adler MJ, White CR. Amelanotic malignant melanoma. *Semin Cutan Med Surg* 1997; 16: 122-30.
22. Busam KJ, Chen YT, Old LJ, Stockert E, Iversen K, Coplan KA, et al. Expression of melan-A (MART1) in benign melanocytic nevi and primary cutaneous malignant melanoma. *Am J Surg Pathol* 1998; 22: 976-82.
23. Busam KJ, Jungbluth AA. Melan-A, a new melanocytic differentiation marker. *Adv Anat Pathol* 1999; 6: 12-8.

24. Gibson LE, Goellner JR. Amelanotic melanoma: cases studies by Fontana stain, S-100 immunostain, and ultrastructural examination. *Mayo Clin Proc* 1988; 63: 777-82.
25. Wick MR, Swanson PE, Racamora A. Recognition of malignant melanoma by monoclonal antibody HMB-45: An immunohistochemical study of 200 paraffin-embedded cutaneous tumors. *J Cutan Pathol* 1988; 15: 201-7.
26. Graniel CML, Carrillo FJO, Garcia AM. Malignant melanoma of the oral cavity: diagnosis and treatment experience in a Mexican population. *Oral Oncol* 1999; 35: 425-30.
27. Tanaka N, Amagasa T, Iwaki H, Shinoda S, Takeda M, Ohashi K, et al. Oral malignant melanoma in Japan. *Oral Surg Oral Med Oral Pathol Oral Radiol Endod* 1994; 78: 81-90.

### **Legend for figures**

Fig. 1 View of swelling mass of left mandibular molar region

Fig. 2 Enhanced CT shows that many lymph nodes reveal rim enhancement.

Fig 3 Photomicrograph of amelanotic melanoma shows diffuse proliferation of large round cells with atypical nuclei and eosinophilic cytoplasm. (H-E staining)

Fig 4 Immunohistochemistry for S-100. Cytoplasmic and nuclear expression is found in almost every tumor cells.

Fig 5 Immunohistochemistry for Melan-A. Granular localization is observed in the cytoplasm of the tumor cells.



Fig. 1

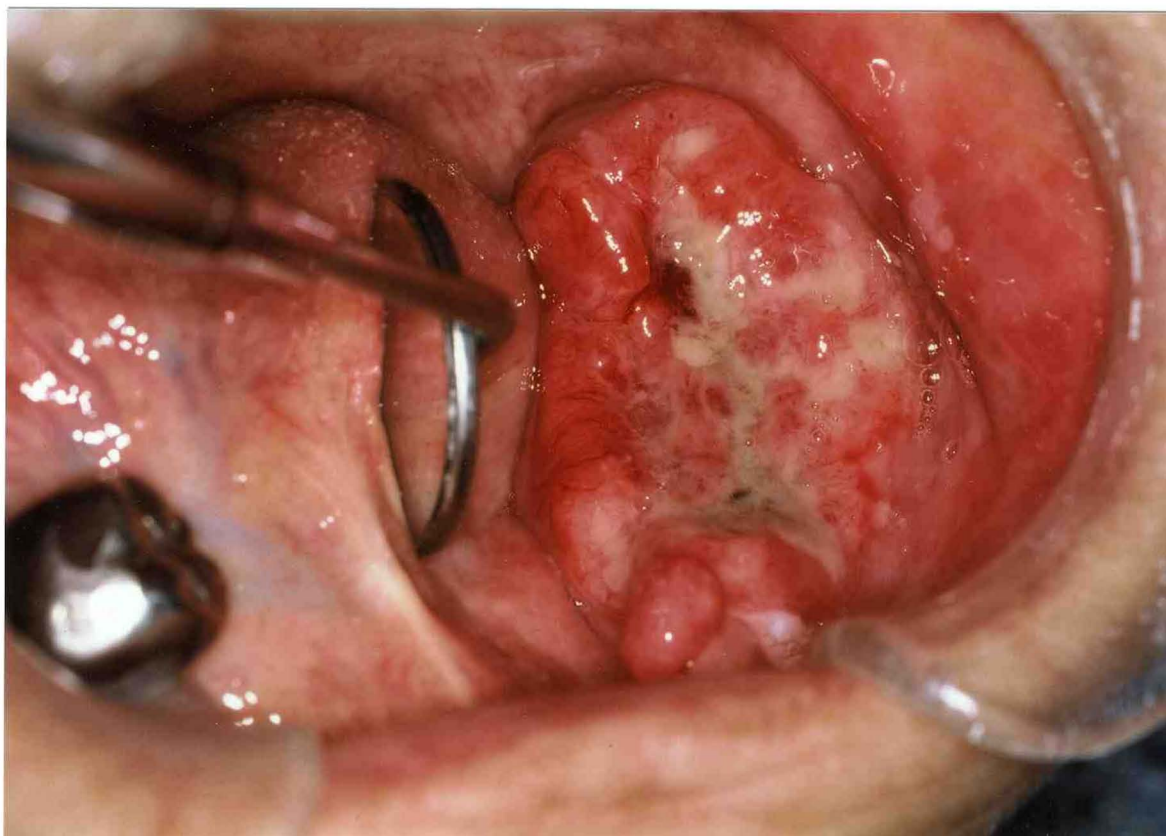


Fig. 2

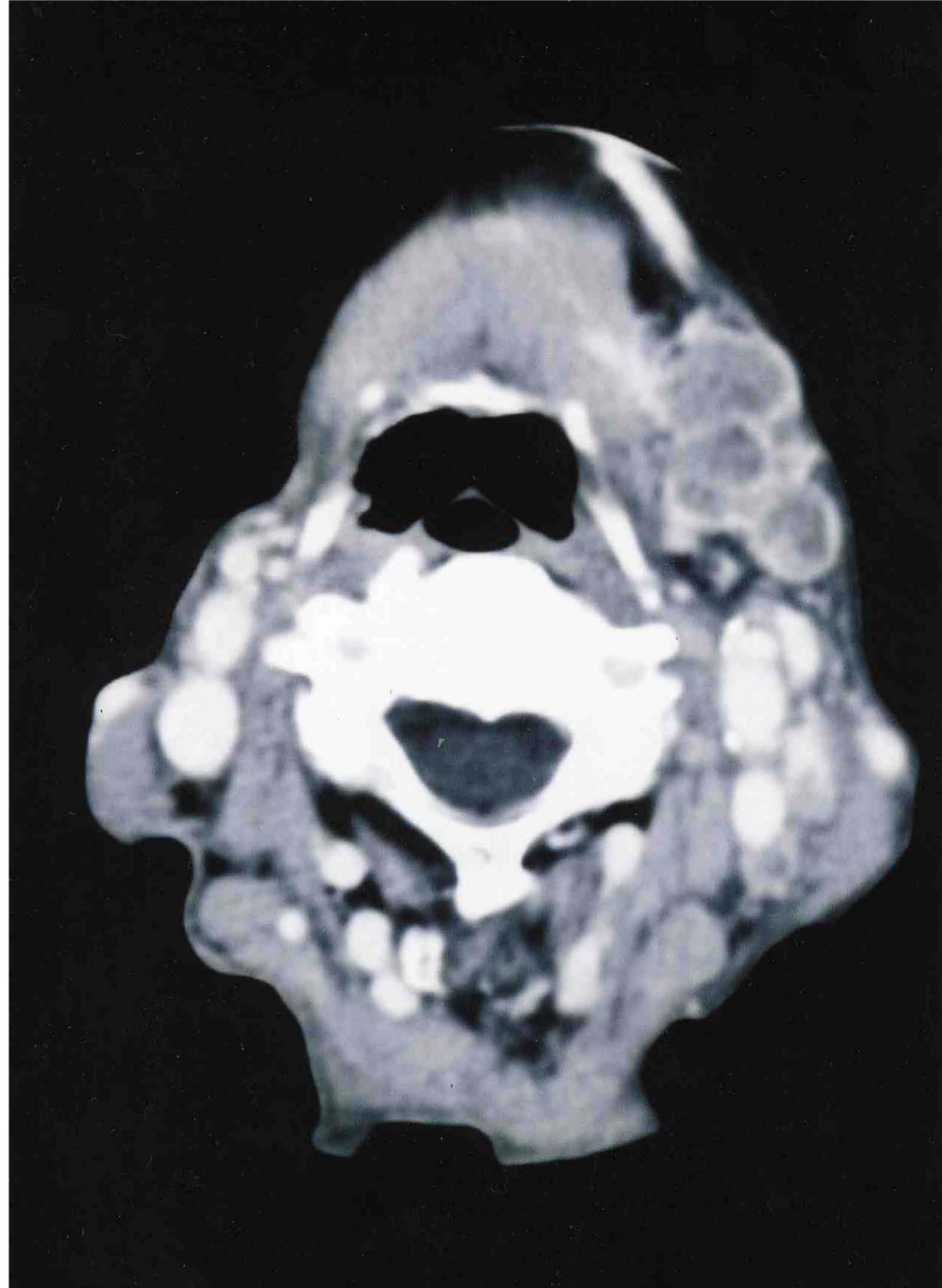

Fig. 3

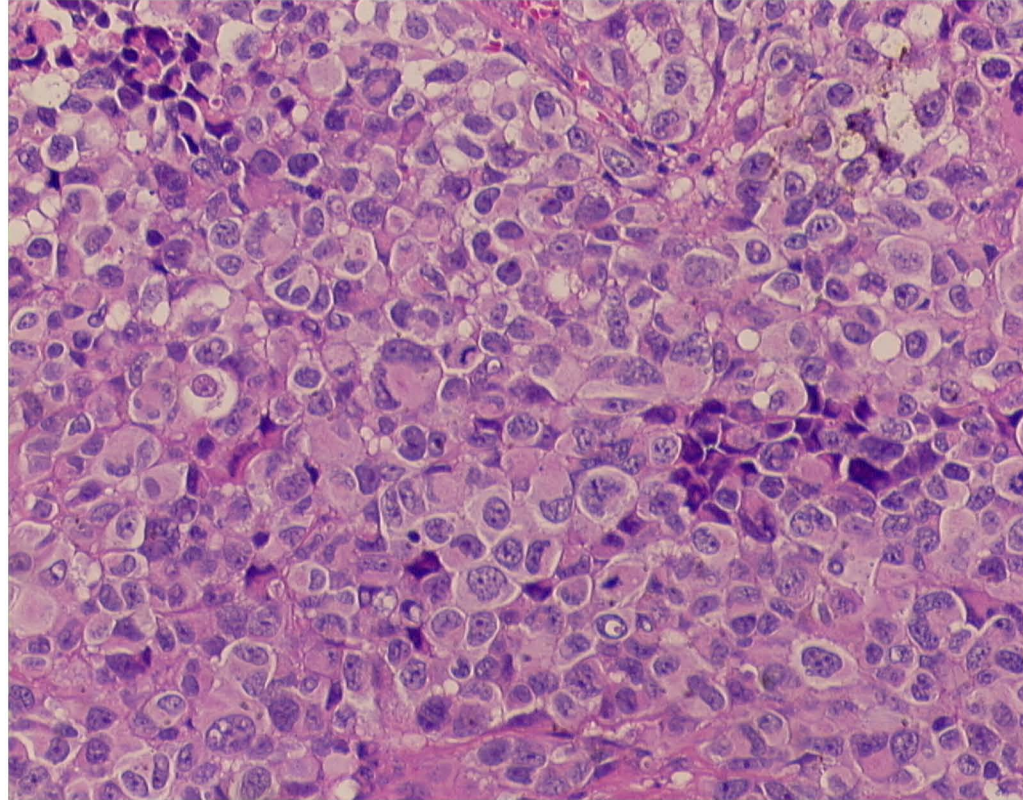


Fig. 4

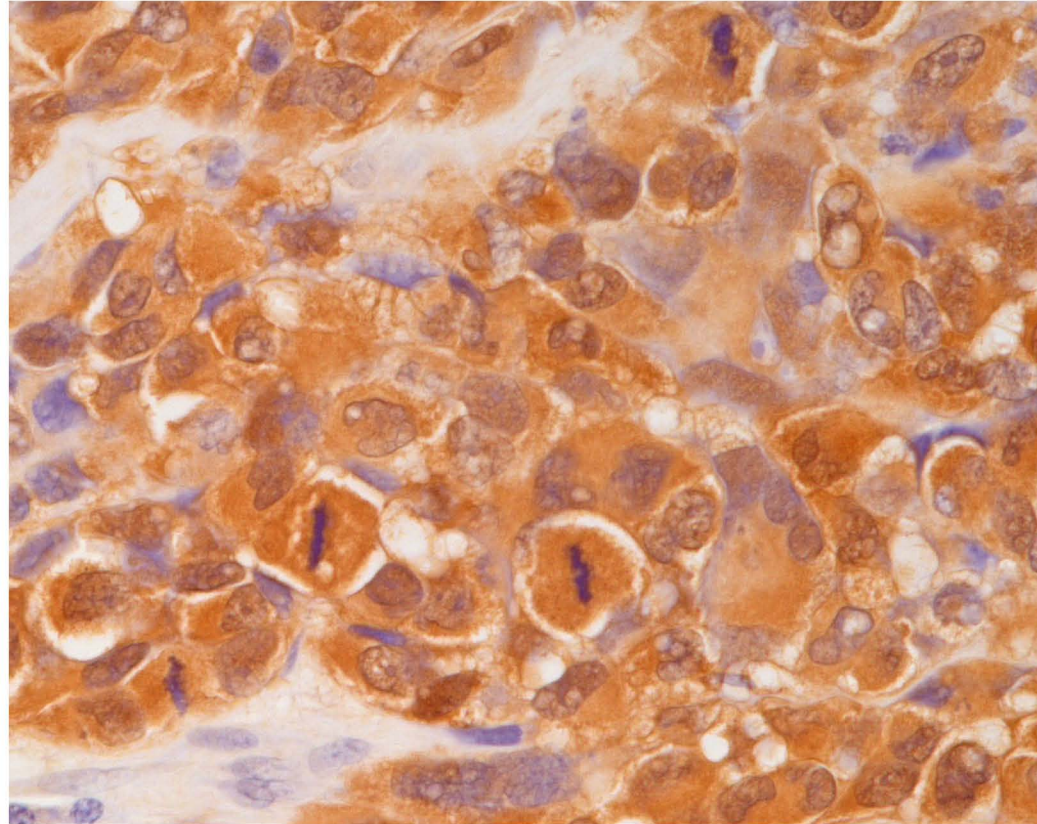


Fig. 5

